*Environmental Health Perspectives*
*Vol. 15, pp. 47-54, 1976*

# Assessment of Hepatotoxic Potential

by J. E. Gray*

**Philosophic concepts and pragmatic approaches toward improved understanding of the effects of drugs in the hepatocyte are reviewed. No set pattern of studies is advocated but rather observations are encouraged within the framework of studies that provide for varied exposure of the hepatocyte. Clinical usage should be imitated to provide earliest possible indications of toxicity in man. The need for definitive characterization through utilization of appropriate methodology derived from cross-fertilization of related disciplines is stressed. Both minimal and maximal dose effects should be established. Selected use of electron microscopy has become essential for characterizing responses of the liver to injury. The advantages of the toluidine blue-stained Epon "thick" sections are emphasized. Such observations are used to implement the utility of serial biopsies from the beagle dog prior to and during long-term study of potential hepatic injury. Examples of the critical effects of drug concentration within the hepatocyte are presented.**

Although we are conditioned to look to the liver, characterization of the hepatotoxic potential of a new chemical or drug can be a humbling experience. Safety studies in animals are more predictive of certain types of hepatic disease than of others. Sensitizing agents, for example, rarely produce alterations in the liver of experimental animals. Their effects are independent, it seems, of the dose and are therefore often unpredictable. Furthermore, it has been the experience of many that it is almost always impossible to evaluate exactly the factor that makes a substance toxic to the liver. Only in recent years with the concept of free-radical formation has some semblance of common understanding been approached of what is probably the most widely studied hepatotoxin, carbon tetrachloride.

It is by intention that I will restrict my discussion chiefly to the safety assessment of drugs; i.e., chemicals to which man is deliberately exposed for therapeutic purposes. The reason for this is that my presentation will be based chiefly on experiences with, perhaps, a helpful smattering of philosophy. At the onset we recognize that most classes of drugs have been associated with hepatic reactions. Clinical (*1*) and pathologic (*2*) effects of drugs in the liver of man have been compiled into long lists. Based on a similarity in chemical structure, the word to the wise would be to consider a new drug suspect and proceed accordingly.

We have passed from the time in which a diagnosis of the effects in the liver of a therapeutic agent was often sufficient to a new era in which definitive characterizations of injury produced by new drugs are being increasingly made. We can follow this progress in a tabulation of the papers that have been published in *Toxicology and Applied Pharmacology* (TAP) on liver injury with morphologic characterization during the past 16 years. As shown in Table 1, 40 such papers were published during the first 11 years and 55 during the past 5 years. While part of the increased rate of publication from 3.6 to 11/yr is due to increased number of TAP volumes issued annually, it is perhaps even more pertinent that 14 of the 55 papers in the past 5 years utilized electron microscopy to define the nature of the injury in the hepatocyte.

Many types of liver injury are represented in these 95 papers (Table 2). Fully one-third reported that the primary lesion was necrosis of the hepatocytes. The majority of these were cen-

*Pathology and Toxicology Research, The Upjohn Company, Kalamazoo, Michigan 49001.

Table 1. Papers on liver injury with morphologic characterization.[a]

| Years | Volumes | EM/LI[b] | Year | Volumes | EM/LI[b] |
|---|---|---|---|---|---|
| 1959 | 1 | 0/4 | 1970 | 16, 17 | 1/10 |
| 1960 | 2 | 0/4 | 1971 | 18, 19, 20 | 3/10 |
| 1961 | 3 | 0/6 | 1972 | 21, 22, 23 | 2/6 |
| 1962 | 4 | 0/3 | 1973 | 24, 25, 26 | 3/10 |
| 1963 | 5 | 0/4 | 1974 | 27, 28, 29, 30 | 5/19 |
| 1964 | 6 | 0/2 | | | |
| 1965 | 7 | 0/3 | | Last 5 years | 14/55 |
| 1966 | 8, 9 | 0/2 | | Total in 16 years | 14/95 |
| 1967 | 10, 11 | 0/5 | | | |
| 1968 | 12, 12 | 0/3 | | | |
| 1969 | 14, 15 | 0/4 | | | |
| First 11 years | | 0/40 | | | |

[a] In *Toxicology and Applied Pharmacology*, 1959-1974.
[b] Electron microscopy/liver injury characterized.

Table 2. Types of liver injury reported in the literature (1959-1974).[a]

| Type | No. of reports |
|---|---|
| Necrosis | |
| Focal | 9 |
| Centrilobular | 25 |
| Midzonal | 2 |
| Peripheral necrosis | 6 |
| Submassive | 3 |
| Massive | 1 |
| Fatty change | 7 |
| Cholestasis | 2 |
| Cholangiotoxic | 14 |
| Progressive | |
| Cirrhosis | 1 |
| Neoplasia | 12 |
| Hemosiderosis | 2 |
| Kupffer cell deposition | 2 |
| Porphyria | 3 |
| Enlarged common bile duct | 2 |
| Granuloma | 1 |
| Degenerative hepatocytes | 4 |
| Diffuse cloudy swelling | 1 |
| Perinuclear vacuolization | 1 |
| Total in 95 papers | 98 |

[a] In *Toxicology and Applied Pharmacology*, 1959-1974.

trilobular in distribution, the frequency being three times as great as midzonal and peripheral necrosis combined. Toxic effects in the bile ducts and neoplasia were also among the more commonly encountered categories of injury. Undoubtedly not all of these figures represent a true proportion of the incidence of chemically induced injury in the liver; rather, the relative incidence is probably skewed by the personal bias of the research interests of the authors.

## The Need for Definitive Characterization

The principal consideration of my discussion of the safety evaluation process is that it must accomplish a definitive characterization of the hepatotoxic potential of a new drug. One of the severest drawbacks of toxicologic evaluations in the past has been the stereotyping of studies so that the yield of information was often low. Definitive characterization implies that "no stones are left unturned" in the safety evaluation in animals. We have learned in the past that stones left unturned may turn up later, often under less favorable circumstances. Essentials for assessment of hepatotoxicity are: definitive characterization, appropriate methodology, and combined discipline approach. To this end, methodology which contributes understanding to the response of the liver cell to the drug exposure is appropriate. Experience has clearly shown that a cross-fertilization from the methods of related disciplines is necessary for definitive characterization. Critical and complementary studies might include, for example, drug effects on specific enzymes, cell respiration, and other biochemical measurements of organelles. Metabolites of the drug may be identified in tissue and bile. The liver concentrations of the drug may be assayed and compared with the sequential appearance of ultrastructural change. Obviously all drug candidates do not require the same battery of studies. Methods which have been used to estimate hepatotoxicity such as lethality, sleeping time potentiation and sulfobromophthalein (BSP) retention become less important as more is learned about the hepatic response.

In most studies of drug-induced injury in the liver, the preliminary observations are obtained with function data and light microscopy. A full spread of dose regimens and sequential observations are now utilized to study the pathogenesis and significance of the hepatic response. Much importance is attached to the manipulation of the dose regimen from that which produces a minimal or threshold effect in the hepatocyte to that which approaches maximal tolerance of the drug. The importance of understanding these differences is that it contributes greatly to the confidence with which human therapy can be initiated. It is necessary to learn, if possible, that a certain response will occur when certain conditions of exposure are met, and even more importantly from a safety standpoint, it is necessary to learn the conditions of exposure such that the particular response is very unlikely to

occur. Such observations also have prognostic value in terms of the onset, nature, and outcome of drug-related effects in the hepatocyte should such occur under extenuating circumstances during therapy in man. Frequently the conditions of clinical usage are imitated to provide the medical investigator with foreknowledge of the earliest possible indications of toxicity. The evaluation of parenterally administered drugs should follow closely the procedures by which the drug is given to man. Identical therapeutic formulations should be injected in animals prior to use in man.

## Effective Utilization of Electron Microscopy

Formerly, we were mostly concerned with labeling with a diagnosis, i.e. a descriptive term, a change we observed in the liver with a light microscope. This is still a beginning point, but diagnosis in drug safety evaluation is no longer an end in itself. The main problem with safety observations limited to diagnosis is that it does not tell us much about what is going on within the hepatocyte. With the application of electron microscopy to drug safety evaluations about 10 years ago, the insight into the dynamic state of the hepatocyte became much broader. Some ultrastructural changes were observed to occur very rapidly. Transient changes were found that ordinarily were missed previously when a single terminal observation was made of the liver by means of light microscopy. The conditions under which irreversible changes occurred in the hepatocytes could also be determined much more precisely. With certain drugs, such as phenobarbital (*3*), erythromycin, clindamycin (*4*), and others, the characteristic hepatocyte response was shown to be ultrastructural; prior interpretation by light microscopy of the changes produced by these drugs had been quite limited. The less specific effects of "wear and tear" on the hepatocyte, such as is embodied in the concept of focal cytoplasmic degeneration (*5*) were also recognized.

Electron microscopy has been utilized effectively as a lead observation to indicate biochemical and pharmacologic studies that may be appropriate to a particular safety evaluation. Without biochemical substantiation of altered protein synthesis, observations of changes in the endoplasmic reticulum may be of limited value. In long-term studies, low grade sequential effects of therapy can be monitored through the use of needle biopsy samples processed for electron microscopy. Electron microscopy is also useful in defining the limits of tolerance for a new drug. Minimal or threshold responses of hepatocytes produced by various routes of administration and dose regimens can be compared. The latter findings are quite helpful in developing an overall safety evaluation. Such changes would probably be inapparent with light microscopy.

In summary, the advantages of electron microscopy in study of hepatocyte response to drug injury are: refinement of the pathologic description; observation of changes that occur rapidly; detection of transient changes; determination of irreversible change; characterization of drug effects that are chiefly ultrastructural in nature; appraisal of general metabolic state; as a lead observation to indicate pertinent biochemical and pharmacologic studies; for monitoring of sequential effects in long-term studies; to define limits of tolerance.

Protocols for electron microscope studies require more forethought and restraint ordinarily than those for light microscopy. The return for effort has the promise of being greater with electron microscopy, but the sampling problem usually does not allow for a large number of observations at one time. Thorough observations sequentially made in the livers of a few animals should yield superior information to that obtained from a large number of animals at one interval during the course of a study of some duration. Therefore with electron microscopy the design must be selective. It is usually best conceived prior to implementation of the study. Electron microscopic observations "hooked on" to other studies often suffer from lack of sufficient control observations. Certain factors, such as exposure to other drugs and lack of environmental control, are very critical in the interpretation of ultrastructural change in the hepatocyte. Categorically, electron microscopy is no better than the design of the study for which it was done. Electron microscopy is no longer a prestige method, but rather it is an essential established method for observing responses of cells to injury or to lack of injury, as the case may be.

It might have been anticipated that the greater magnification obtained with electron microscopy (EM) would bring about a closer correlation of morphological change with serum enzyme activities associated with liver function. The results of some studies (*6,7*) have not shown, however, that slight elevations of serum transaminase activities specifically reflect ultrastructural changes. The

data do not suggest that one is necessarily predictive of the other during the early stage of altered function and morphology in the liver cell. It seems plausible, at present, that these changes may be, more or less, independent phenomena which may or may not occur simultaneously.

## EM Fallout: The Semithin Epon Section

A very valuable histologic procedure that came about following the introduction of electron microscopy has been the preparation of semithin or thick Epon sections. These sections, which are 0.5 to 2.0 μm thick, are cut preliminarily from the same blocks prepared for electron microscopy and are routinely stained with toluidine blue. They are indispensable for orientation of the section for electron microscopy and, moreover, frequently enable the investigator to decide whether or not to proceed with a particular block or embedment. Thus there is a critical time factor associated with their utility.

The preservation of detail in the semithin section is much better than in the paraffin section. This is often particularly true with liver sections. Semithin Epon sections are especially valuable for the study of the distribution of fatty droplets and myeloid bodies, as both stain intensely with toluidine blue. Alternatively, frozen sections stained with Oil Red O can be prepared but these are often unreliable and poor in quality. Myeloid bodies are not visualized satisfactorily in conventionally stained paraffin sections.

A further advantage of the semithin Epon sections is that often they are available more quickly than the paraffin sections. Some pathology laboratories are processing Epon blocks from fixation to staining the same working day. They can be routinely processed in 24 hr. The information they contain is very useful for the "feedback" that allows the pathologist to interpret paraffin sections more accurately as well as to make better utilization of electron microscopy at the same time. Their value lies then, in part, that they can be read "up" to electron microscopy or read "down" to conventional light microscopy. Such morphologic correlations are indispensable for adequate safety evaluations of the liver.

## Species Selection for Hepatotoxicity Studies

Much of what has been learned about the hepatotoxicity of drugs in animals has probably come from the albino rat. The rat is somewhat less susceptible to most drugs than the dog. This has been shown repeatedly by the higher dose regimens of most drugs tolerated by the rat for long periods of time. Because a single treatment group consists of 10 or more animals, studies in the rat are particularly useful for detection of weight increase or hypertrophy of the liver (*8, 9*). This measure of hepatic response is usually more sensitive than either increases in serum enzyme activities or light microscope change.

Conventionally, parallel safety studies are done in the rat and the dog. In studies of several months duration with a drug of some therapeutic promise, i.e., with no overt hepatotoxic property, the dog generally yields the most reliable information. Besides having a liver that is more susceptible to injury, the dog is probably also a better predictor to tolerance in man. In our experience, the dog is less likely to yield a false negative prediction than the rat. Such empiric understanding seemingly has limited value in this discussion but nonetheless plays heavily in the evaluation of hepatotoxicity of a new drug. In the light of this prejudice, it is interesting to reflect on similarities in the remarks expressed several years ago by Beyer (*10*) in favor of the use of the clean mongrel dog in safety evaluations because man and the dog had presumably made similar metabolic adaptations to their environment for a substantial period of time. My only reservation on Beyer's confidence in the dog is that ultrastructual variations in the hepatocyte of the mongrel dog would more than likely be a major shortcoming.

The beagle is used widely in drug safety evaluation. The ultrastructure of the hepatocyte in high quality beagles is quite uniform and free of many of the aberrations commonly found in street dogs and in beagles with compromised backgrounds (*4,11*). To achieve high standards of ultrastructural control, beagles should be raised in a rigidly controlled environment. Beagles are most suitable for long-term studies during which biopsies of the liver and serum enzyme activities are obtained periodically for sequential appraisal of the liver response (Table 3). Customarily, the livers are biopsied with Silverman needles at least once, usually twice, prior to treatment so that an adequate ultrastructural baseline is available in each dog. Posttreatment biopsies are usually included in the study protocol of some dogs to register the reversibility of any changes that may have appeared during the treatment period. Vacuolation artifacts in the hepatocyte such as have been associated with electrocution

Table 3. Suggested schedule for monitoring of ultrastructural injury in the liver by biopsy.

| Type of sampling | Schedule |
|---|---|
| Pretest sampling | Once or twice for individual baseline data |
| Short-term sampling | First day of treatment<br>30 min, 1, 2, 4, 8 hr<br>24, 48, 72 hr<br>1 week, 2 weeks |
| Long-term sampling | 1 month<br>Monthly, bimonthly, trimonthly, semiannually |
| Crisis sampling | At time of clinical or functional change |
| Posttreatment | 1 to 2 weeks after treatment discontinued |

(*12*) have been alleviated by the biopsy sampling procedure.

We have attempted to use the rhesus monkey in studies of ultrastructural monitoring by biopsy, similar to those in the dog. The effort has been much more limited in numbers of animals but thus far the results have been less satisfactory. The hepatic response of the monkey to drug was quite varied and therefore less predictable. The liver of the monkey by comparison to the dog, given the same dose regimen, appeared to be less susceptible to injury.

## Comparative Characteristics of the Hepatocyte Ultrastructure

Inclusion of some of the apparent ultrastructure characteristics and responses in the rat and dog seem appropriate to the discussion. Fat droplets, for example, are frequently present in small numbers in scattered hepatocytes in the rat. They are only occasionally encountered in the hepatocyte of the beagle. The formation of myeloid bodies (*13*) is the typical morphologic expression of phospholipidosis in both species. This is a common response in the liver to many chemicals collectively termed as amphiphilic (*14*). Myeloid bodies in rats treated with clindamycin were usually multicentric whereas those in the dog consisted of concentrically layered membranes about a single core of matrix (*4*). There was some indication of a broader response in the rat in that earlier stages in lysosome development (*15*) were subject to the formation of whorled membranes. The response in the dog was restricted largely to the secondary lysosome or residual body. In contrast, fewer myeloid bodies were found in the rat hepatocyte at comparable treatment levels with the dog. The lysosomes of the hepatocyte of the treated dog tend to become larger and more varied in shape and density than those in the rat hepatocyte.

In both species, piecemeal effects on various organelles can be visualized as the dose regimens are increased. Changes in the mitochondria are often indicative of irreversible injury. An increase in autophagic vacuoles is noted, and this suggests that the turnover time of organelles may be shortened during a treatment period when drugs are given at levels higher than the minimal or "threshold" effect dose. Focal cytoplasmic degradation may, therefore, be accelerated.

## Drug Concentrations and Metabolism

In the assessment of the hepatotoxic potential of a drug it is paramount to determine whether the drug is excreted principally through the liver or by the kidney or some other route. Each metabolite should be identified to learn whether it enhances or diminishes the toxic effect of the drug. A dose-related response in the liver is usually considered to reflect the concentration of the drug in the hepatocyte. Piecemeal injury of the ultrastructural organelles appears to be related to varied concentrations of the drug, in part, in the hepatocyte. An increased concentration of a drug may bring about degeneration of an organelle that had been able to accomodate to lower levels of the drug. Conversely, the hepatocyte may show improved tolerance, i.e., less evidence of response, after a few days of treatment and may continue to do so for a limited period of time or for the duration of long term study. The latter type of accomodation was recently reviewed (*16*). Transient ultrastructural changes lie within the scope of this type of adaptation.

There is increasing evidence that the hepatocyte can handle concentrations of certain drugs to a rather specific level without functional or morphological insult. Once the level of minimal or threshold effect is exceeded, a variety of hepatic responses may occur depending on nature of the specific insult. In ultrastructural studies (*4*) with clindamycin, for example, myeloid bodies were seldom observed in a group of dogs treated orally with 300 mg/kg for one year. In other dogs treated with a near maximal tolerated dose of 600 mg/kg they formed rapidly, in 30 min or less, and

became abundant in most hepatocytes. The critical effect of concentration on the hepatic response is also illustrated by a comparison of tetracycline levels in the blood serum and liver (Table 4). The disproportionately greater concentration in the liver of female rats treated with 300 mg/kg compared with that of rats treated with 100 mg/kg is indicated at 1 hr after injection (342:1), at 3 hr (833:167), and at 48 hr (163:1). These concentrations produced distinguishable accumulations of fat droplets in the hepatocyte (*17*). *In vitro* studies revealed that a precipitate formed rather abruptly with serum lipoproteins in the presence of $Ca^{2+}$ when the concentration of tetracycline exceeded 200 μg/ml (Fig. 1). This information, coupled with the bioassay results which indicated that the concentration of tetracycline in the liver of rats treated with 300 mg/kg considerably exceeded 200 μg/g of tissue, offered a credible basis for the formation of fat droplets in the space of Disse (Fig. 2).

**Table 5. Mean concentrations of tetracycline in blood serum and liver of groups of three Sprague-Dawley female rats after intraperitoneal treatment with 100 and 300 mg/kg.**

| Time after single IP injection, hr | Tetracycline concentration | | | |
|---|---|---|---|---|
| | IP dose=100 mg/kg | | IP dose=300 mg/kg | |
| | Blood serum, μg/ml | Liver, μg/g | Blood serum, μg/ml | Liver, μg/g |
| 1 | <0.7 | <1.1 | 38.0 | 342.1 |
| 3 | 36.2 | 166.7 | 68.9 | 832.5 |
| 6 | 25.7 | 124.8 | 72.9 | 804.4 |
| 24 | 1.3 | 4.6 | 27.3 | 183.8 |
| 48 | <0.7 | <1.1 | 23.3 | 163.2 |

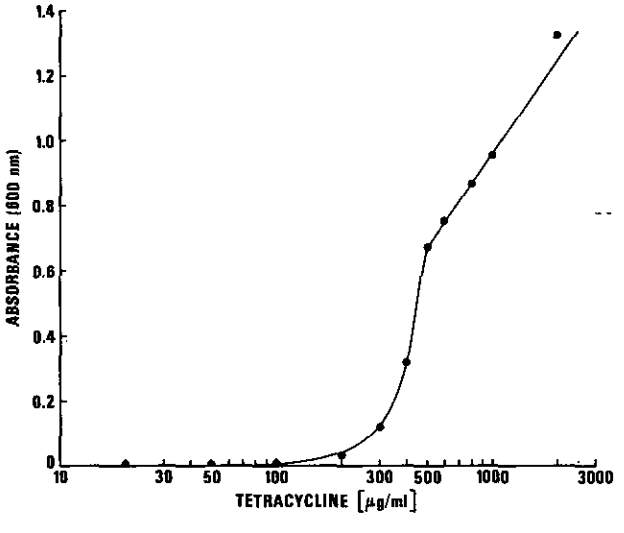


FIGURE 1. Influence of tetracycline concentration on the formation of a precipitate with lipoprotein in rat serum *in vitro*.

Another curious finding may follow the excretion of high levels of a drug by the liver (*7*). Under certain circumstances, especially during an anorexic state, the drug or its metabolites may accumulate in the bile in the gall bladder in higher concentration than it was excreted by the liver. The higher concentration may exceed the tolerance of the gall bladder and may bring about necrosis of the lining. This could occur without appreciable change in the hepatocyte observable by light microscopy.

## Implementation of Hepatotoxicity Studies

How, then, do we go about evaluating hepatotoxic potential of drugs in animals? Underlying this discussion has been the assumption that no set pattern of observations would be adequate. All observations are made in the framework of studies that allow for varied exposure of the hepatocyte to the drug. Allowance should be made for the accommodation of special observations as the characterization proceeds. Some chemicals will require long-term studies if proliferative responses of the hepatocytes of bile duct epithelium have occurred or are suspected. With others, the study time could plausibly be shortened to a few months in duration. These differences are dependent chiefly upon the type of hepatic response.

Perhaps fewer drug candidates will be studied in the foreseeable future, but these will be worked on in greater depth than ever before. More will be learned about each drug before human exposure. This has been made possible by technological improvements and opportunities for combined discipline approach. All observations must be integrated and interpreted in so far as possible. A continuing challenge exists in altering the dose regimens and conditions of exposure so as to minimize the possibility of hepatic injury. Hepatic injury may be studied during simultaneous administration of two or more drugs. No widespread use of this is foreseen, however, rather, such studies may be done in selected situations in which one drug has an effect on the metabolism of another. The forecast for assessment of hepatotoxic potential shows promise for continued optimism. It is sobered by

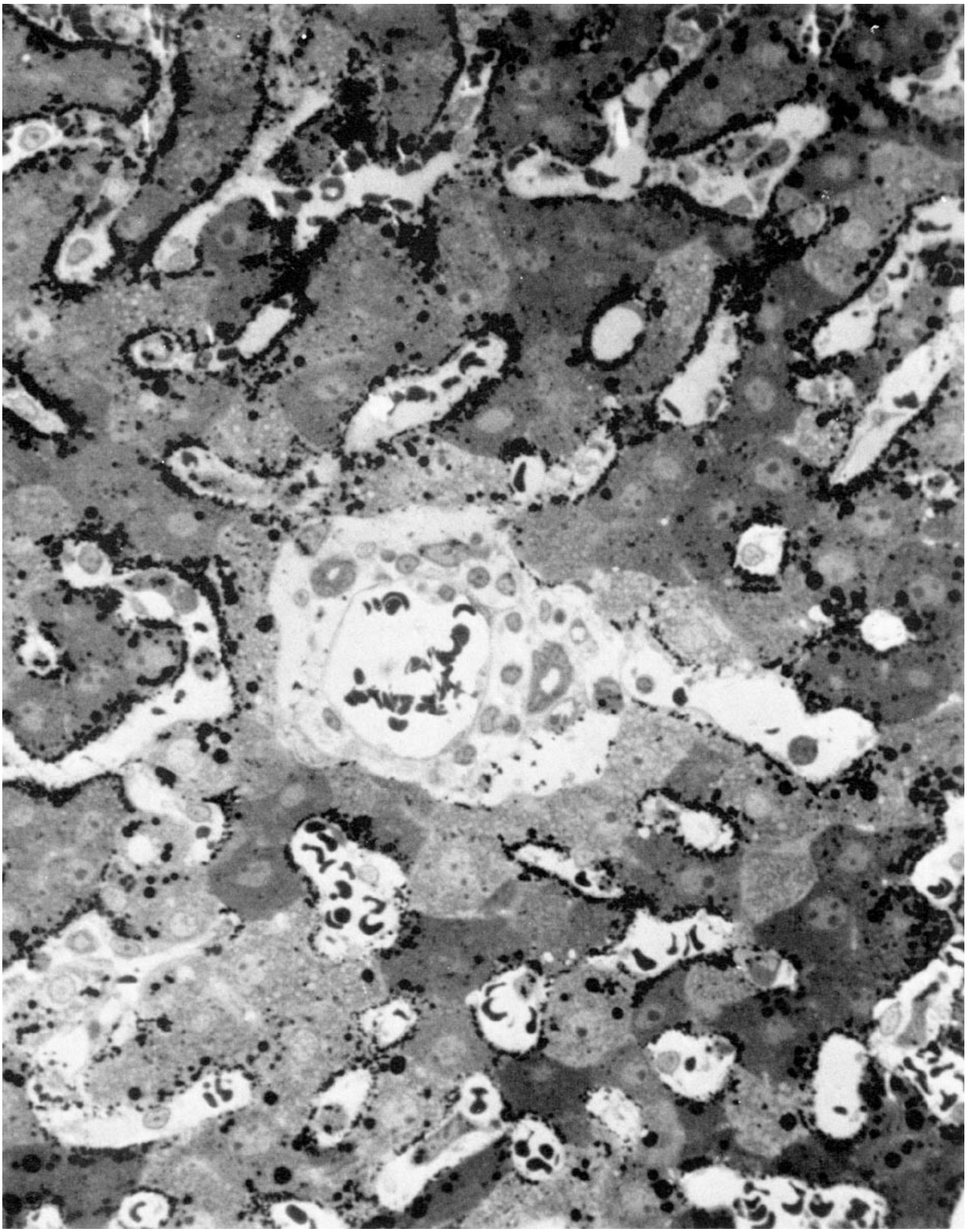

FIGURE 2. Epon-embedded section of the liver of a rat treated for 1 day with 300 mg/kg of tetracycline hydrochloride. Numerous small fat droplets have accumulated about the sinusoids in the spaces of Disse. Some of the periportal cells also show swollen mitochondria. Toluidine blue-safranin stain. ×635.

the foregone understanding that hepatic reactions will continue to occur occasionally during therapy with many useful and necessary drugs.

## REFERENCES


1. Rosenstein, S., and Lamy, P. Drug-induced disease: the liver. Hosp. Formulary Mgmt. 5: 11 (1970).
2. Popper, H., et al. Drug-induced liver injury. Arch. Intern. Med. 115: 128 (1965).
3. Herdson, P., Garvin, P., and Jennings, R. Fine structural changes in rat liver induced by phenobarbital. Lab. Invest. 13: 1032 (1964).
4. Gray. J., et al. Ultrastructural studies of the hepatic changes brought about by clindamycin and erythromycin in animals. Toxicol. Appl. Pharmacol. 19: 217 (1971).
5. Hruban, Z., et al. Focal cytoplasmic degradation. Am. J. Pathol. 42: 657 (1963).
6. Grice, H., et al. Correlation between serum enzymes, isozyme patterns and histologically detectable organ damage. Food Cosmet. Toxicol. 9: 847 (1971).
7. Gray, J., et al. The oral toxicity of clindamycin in laboratory animals. Toxicol. Appl. Pharmacol. 21: 516 (1972).
8. Barka, T., and Popper, H. Liver enlargement and drug toxicity. Medicine 46: 103 (1967).
9. Golberg. L. Liver enlargement produced by drugs: its significance. Proc. Eur. Soc. Study Drug Toxicity 7: 171 (1966).
10. Beyer, K. H., Jr. Perspectives in toxicology. Toxicol. Appl. Pharmacol. 8: 1 (1966).
11. Stein, R., Richter, W., and Brynjolfsson, G. Ultrastructural pharmacopathology 1. Comparative morphology of the livers of the normal street dog and purebred beagle. A base-line study. Exp. Mol. Pathol. 5: 195 (1966).
12. Schofield, B. and Grossman, I. Electron microscopy of hepatic cell lesions induced by electrocution. Arch. Pathol. 86: 208 (1968).
13. Hruban, Z., Sleser, A., and Hopkins, E. Drug-induced and naturally occurring myeloid bodies. Lab. Invest. 27, 62 (1972).
14. Lüllman-Rauch, R. and Reil, G. Chlorphentermine-induced ultra-structural changes in liver tissues of four animal species. Virchows Arch. [Zellpathol]. 13: 307 (1973).
15. Arstila, A. and Trump, B. Studies on cellular autophagocytosis. The formation of autophagic vacuoles in the liver after glucagon administration. Am. J. Pathol. 53: 687 (1968).
16. Balazs, T. Development of tissue resistance to toxic effects of chemicals. Toxicology 2: 247 (1974).
17. Gray, J., et al. Effects of tetracycline in ultrastructure and lipoprotein secretion in the rat hepatocyte. Toxicol. Appl. Pharmacol. 30: 317 (1974).