Environmental Health Perspectives
Vol. 16, pp. 111-118, 1976

Pulmonary Changes Induced by Amphophilic Drugs

by Zdenek Hruban*

Administration of amphophilic drugs to experimental animals causes formation of myeloid bodies in many cell types, accumulation of foamy macrophages in pulmonary alveoli, and pulmonary alveolar proteinosis. These changes are the result of an interaction between the drugs and phospholipids which leads to an alteration in physicochemical properties of the phospholipids. Impairment of the digestion of altered pulmonary secretions in phagosomes of macrophages results in accumulation of foam cells in pulmonary alveoli. Impairment of the metabolism of altered phospholipids removed by autophagy induces an accumulation of myeloid bodies. In summary, administration of amphophilic compounds causes a drug-induced lysosomal disease or generalized phospholipidosis.

In recent years it is becoming increasingly apparent that certain drugs administered systemically to man have serious side effects because of their affinity for the lungs. The pulmonary pathology produced by these drugs has received relatively little clinical attention because of the insiduous and chronic nature of its development. With increasing awareness that a large variety of seemingly harmless drugs can induce such lung changes, it is imperative that more rigorous studies be carried out before such drugs are put to clinical use. The purpose of this report is to review a group of drugs which lead to intra-alveolar histiocytosis.

In 1966 Greselin reported (*1*) that chronic administration of a drug which inhibits cholesterol synthesis, *trans*-1, 4-bis(2-chlorobenzylaminomethyl)cyclohexane dichloride, also called AY-9944, induces accumulation of foam cells in pulmonary alveoli of experimental animals. In the past six years other drugs with different pharmacological effects were shown to produce similar pulmonary side effects. These drugs include the anthistaminic chlorcyclizine and its derivatives (*2*), the hypolipidemic agents triparanol (*2,3*), haloperidol (*2*), boxidine (*2*), and the already mentioned AY-9944 (*1,4*), the chemotherapeutic drug chloroquine (*2*), the anorectic agents chlorphentermine (*3, 5-9*), cloforex (*10, 11*) and fenfluramine (*12*), the tricyclic antidepressants iprindole (*13-16*), 1-chloroaminotryptyline (*17*), imipramine (*18*), and clomipramine (*18*), and the coronary vasodilator 4,4′-diethylaminoethoxyhexestrol (*19*).

These drugs induce essentially similar histological and ultrastructural changes in the lung, although the time required for the appearance of the foam cells and their quantity and size may be quite different in various animal species (*1,7,8,12*). The lungs of the treated animals increase in weight (*1,11*) and contain whitish plaques and nodules on gross examination (*1,2*). Microscopically these plaques consist of intra-alveolar accumulations of foam cells (*1,2*).

The foam cells are between 20 and 80 μm in diameter (*3,4,6,8*) and have a centrally placed nucleus. The cytoplasm is abundant, pale, and finely reticulated in hematoxylin-eosin stained sections (Fig. 1). In toluidine blue-stained Epon

* Department of Pathology, University of Chicago, Chicago, Illinois 60637.

sections, the foam cells are filled with numerous round inclusions (Figs. 2 and 3). Staining of foam

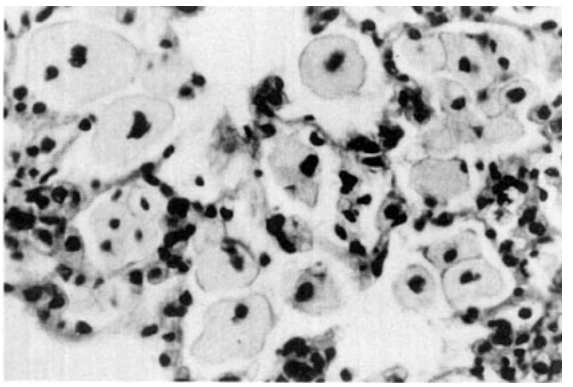

FIGURE 1. Foam cells in alveolar lumina of a rat fed chlorcyclizine. Hematoxylin-eosin, ×350.

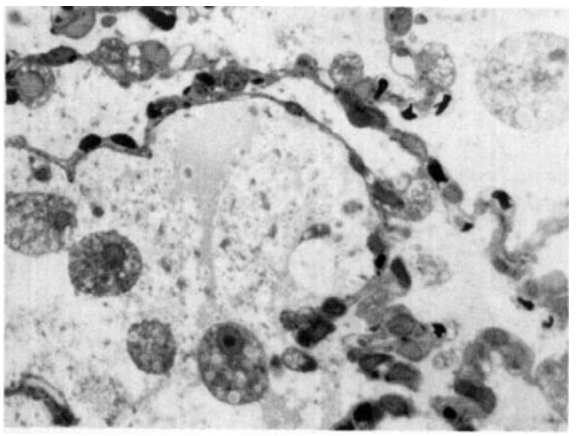

FIGURE 2. Amorphous material and foam cells in alveolar lumina of a rat fed chlorcyclizine for 4 weeks. Granular pneumocytes are seen on alveolar walls. Toluidine blue, thick section; ×450.

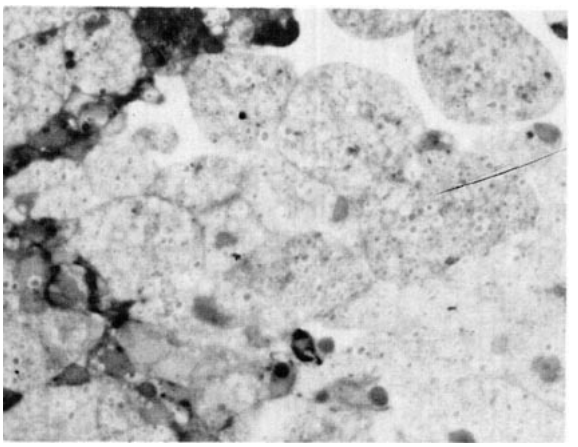

FIGURE 3. Numerous foam cells in alveolar lumina of a rat fed chlorcyclizine for 9 weeks. Toluidine blue, thick section; ×450.

cells with Baker's acid hematein for phospholipids is positive, while staining with Sudan III and by the periodic acid-Schiff method are negative (*2,6,11*). Other staining reactions identify the material in the foam cells as choline-containing phosphoglycerides, including lecithin (*11*). Histochemical studies reveal high activities of acid phosphatase and β-glucuronidase, implicating the foam cells as macrophages (*6,8,13,16*).

The time sequence of pulmonary changes associated with foam cell accumulation has been studied at light and electron microscopic levels. The first change observed in iprindole-treated rats is interstitial pulmonary edema associated with degenerative changes in capillary endothelia (*16*). Subsequently endothelia and alveolar epithelia become swollen and the septa are infiltrated by interstitial macrophages (*16*). The lungs of chlorphentermine-treated rats show hyperemia, aggregation of leucocytes in venules and perivascular infiltration by monocytes during the first week of treatment (*8*). In general a few intra-alveolar macrophages appear early and become progressively larger and more numerous (*2,6,11*). These macrophages are derived from interstitial macrophages (*6,14*), which in turn originate from blood monocytes (*8,10*). In histological sections the alveolar lumina contain abundant amorphous material (Fig. 2), which somewhat resembles the material seen in alveolar proteinosis (*4*). On ultrastructural examination the material is identified as secretions derived from secretory vacuoles of granular pneumocytes (Figs. 4 and 5). It has been shown (*2,9,20*) that the intra-alveolar macrophages phagocytize the secretions, which are rich in dipalmytoyl lecithin (*3*), and become foam cells (Figs. 3 and 6). After 3-6 weeks of treatment, the foam cells are numerous (*2,4,8,13*).

A marked decrease in the secretory activity of type 2 pneumocytes is observed after 9 months of treatment (*15*). After 12 month of iprindole feeding, the accumulations of foam cells are replaced by pale eosinophilic granular material in the intra-alveolar spaces as a result of cellular breakdown, and the histological picture is that of alveolar proteinosis (*15*). Degeneration of macrophages is also seen in rats treated with AY-9944 for prolonged periods (*1*). If the administration of the drug is withdrawn after several weeks of treatment, the size and the number of foam cells will decrease in 2-3 weeks (*2,6*). During this process the secretions in phagosomes of macrophages are replaced by electron dense heterogeneous material (*2*) (Fig. 7).

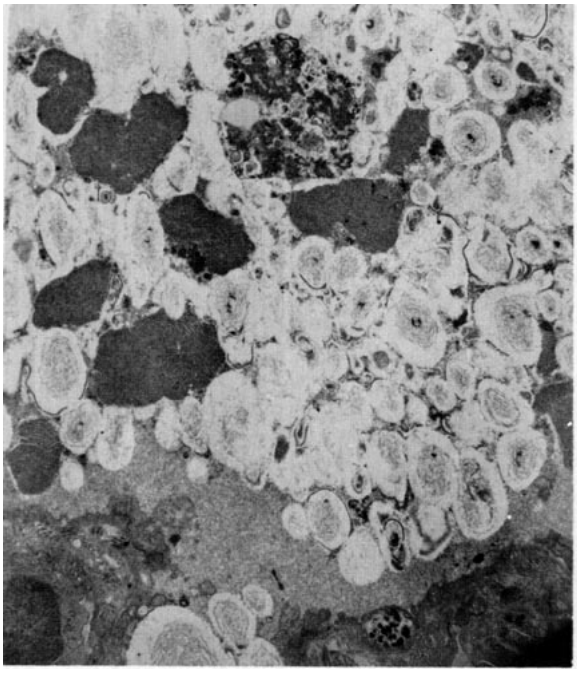

FIGURE 4. Concentric secretions and dense masses of tubular figures in an alveolar lumen of a rat fed chlorcyclizine for 4 weeks. The heterogeneous mass (arrow) may be derived from contents of lysosomes released into alveolar lumen. ×4800.

FIGURE 5. Secretory vacuoles of a granular pneumocyte from a rat fed chlorcyclizine for 9 weeks. ×5600.

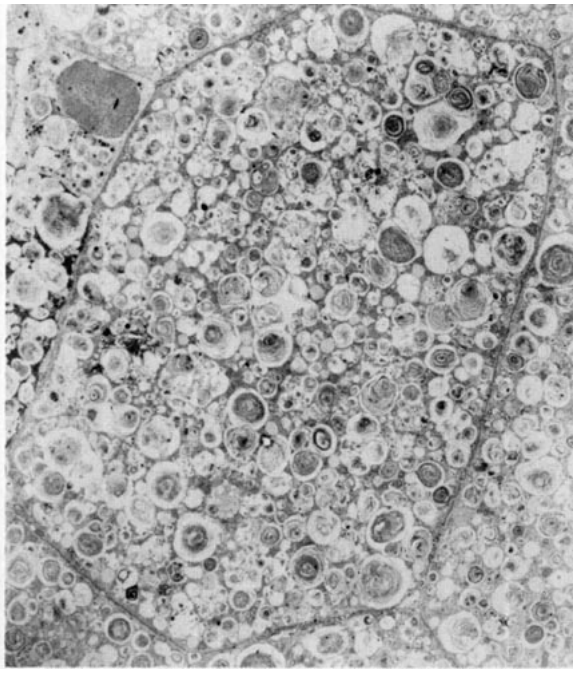

FIGURE 6. Portions of several alveolar macrophages filled with alveolar secretions from a rat treated with chlorcyclizine for 9 weeks. ×2800.

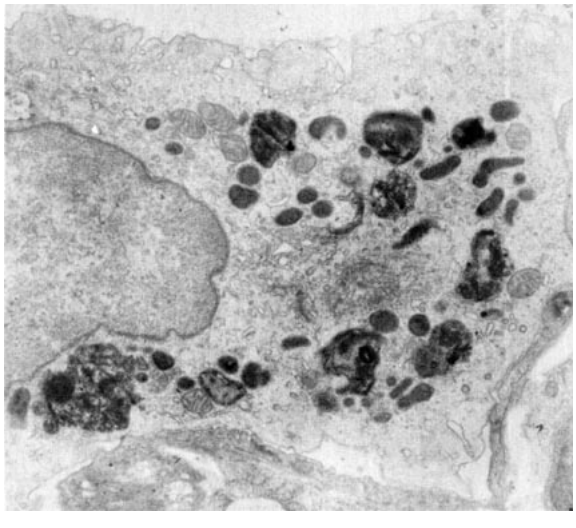

FIGURE 7. Portion of a pulmonary macrophage from a rat treated with chlorcyclizine for 14 weeks and allowed to recover for 2 weeks. ×5600.

Other pulmonary cells also show striking changes. Type 2 pneumocytes become hypertrophic and hyperplastic after triparanol and chlorcyclizine treatment (*2,4*) but do not show changes after chlorphentermine treatment (*6*). The secretory vacuoles of type 2 pneumocytes are large (*2,15*). Myeloid bodies (*21,22*) and heterogeneous dense bodies are found in the cytoplasm of type 1 pneumocytes (Fig. 8), ciliated bronchiolar epithelia and Clara cells, smooth muscle cells, fibroblasts and capillary endothelia (*2–4,15,16,19*). Other investigators refer to the myeloid bodies as concentric lamellar inclusion bodies (*3,6*) and membrane-bound lamellated inclusion bodies (*23*). Heterogeneous dense bodies are secondary lysosomes. Myeloid bodies are lysosomes filled with concentric layers of myeloid membranes

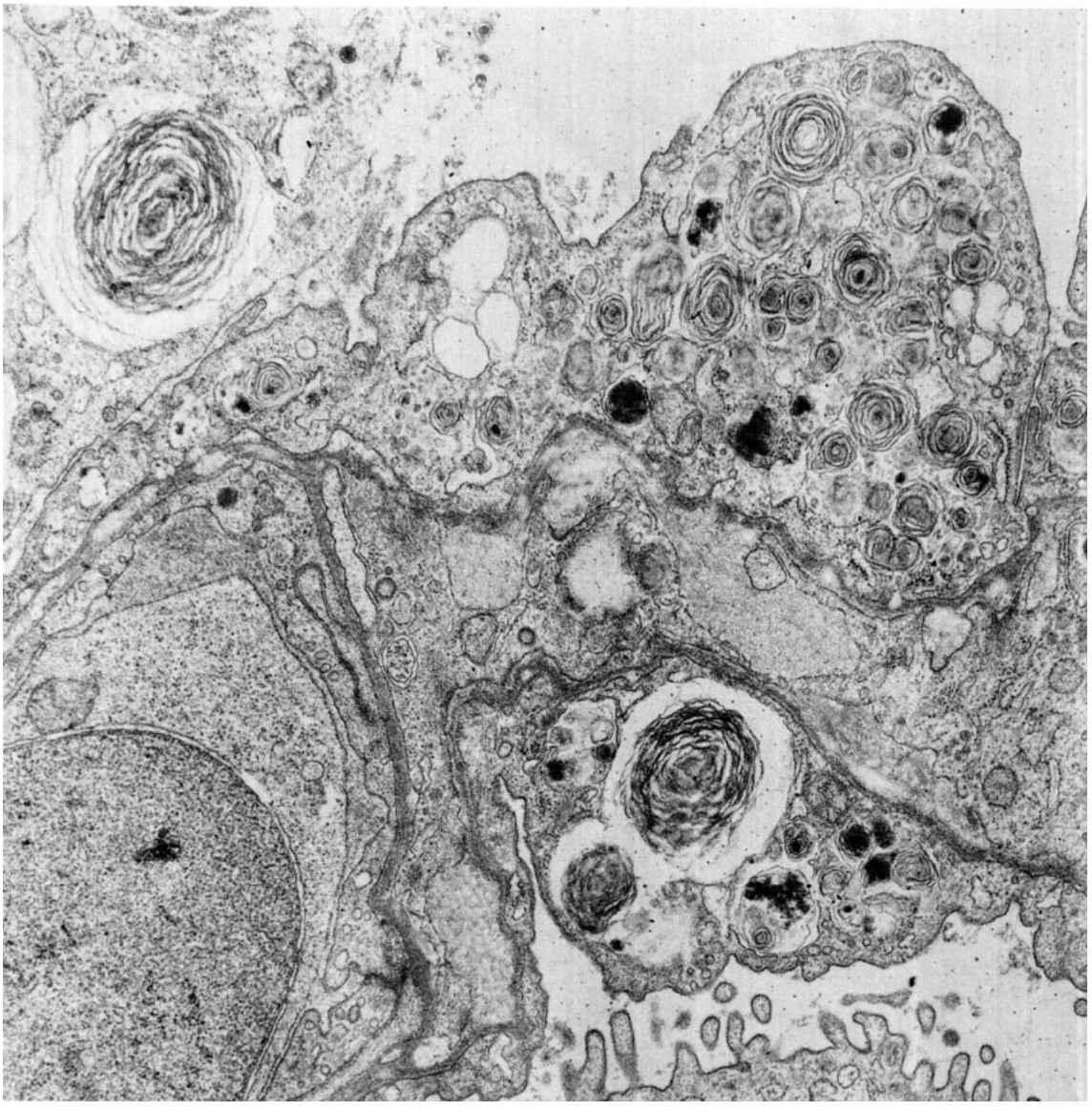

FIGURE 8. Type I pneumocytes from a rat fed chlorcyclizine for 5 weeks. The upper cell contains numerous myeloid bodies. The lower cell contains heterogeneous dense bodies and material resembling alveolar secretions. Portion of a macrophage is seen in left upper corner. ×15,600.

(Fig. 9), although in some cells they may contain reticular or crystalloid structures (*21,22*). Such reticular or crystalloid myeloid bodies were found in various pulmonary cells, but not in pulmonary macrophages (*3*). The drugs which induce accumulations of pulmonary foam cells are also known to induce formation of myeloid bodies in many other cell types of various tissues (*7,22,24*).

Because the inclusions in foam cells and the myeloid bodies are modified lysosomes, knowledge of lysosome formation by heterophagy and by autophagy is necessary to understand their nature (*22*). In autophagy, sequestering cisternae surround a portion of the cytoplasm with organelles and form an autophagic vacuole (Fig. 9). The thin membranes of the sequestering cisterna are transfromed into a thick limiting membrane of the lysosome. Hydrolytic enzymes formed in endoplasmic reticulum are brought to the autophagic vacuole within primary lysosomes. The sequestered organelles are broken down by the

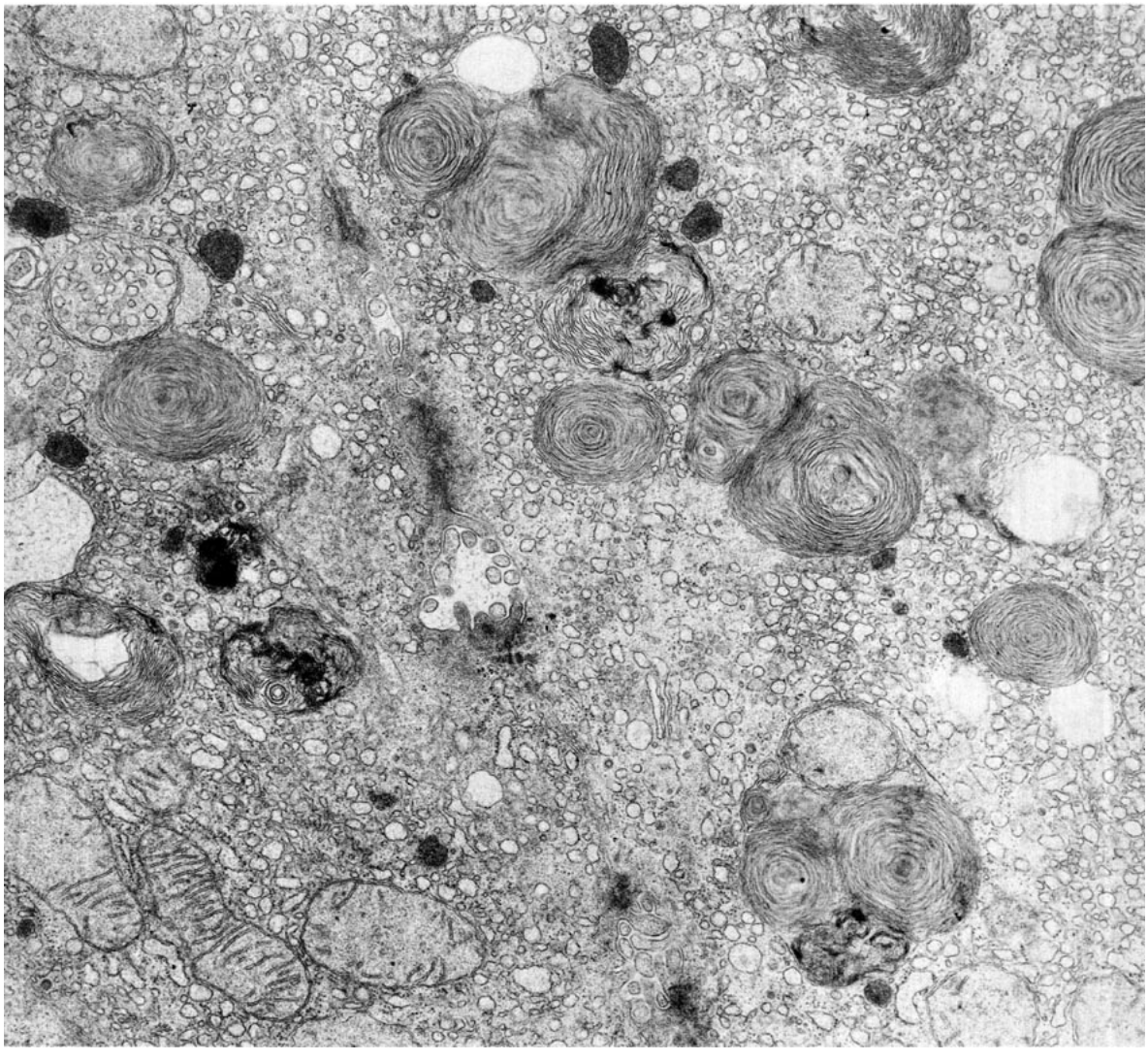

FIGURE 9. Portions of two liver cells from a rat fed chlorcyclizine for 5 weeks. Myeloid bodies are surrounded by a lysosomal membrane. An autophagic vacuole contains sequestered endoplasmic reticulum. A mitochondrion is recognizable in a body which also contains myeloid figures × 11,900.

hydrolytic enzymes and the autophagic vacuole changes into a heterogeneous dense body (secondary lysosome). Further digestion leads to the appearance of smaller homogeneous dense bodies (residual bodies). In heterophagy, the extracellular material enters the cell within pinocytotic vesicles and phagocytic vacuoles. Primary lysosomes empty their enzymes into this vacuole, and the digestion proceeds as in autophagy.

If the degradation of substrates sequestered within lysosomes is impaired, the substrates will accumulate, and the lysosomes will become storage bodies. The impairment of lysosomal digestion may have a variety of causes. Leprosy bacilli are known to inhibit lysosomal digestion in phagosomes. Human storage diseases are caused by the absence of specific lysosomal enzymes. Myeloid bodies are storage bodies containing membranes whose digestion is impaired by drugs (*20*). The inclusions in foam cells are phagosomes storing phagocytized pulmonary secretions whose digestion is impaired by drugs.

The inclusions in foam cells and myeloid bodies are sometimes grouped together as "concentric lamellar inclusion bodies" (*3,6,9*). They are, however, different structurally and etiologically (*2,15,16*). The material within pulmonary macrophages is less densely packed and arranged in a

less orderly fashion than are the myeloid membranes within myeloid bodies (*6,16*). Myeloid body is an autophagosome while the inclusion in the macriphage is a heterophagosome. Some investigators believe that in chorphentermine treated animals autophagy may not precede or be increased during the formation of myeloid bodies (*3,23,25*). Increased autophagy has been, however, observed with other drugs (*2,21,26*). The fact that myeloid bodies show acid phosphatase activity (*6,21,27,28*) and are lysosomes (*6,16,26,28*) indicates that autophagy or heterophagy must be involved in their formation.

Myeloid bodies are surrounded by a lysosomal membrane and should be distinguished from myeloid figures lying free in the cytoplasm or on the surface of mitochondria (*22,29*). Presence of myeloid figures protruding into mitochondria in granular pneumocytes (*30*) and in cells of murine pulmonary tumors originating from type 2 pneumocytes (*31*) does not indicate that myeloid figures are precursors of membrane bound secretions of granular pneumocytes. The structure of pulmonary secretions and of myeloid figures is quite different (*19*) (compare Figs. 5 and 9).

Biochemical studies show that the accumulation of pulmonary foam cells is associated with an increase of lipids. Chlorphentermine treatment leads to a twofold increase of total pulmonary lipids in the rat (*32*) and to a tenfold increase of the lipid content of pulmonary macrophages (*33*). The sphingomyelin. cholesterol, and cholesterol ester fractions are markedly increased while phosphatidylcholine is increased fivefold (*32*). Cloforex increases the cholesterol content of rat lung by 50% and the phospholipid content five times (*1*). A marked increase of the levels of total phospholipids, total sterols, lyso-bisphosphatidic acid, and desmosterol was demonstrated in the lamellar body fraction isolated from lungs of rats treated with diethylaminoethoxyhexestrol (*19*). Desmosterol was also found in fractions containing myeloid bodies induced by inhibitors of cholesterol synthesis (*27,34*). Finally, it has been demonstrated that the drugs inducing foam cell accumulation have a very high affinity for the lung (*4,33,35-37*).

The factors which should be considered in the pathogenesis of intra-alveolar foam cell accumulation are: increased production of surfactant and/or decreased clearance of pulmonary macrophages (*2,4,15*); lipolytic action of the drugs with subsequent excretion of lipids by the lung (*11*); inhibition of fusion of primary lysosomes with phagocytic vacuoles (*38*); accumulation of cholesterol precursors in macrophages (*1,2,4,27*); formation of abnormal "foreign" phospholipids which can not be eliminated by normal pathways (*39*); interaction of drugs with lysosomal lipid-degrading enzymes leading to enzyme inactivation (*6,19,32,39*); interaction between the drugs and lipids leading to an alteration in physicochemical properties of the lipid (*2,3,6,8,32,39*). The last possibility has gained the most support. The molecules of chlorphentermine, triparanol and of the other drugs mentioned earlier have amphophilic character (*3,7,8*). One part of the molecule contains protonated nitrogen and has hydrophilic properties. The aromatic portion of the molecule, particularly with certain substitutions on the ring, is hydrophobic. The amphophilia of the drugs facilitates complex formation with amphophilic phospholipids (*3*). An interaction between chlorphentermine and phospholipids has been demonstrated by nuclear magnetic resonance studies (*40*).

It is believed that the formation of a complex between the drug and the phospholipid leads to an alteration in physicochemical properties of the phospholipid and impairs its metabolism in phagosomes and in lysosomes (*2, 3, 40*). In the lung the drugs bind to phospholipids such as dipalmitoyl lecithin of pulmonary secretions in granular pneumocytes. These secretions are released into alveolar lumina, where they are taken up by pulmonary macrophages. Because of impaired digestion, the secretions persist and accumulate, and the macrophages become foam cells. Similar drug binding occurs in various cells in the body. The drugs react with phospholipids of cellular membranes and the altered membranes are removed by autophagy. The sequestered proteins and carbohydrates are broken down by lysosomal enzymes while the drug-lipid complexes resist digestion and are transformed into myeloid membranes. Thus a myeloid body is formed. For these reasons, the formation of foam cells and of myeloid bodies can be considered a drug-induced lysosomal disease (*28*) or a drug-induced generalized phospholipidosis (*6-8*).

The drug-induced lipidoses are side effects of drugs and do not depend on the pharmacological actions of the drugs (*8*). The anorectic drugs have been associated with pulmonary hypertension in man. These vascular effects are related to an ~~altered~~ metabolism of serotonin rather than to foam cell accumulation (*41*). The accumulation of pulmonary foam cells and of myeloid bodies may, however, be associated with serious clinical problems. Functional impairment of overloaded mac-

rophages may lead to a decreased resistance to bacterial and fungal infections (*21*). Massive accumulation of myeloid bodies may cause cellular damage and death. Administration of chloroquine has been associated with retinopathy in man (*42*). Hyperlipidemia, hepatosplenomegaly, liver cell necrosis and cirrhosis have been reported in patients treated with diethylaminoethoxyhexestrol (*19,26,43*).

Side effects of some of the discussed drugs were discovered only after they were used in men. Most probably other drugs will have similar side effects (*44*). It is therefore imperative to search for myeloid body formation when new drugs are introduced. In animal experiments, massive accumulation of pulmonary foam cells is an excellent indicator of a drug-induced lipidosis. It should be remembered, however, that foam cells occur in other pathological entities (*1*) and in old normal rats (*45*). In clinical trials the peripheral blood is easily accessible for ultrastructural studies. Lymphocytes and plasma cells respond to amphophilic drugs by formation of myeloid bodies in animals and in man (*12,23,28*).

The intra-alveolar accumulation of foamy macrophages is a form of pulmonary histiocytosis (*2,15*). Massive accumulation of intra-alveolar histiocytes and hyperplasia of granular pneumocytes are found also in human and experimental desquamative interstitial pneumonia (*46-51*). The macrophages are, however, smaller, lack foamy appearance, and contain PAS-positive granules. Necrosis is absent.

Administration of busulfan, hexamethonium, apresoline and antituberculous drugs may be associated with hypertrophy of granular pneumocytes. The essential feature of the "busulfan lung" is chronic pulmonary fibrosis and does not resemble lesions induced by amphopilic drugs (*52-54*).

The drug-induced pulmonary lipidosis (*15*) and desquamative pneumonia in man (*55*) may progress to alveolar proteninosis. The alveoli in alveolar proteinosis are filled with amorphous, protainaceous, PAS-positive material which is rich in lipids and contains phospholipids (*56-58*). For this reason the term alveolar lipo-proteinosis is more exact (*58*). The intra-alveolar material is mostly derived from disintegrated macrophages (*59*) and pneumocytes (*57,58,60*). Alveolar proteinosis is observed in acute silicosis (*20,60,61*) and as a response to a variety of nonspecific chemical irritants (*59*).

In summary, the drug-induced pulmonary histiocytosis is a manifestation of a generalized drug-induced lysosomal storage disease (or lipidosis). The use of the electron microscope greatly facilitates the search for drug-induced side effects at the cellular level.

This study was supported in part by Cancer Research Center Grant CA 14599 from the National Cancer Institute, National Institutes of Health.

REFERENCES

1. Greselin, E. An inhibitor of cholesterol biosynthesis and the alveolar macrophages. Can. J. Comp. Me. 30: 121 (1966).
2. Hruban, Z., Slesers, A. and Aschenbrenner, I. Pulmonary intra-alveolar histiocytosis induced by drugs. Toxicol. Appl. Pharmacol. 26: 72 (1973).
3. Lüllmann, H., Lüllmann-Rauch, R., and Reil, G. H. A comparative ultrastructural study of the effects of chlorphentermine and triparanol in rat lung and adrenal gland. Virchows Arch. B 12: 91 (1973).
4. Kikkawa, Y., and Suzuki, K. Alterations of cellular and acellular alveolar and bronchiolar walls produced by hypocholesteremic drug AY 9944. Lab. Invest. 26: 441 (1972).
5. Franken, G., Lullmann, H., and Siegfried, A. The occurrene of huge cells in pulmonary alveoli of rats treated by an anorexic drug. Arzneimittel-Forsch. 20: 417 (1970).
6. Lüllman-Rauch, R., et al. The ultrastructure of rat lung changes induced by an anorectic drug (chlorphentermine). Virchows Arch. B 11: 167 (1972).
7. Lüllmann-Rauch, R., and Reil, G. H. Chlorphentermine-induced lipidosislike ultrastructural alterations in lungs and adrenal glands of several species. Toxicol. Appl. Pharmacol. 30: 408 (1974).
8. Parwaresch, M. R., Reil, G. H., and Seiler, K. U. Über die Tier- und Organspezifität morphologischer Veränderungen nach chronischer Chlorphentermingabe. Res. Exp. Med. 161: 272 (1973).
9. Smith, P., Heath, D., and Hasleton, P. S. Electron microscopy of chlorphentermine lung. Thorax 28: 559 (1973).
10. Flodh, H., and Magnusson, G. Genesis of foam cells: study in rats after administration of cloforex. Virchows Arch. 12: 360 (1973).
11. Magnusson, G., and Magnusson, O. Cloforex-induced pulmonary changes in rats. Beitr. Pathol. 146: 79 (1972).
12. Lullmann-Rauch, R., and Reil, G. H. Fenfluramine-induced ultrastructural alterations in tissues of rats and guinea pigs. Naunyn-Schmiedeberg's Arch. Pharmacol. 285: 175 (1974).
13. Vijeyaratnam, G. S., and Corrin, B. Pulmonary histiocytosis simulating desquamative interstitial pneumonia in rats receiving oral iprindole. J. Pathol. 108: 105 (1972).
14. Vijeyaratnam, G. S., and Corrin, B. Origin of the pulmonary alveolar macrophage studied in the iprindole treated rat. J. Pathol. 108: 115 (1972).
15. Vijeyaratnam, G. S., and Corrin, B. Pulmonary alveolar proteinosis developing from desquamative interstitial pneumonia in long toxicity studies in the rat. Virchows Arch. 358: 1 (1973).
16. Vijeyaratnam, G. S., and Corrin, B. Fine structural alterations in the lungs of iprindole-treated rats. J. Pathol. 114: 233 (1974).
17. Theiss, E., et al. Lipidspeicherung bei Versuchstieren nach Verabreichung trizyklischer Amine. Schweiz. Med. Wochenschr. 103: 424 (1973).

18. Lüllmann-Rauch, R., Reil, G. H., and Scheid, D. Lipidosis-ähnliche Zellveränderungen bei der Ratte nach Behandlung mit Thymoleptika. Verh. Deut. Ges. Pathol. 57: 425 (1973).
19. Akeda, S. A study on the lipidosis induced by a coronary vasodilator, 4,4′-diethylaminoethoxyhexestrol dihydrochloride. Mie Med. J. 22: 65 (1972).
20. Corrin, B., and King, E. Experimental endogenous lipid pneumonia and silicosis. J. Pathol. 97: 325 (1969).
21. Hruban, Z., Swift, H., and Slesers, A. Effect of triparanol and diethanolamine on the fine structure of hepatocytes and pancreatic acinar cells. Lab Invest. 14: 1652 (1965).
22. Hruban, Z., Slesers, A., and Hopkins, E. Drug-induced and naturally occuring myeloid bodies. Lab Invest. 27: 62 (1972).
23. Lullmann-Rauch, R., and Pietschmann, N. Lipidosis-like cellular alterations in lymphatic tissues of chlorphentermine-treated animals. Virchows Arch. B 15: 295 (1974).
24. Read, W. K., and Bay, W. W. Basic cellular lesion in chloroquine toxicity. Lab. Invest. 24: 246 (1971).
25. Lüllmann-Rauch, R., and Reil, G. H. Chlorphentermine-induced ultrastructural changes in liver tissues of four animal species. Virchows Arch. B 13: 307 (1973).
26. Itoh, S. and Tsukada, Y. Clinico-pathological and electron microscopical studies on a coronary dilating agent: 4,4′-diethylaminoethoxyhexestrol-induced liver injuries. Acta Hepato-gastroenterol. 20: 204 (1973).
27. Dietert, S. E., and Scallen, T. J. An ultrasructural and biochemical study of the effects of three inhibitors of cholesterol biosynthesis upon murine adrenal gland and testis. J. Cell Biol. 40: 44 (1969).
28. Kitani, T., et al. Drug-induced lipidosis (IV). Morphological aspect of leucocytes and bone marrow cells in human cases and animal experiments induced by 4,4′-diethylaminoethoxyhexestrol. Acta. Haem. Jap. 35: 131 (1972).
29. Le Beux, Y., Hetenyi, G., and Philips, M. J. Mitochondrial myelin-like figures: A non-specific reactive process of mitochondrial phospholipid membranes to several stimuli. Z. Zellforsch Mikrosk. Anat. 99: 491 (1969).
30. Pattle, R. E., et al. Lung surfactant and organelles after an exposure to dibenzoxazepine. Brit. J. Pathol. 55: 213 (1974).
31. Flaks, B., and Flaks, A. Electron microscope observations on formation of cytoplasmic lamellar inclusion-bodies in murine pulmonary tumors induced *in vitro*. J. Pathol. 108: 211 (1972).
32. Seiler, K. U., and Wassermann, O. Drug induced phospholipidosis. II. Alterations in the phospholipid pattern of organs from mice, rats and guinea pigs after chronic treatment with chlorphentermine. Naunyn-Schmiedeberg's Arch. Pharmacol. 288: 261 (1975).
33. Schmien, R., Seiler, K. U., and Wassermann, O. Drug-induced phospholipidsis. I. Lipid composition and chlorphentermine content of rat lung tissue and alveolar macrophages after chronic treatment. Naunyn-Schiedeberg's Arch. Pharmacol. 283: 331 (1974).
34. Yates, R. D., Arai, K., and Rappoport, D. A. Fine structure and chemical composition of opaque cytoplasmic bodies of triparanol-treated Syrian hamsters. Exptl. Cell. Res. 47: 459 (1967).
35. Eichelbaum, M., Hengstmann, J. H., and Dengler, H. J. Das Verteilungsmuster des Chlorphentermins bei Ratte, Kaninchen und Schwein. Naunyn-Schmiedeberg's Arch. Pharmacol. 267: 446 (1970).
36. Kuntzman, R., et al. Physiological distribution and metabolic inactivation of chlorcyclizine and cyclizine. J. Pharmacol. Exptl. Therap. 149: 29 (1965).
37. Ryrfeldt, A. The distribution, elimination, and biotransformation of ^{14}C-Cloforex in the mouse and rat. Acta Pharmacol. Toxicol. 28: 391 (1970).
38. Abraham, R., and Hendy, R. Effects of chronic chloroquine treatment on lysosomes of rat liver cells. Exptl. Mol. Pathol. 12: 148 (1970).
39. De La Iglesia, I. A., et al. Morphologic studies on secondary phospholipidosis in human liver. Lab. Invest. 30: 539 (1974).
40. Seydel, J. K., and Wassermann, O. NMR studies on the molecular basis of drug-induced phospholipidosis. I. Interaction between chlorphentermine and phosphatidylcholine. Naunyn-Schmiedeberg's Arch. Pharmacol. 279: 207 (1973).
41. Mielke, H., et al. Über eine Beziehung zwischen dem Serotoninstoffwechsel und der pulmonalen Hypertonie bei Ratten nach Gabe verschiedener Anorektika. Z. Kardiol. 62: 1090 (1973).
42. Hobbs, H. E., Sorsby, A., and Freedman, A. Retinopathy following chloroquine therapy. Lancet (II): 478 (1959).
43. Shikata, T., et al. Drug-induced generalized phospholipidosis. Acta Pathol. Jap. 22: 517 (1972).
44. Gray, J. E., et al. Ultrastructural studies of the hepatic changes brought about by clindamycin and erythromycin in animals. Toxicol. Appl. Pharmacol. 19: 217 (1971).
45. Flodh, H., Magnusson, G., and Magnusson, O. Pulmonary foam cells in rats of different age. Z. Versuchstierk. 16: 299 (1974).
46. Brewer, D. B., and Asquith, P. Electron microscopy of desquamative interstitial pneumonia. J. Pathol. 97: 317 (1969).
47. Corrin, B., and Price, A. B. Electron microscopic studies in desquamative interstitial pneumonia associated with asbestos. Thorax 27: 324 (1972).
48. Farr, G. H., Harley, A., and Henningar, G. R. Desquamative interstitial pneumonia. Amer. J. Pathol. 60: 347 (1970).
49. Heath, D. Desquamative interstitial pneumonia. Thorax 23: 330 (1968).
50. Rhodes, M. L. Desquamative interstitial pneumonia. New ultrastructural findings. Am. Rev. Respir. Dis. 108: 950 (1973).
51. Shortland, J. R., Darke, C. S., and Crane, W. A. J. Electron microscopy of desquamative interstitial pneumonia. Thorax 24: 192 (1969).
52. Littler, W. A., et al. Bisulphan lung. Thorax 24: 639 (1969).
53. Oliner, H., et al. Interstitial pulmonary fibrosis following busulfan therapy. Amer. J. Med. 31: 134 (1961).
54. Spencer, H. Pathology of the Lung. Pergamon Press, New York, 2nd ed., 1968.
55. Bhagwat, A. G., Wentworth, P., and Conen, P. E. Observations on the relationship of desquamative interstitial pneumonia and pulmonary alveolar proteinosis in childhood: A pathologic and experimental study. Chest 58: 362 (1970).
56. Rosen, S. H., Castleman, B., and Liebow, A. A. Pulmonary alveolar proteinosis. New Engl. J. Med. 258: 1123 (1958).
57. Kuhn, C. et al. Pulmonary alveolar proteinosis. A study using enzyme, histochemistry, electron microscopy and surface tension measurements. Lab Invest. 15: 492 (1966).
58. Heppleston, A. G., Wright, N. A., and Stewart, J. A. Experimental alveolar lipo-proteinosis following the inhalation of silica. J. Pathol. 101: 293 (1970).
59. Davidson, J. M., and Macleod, W. M. Pulmonary alveolar proteinosis. Brit. J. Dis. Chest 63: 13 (1969).
60. Lamberty, J., Hoffmann, E., and Pizzolato, P. The ultrastructure of acute silicosis in humans. Am. J. Pathol. 70: 34a (1973).
61. Hoffmann. E. O., et al. The ultrastructure of acute silicosis. Arch. Pathol. 96: 104 (1973).