Environmental Health Perspectives
Vol. 18, pp. 55-60, 1976

Comparative Development of the Nervous, Respiratory, and Cardiovascular Systems

by Ian W. Monie*

The timing of some key embryological events is given for man, rat, chick, and certain other animals. Such times, however, are approximations, and variations occur among members of the same strain and even among members of the same litter. Some differences in developmental patterns are indicated.

This paper attempts to describe and tabulate the times at which comparable stages in the development of the nervous, respiratory, and cardiovascular systems occur in different animals. Since genetic and environmental factors influence rate of development, and investigators may differ as to the way of calculating the duration of gestation as well as to when an organ is actually established, it must be emphasized that all times given are subject to variation.

Many sources (*1-21*) have been consulted in regard to timings and to features of development. The tables provided by Altman and Dittmer (*1*), and by Shepard (*15*), have been found especially useful.

Since time of fertilization is not determinable, ovulation age has been used for man and the macaque, and ovulation or copulation age for other mammals. In the case of the rat, the times given agree fairly well with those for the Long-Evans rats in our colony where the day of finding sperm in the vagina is called day zero.

Times shown for the chick are incubation days, it being remembered that when the egg is laid development is already about 24 to 36 hr under way. The rate of development of birds, however, is greatly influenced by temperature.

*Department of Anatomy, University of California, San Francisco, San Francisco, California 94143.

Embryos may be classified according to age, length, weight, or the number of somites in the case of young specimens. However, since embryos of the same chronological age may develop at different rates, schemes have been devised for classifying them according to the degree of development attained. Among these are Streeter's horizons for human embryos, Witschi's standard stages, and the chick stages of Hamburger and Hamilton (*1*). For the purpose of this presentation, age in days has been selected as the most practical means for determining approximately when a particular event is occurring in embryos of different species.

In the figures the diagrams of organs reflect the appearance of those in man. Where configurations are significantly different in other animals these are mentioned in the text.

Stages of Gestation

The approximate times of certain key embryological events are given for various mammals and the chick in Table 1. Development of the mouse is generally similar to that of the rat, except that it is in advance of the latter by about 1.5 days in the early stages, and by about 2.0 days in the later stages, of gestation. In sheep, implantation occurs around day 10 or later.

Average gestation periods in days for some animals other than those shown in Table 1 are:

Table 1. Stages of gestation.

Animal	Time, days					
	Implantation	Primitive streak	Neural tube closed	Lower limb bud	Hand rays	Gestation period
Man	7.5	16	28	32	37	267
Macaque	9	19	26?	27	34	166
Guinea pig	6	13.5	16.5?	18.5	23.5	66
Rabbit	7.5	7	10?	11	14.5	32
Rat	6	9	11.5	12	14	22
Mouse	6	7	9.5	10.3	12.3	19
Hamster	5	7	8.5	9.75	10.25	16
Chick	—	0.5	3.75	3	4.75	21

opossum 13; dog, 61; cat, 63; pig, 115; sheep, 150; cattle, 280; horse, 340; and elephant, 640.

Generally, where gestation is short, embryonic development is rapid and the number of young in a litter is large. In the latter case, littermates may differ noticeably in rate of development in the early stages, but in the later stages differences tend to be much less.

Nervous System

The nervous system has its origin in the neural plate (Fig. 1) in the ectoderm of the embryonic disc. The margins of the plate become ridges or folds which grow towards each other and unite to form the neural tube. The latter first closes in its central portion, which corresponds to the future brainstem region, and union then proceeds towards either end. The last open portions of the neural tube are the anterior and posterior neuropores, which in man close about day 25 and day 27, respectively; corresponding figures in days for some other animals are: rat, 10.5-11.0; chick, 2.3-3.75; macaque, 24-26; mouse, 9.0-9.5; rabbit, 9.5-10.5?; hamster, 8.25-8.5; and guinea pig, 15.25-16.5. The cranial end of the neural tube segments into the three brain vesicles, namely the prosencephalon, mesencephalon, and rhombencephalon; the first of these gives rise to the brain and the remainder to the brain stem. Next, the prosencephalon divides into the telencephalon and the diencephalon, and the rhombencephalon into the metencephalon and myelencephalon;

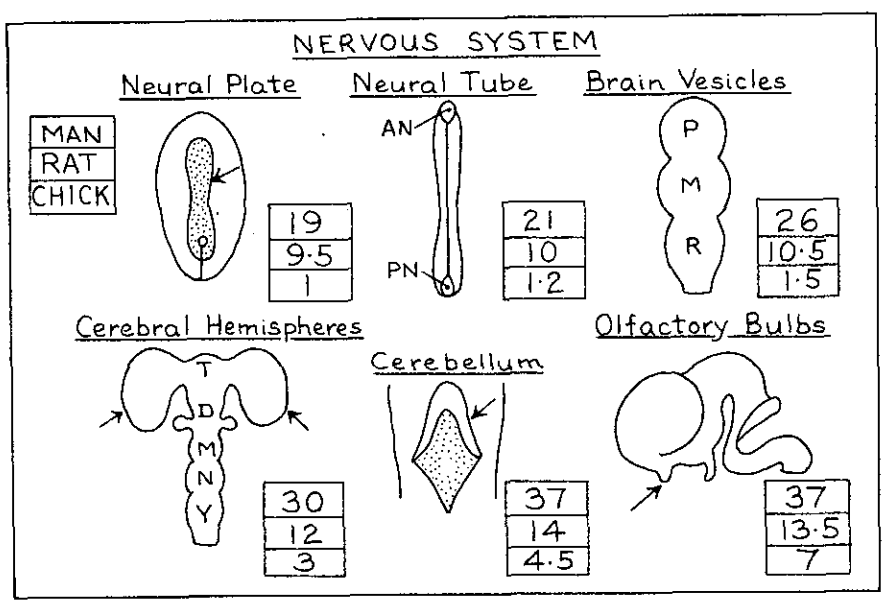

FIGURE 1. Development of nervous system. All figures are time in days. AN, anterior neuropore; D, diencephalon; M, mesencephalon; N, metencephalon; P, prosencephalon; PN, posterior neuropore; R, rhombencephalon; T, telencephalon; Y, myelencephalon.

from the telencephalon arise the cerebral hemispheres. The brain stem develops flexures (cephalic, pontine, and cervical) giving it a sigmoid configuration when viewed laterally. Thickening of the cranial margin of the thinned roof of the fourth ventricle produces the cerebellum, while from the inferior aspects of the telencephalon spring olfactory bulbs which advance towards the developing nasal region.

In the chick, the cerebral hemispheres remain small, while the optic lobes, midbrain, and cerebellum are well developed.

Neural crest cells migrate from the summits of the neural folds prior to closure and give rise to peripheral and autonomic ganglia, adrenal medulla, and a variety of other structures.

Myelination begins in the cord and brainstem of the human fetus about the fifth or six month of gestation, and in the corticospinal (pyramidal) tracts is not completed until between the second and third years. In the rat, there is little myelin in the nervous system at birth, but thereafter myelination steadily advances and is quite active by the 10th day (*22*). In the chick, myelination of the central and peripheral nervous systems commences about day 15 of incubation (*23*).

Movement can be elicited in the neck of the human fetus between 7 and 8 weeks, in the neck of the rat fetus about day 16, and in the neck of the chick during day 3 of incubation (*22*).

Special Senses

Eye

The optic vesicle (Fig. 2), arising from the diencephalon, invaginates to form the optic cup and induces the lens placode in the overlying ectoderm. The latter sinks inwards, forming a cup, then a vesicle, which gradually loses its cavity as it forms the definitive lens. The inner layer of the optic cup becomes the retina, and axons from its nerve cells gradually extend as optic nerve fibers along the optic stalk to the brain. The retinas of man and chick contain both rods and cones, but that of the rat has only rods. The retina of the rat is immature at birth and development in the postnatal period is considerable.

In man, rat, and many other mammals the eyelids fuse, then separate after a period of time; the latter event occurs postnatally in the rat. The eyelids of the chick approximate but do not fuse.

The cornea, sclera, and the choroid are derived from condensations of mesenchyme.

Ear

The otic vesicle (fig. 2) which forms the inner ear is derived from ectoderm. It eventually develops a ductus endolymphaticus, cochlea, and three out-pouchings which become the semicircular canals. Laternal to it, an upward extension

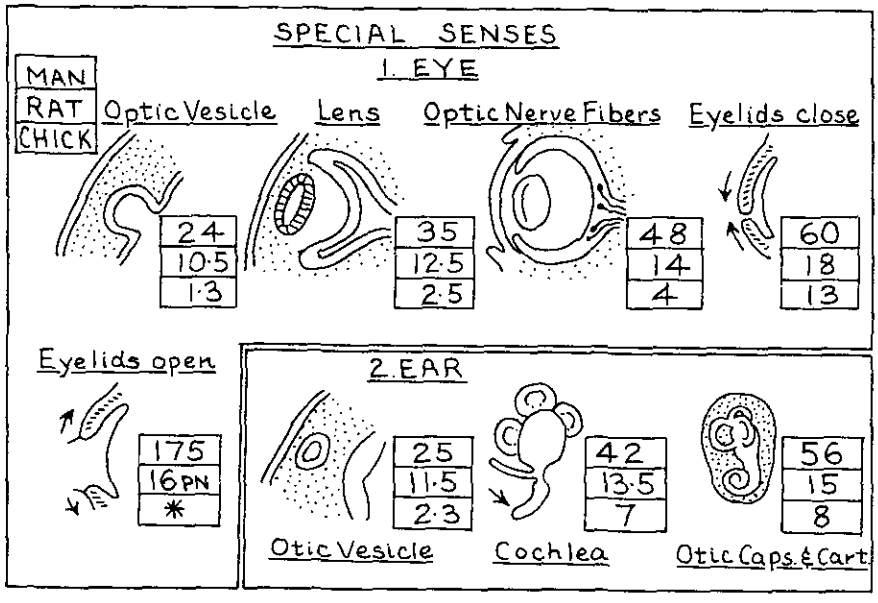

FIGURE 2. Development of organs of special senses. All figures are time in days.

from the pharynx forms the pharyngotympanic tube, the middle ear, and the mastoid antrum. The upper end of the first external pharyngeal cleft establishes the external auditory meatus.

In mammals, the three ear ossicles (malleus, incus, and stapes) develop mainly from the dorsal ends of the first and second branchial arch cartilages. In the chick, however, these ossicles are replaced by the columella which is homologous with the stapes.

The inner ear becomes surrounded by the cartilaginous otic capsule which later ossifies and forms part of the temporal bone.

Respiratory System

The respiratory rudiment (Fig. 3) arises from the laryngotracheal groove on the ventral aspect of the foregut. It forms a short tube which bifurcates into buds, the repeated divisions of which soon result in an asymmetrical pattern reflecting the definitive form of the lungs. Eventually, the major bronchial divisions are recognizable, as well as the finer components of the lung substance. In man about 18 generations of divisions take place before birth and about another 6 generations thereafter. The human right lung consists of three lobes and the left lung of two lobes but in the rat, the right lung has four lobes and the left lung, one lobe. The respiratory rudiment appears in the hamster on day 9, and in the guinea pig on day 17.5.

The mammalian lung passes through glandular, canalization, and vascularization phases; in man, the last two of these occur approximately during the fifth and sixth months of fetal life, respectively. In order that the moist surfaces of the lung alveoli may re-expand readily after expiration once breathing commences, surfactant, a phospholipid, is secreted into their lumina by type II cells. In man, surfactant appears about the 25th week (*24*) and sufficient is usually present by the 35th week for the lung to be considered mature (*25*). The days of gestation on which surfactant is found in some other animals is as follows: mouse, 18, rabbit, 27; and lamb, 124 (*26*). In the rat fetus it is present on day 19 (personal observation, Mary C. Williams).

In birds, the lung has a basically different form from that of the mammal, and alveoli and air sacs are replaced by air capillaries, looplike channels which arise from, and terminate in, the parabronchi. In the chick embryo, surfactant becomes detectable as the air capillaries form between days 16 and 18. In the same animal, respiratory movements gradually begin a few days before hatching.

In the lungs of man and lamb, vascular resistance is high during fetal life, but increased oxygen tension in the blood stream as a result of respiration causes dilatation of the pulmonary arterioles.

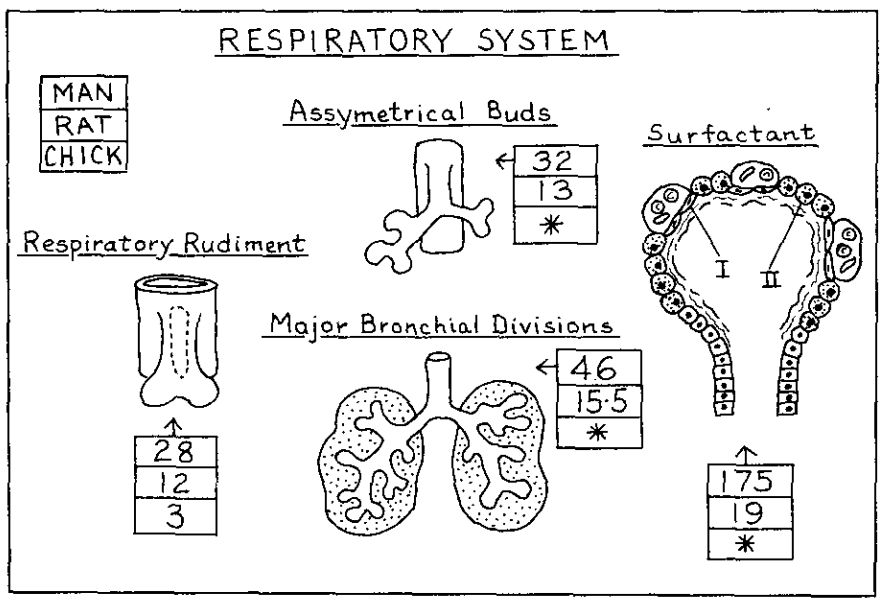

FIGURE 3. Development of respiratory system. All figures are time in days. I, type I cell; II, type II cell; * see text.

Cardiovascular System

Two heart tubes develop at the head end of the embryonic disc and fuse to form a single heart tube (Fig. 4). The latter undergoes segmentation into a series of communicating chambers, namely, sinus venosus, primitive atrium, primitive ventricle, and bulbus cordis, the last-mentioned being connected by the truncus arteriosus to the paired ventral aortae. Blood enters the sinus venosus and leaves by the truncus arteriosus. With continued growth the heart tube becomes S-shaped and within it chamber sepatation commences. The primitive atrium gives rise to the definitive right and left atria, the sinus venosus being incorporated into the former. The bulbus cordis forms the right ventricle as well as the commencement of the pulmonary trunk and the aorta, while the primitive ventricle becomes the left ventricle. In mammals, the foramen ovale of the interatrial septum remains until birth and allows blood to pass from the right to the left atrium; in the chick, instead of a single opening in this septum there are multiple perforations. The interventricular foramen ceases to allow the passage of blood between the ventricles once truncal septation is complete. The latter event also leads to the establishment of the aorta and the pulmonary trunk. In hamster and guinea pig embryos, cardiac and truncal septation is complete about day 11 and day 26, respectively.

Days on which heart beats first appear are: man, 22?; rat, 10.2; hamster, 8; guinea pig, 16.5; and chick, 1.5.

Six pairs of aortic arch arteries appear in sequence but are not all present at the same time. Fifth arch vessels may fail to form or are rudimentary. The third, fourth, and sixth arch arteries remain in whole or in part in the mammal as the carotids, right subclavian, aortic arch, and the pulmonary arteries (Fig. 4).

The lateral part of the left sixth arch persists in mammals as the ductus arteriosus, while the descending aorta is formed from the left dorsal aorta. In the chick, there is both a right and left ductus arteriosus, and the descending aorta is derived from the right dorsal aorta. First aortic arch arteries are seen in the hamster on day 7.75 and in the guinea pig about day 15.5.

With the commencement of respiration, equalization of pressures within the right and left atria results in the cessation of blood flow from the former to the latter chamber. This is due to the flap-like caudal portion of the interatrial septum being brought against its cranial portion. In birds, functional closure of the multiple openings in the interatrial septum is thought to be due to relaxation of the septum which formerly bulged into the left atrium.

In the chick, respiratory movements occur, and pulmonary blood flow gradually increases, about two to three days prior to hatching.

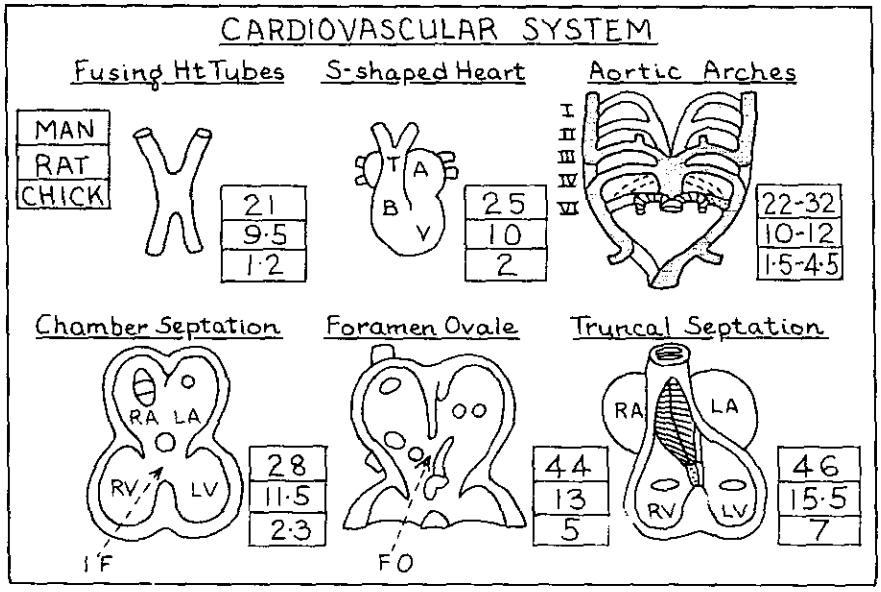

FIGURE 4. Development of cardiovascular system. All figures are time in days. A, primitive atrium; B, bulbus cordis; FO, foramen ovale; IF, interventricular foramen; LA, left atrium; LV, left ventricle; RA, right atrium; RV, right ventricle; T, truncus arteriosus; V, primitive ventricle, I - VI, aortic arch arteries.

The mammalian ductus arteriosus closes after birth in two stages, the first being functional and the second anatomical (*27*). Primary closure, due to contraction of muscle in the ductus wall, occurs a few minutes after birth in the guinea pig and rabbit, and about 10 to 15 hr after birth in man. Secondary closure from fibrosis takes 3 to 5 days in the rat, guinea pig, rabbit and lamb, whereas in man this process occupies several weeks. Between the first and second stages of closure a transitory flow of blood from the aorta to the pulmonary arteries may occur in man, pig, lamb, calf, and foal, and causes an audible murmur.

The ductus venosus connects the umbilical vein with the inferior (posterior) vena cava, and closes quickly following birth or hatching. In the rat there is no trace of this channel by 5 days after birth. In the horse and the pig the ductus venosus disappears before birth (*28*).

In many mammals the vitelline vessels form prior to the umbilical (allantoic) vessels, but the opposite holds in man. Where a yolk sac placenta as well as an allantoic placenta is present, as in the rat and mouse, the vitelline vessels persist throughout gestation.

In man, the umbilical arteries initially combine to form a single artery in the body stalk (later umbilical cord) but during the fifth week this vessel shortens and the two arteries which joined to form it come to extend the entire length of the cord (*29*). In the rat there is only one umbilical artery in the cord throughout gestation, and of the two umbilical arteries within the fetus, one of these, usually the left, disappears by day 17. A similar pattern is seen in the mouse embryo. In the chick the right umbilical artery begins to disappear about day 8 of incubation.

Of the two umbilical veins initially present in mammalian embryos, the right one usually disappears. In man, this occurs about week 6 and in the rat at day 13. In the chick, the right umbilical vein and the subintestinal vein begin to disappear about day 4. The umbilical cord of the lamb contains two veins (and two arteries) which persist throughout gestation.

In rat, mouse, and probably other rodents, there is a transient communication between the vitelline and umbilical arteries within the embryo until day 11, when it disappears (*30*). Persistence of this channel results in bizarre patterns of the two arteries it connects.

Some of the studies involving rat embryos were supported by USPHS Grant HD 00419.

REFERENCES

1. Altman, P. L., and Dittmer, D. S. Growth. Federation American Society of Experimental Biology, Washington D.C., 1962.
2. Arey, L. B. Developmental Anatomy. Saunders, Philadelphia, 7th ed., 1974.
3. Edwards, J. A. The external development of the rabbit and rat embryo. In: Advances in Teratology, Vol. 3, D. H. Woollam, Ed., Academic Press, New York, 1968.
4. Farris, E. J., and Griffith J. R. The Rat in Laboratory Investigation. Hafner, New York, 2nd ed., 1962.
5. Hamburger, V. and Hamilton, H. L. A series of normal stages in the development of the chick embryo. J. Morphol, 88: 49 (1951).
6. Hamilton, H. L. Lillie's Development of the Chick. Holt, New York, 3rd Ed., 1952.
7. Hamilton, W. J., and Mossman, H. W., Human Embryology. Heffer, Cambridge, 4th ed., 1972.
8. Heuser, C. H., and Streeter, G. L. Development of the macaque embryo. Contrib. Embryol. 29: 15 (1941).
9. McEwen, R. S. Vertebrate Embryology. Holt, New York, 4th ed., 1957.
10. Monie, I. W. Comparative development of rat, chick, and human embryos. In: Teratology Workshop Manual (supplement), Pharmaceutical Manufacturers Association, Berkeley, 1962.
11. Nelsen, O. E. Comparative Embryology of the Vertebrates. McGraw-Hill, New York, 1953.
12. Patten, B. M. Early Embryology of the Chick. McGraw-Hill, New York, 4th ed., 1951.
13. Patten, B. M. Human Embryology. Blakiston, Philadelphia, 3rd ed., 1968.
14. Rugh, R. The Mouse: Its Reproduction and Development. Burgess, Minneapolis, 1968.
15. Shepard, T. Catalog of Teratogenic Agents. Johns Hopkin Univ. Press. Baltimore, 1973.
16. Snell, G. D. The early embryology of the mouse. In: Biology of the Laboratory Mouse. Blakiston, Philadelphia, 1941.
17. Streeter, G. L. Developmental horizons in human embryos (XI-XII). Contrib. Embryol. 30: 211 (1942).
18. Streeter, G. L. Developmental horizons in human embryos (XIII-XIV). Contrib. Embryol. 31: 27 (1945).
19. Streeter, G. L. Developmental horizons in human embryos (XV-XVIII). Contrib. Embryol. 32: 133 (1948).
20. Waterman, A. J. A Laboratory Manual of Comparative Vertebrate Embryology. Holt, New York, 1948.
21. Witschi, E: Development of Vertebrates. Saunders, Philadelphia, 1956.
22. Jacobsen, M. Developmental Neurobiology. Holt, Rinehart, and Winston. New York, 1957.
23. Jílek, L., and Trojan, S. Ontogenesis of the Brain. Univ. Caroline, Prague, 1968.
24. Pattle, R. E. The development of the foetal lung. In: Foetal Autonomy, G. E. W. Wolstenholme and M. O'Connor, Eds., Churchill, London, 1969.
25. Gluck, L. Fetal lung maturity. In: Preventability of Perinatal Injury. K. Adamsons and H. A. Fox, Eds., Liss, New York, 1975.
26. Conen, P. E. and Balis, J. U. Electron microscopy in study of lung development. In: The Anatomy of the Developing Lung. J. Emery, Ed., Heinemann, London, 1969.
27. Heymann, M., and Rudolph, A. M. Control of the ductus arteriosus. Physiol. Rev. 55: 62 (1975).
28. Barclay, A. E., Franklin, K. J., and Prichard, M. M. L. The Foetal Circulation. Thomas, Springfield, 1945.
29. Monie, I. W. The genesis of single umbilical artery. Am. J. Obst. Gynec. 108: 400 (1970)
30. Monie, I. W., and Khemmani, M. Absent and abnormal umbilical arteries. Teratology 7: 135 (1973).