Environmental Health Perspectives
Vol. 1, pp. 61-66, 1976

Comparative Developmental Aspects of Selected Organ Systems. II. Gastrointestinal and Urogenital Systems

by Richard M. Hoar*

A brief description of the basic patterns of mammalian organogenesis of the gastrointestinal and urogenital systems is presented based on events as they occur in human beings. The emphasis is not on the details of this development, but rather on its organization and timing, with tables of comparative development providing a comparison of similar events in man, rat, mouse, and chick.

My responsibility is to present some of the basic patterns of mamalian organogenesis, specifically of the gastrointestinal and urogenital systems. Such a "refresher course" within the allocated time can only sketch the raw outlines of these beautifully complex systems. However, I hope that this presentation will persuade you to pursue the subject further, and that the tables of comparative development will remind you how rapidly these events take place in the rodent species as compared to man.

The Gastrointestinal System

The gastrointestinal system is generally divided into three areas, anterior, middle, and posterior; for the sake of convenience, they will be discussed separately. The anterior gut (Fig. 1) extends from the oral pharyngeal membrane (the stomadeum) to approximately the first half of the duodenum, and its development is best characterized by the word complex. It includes the pharyngeal derivatives, the foregut, and that portion of the duodenum from which the liver, gall bladder, and pancreas develop.

The pharyngeal gut is most easily distinguished by the branchial apparatus with its branchial arches from which develop the visceral skeleton, including the jaws and palate, and the ear ossicles and its branchial pouches and clefts from which develop the external ear, middle ear, Eustachian tube, palatine tonsil, thymus, parathyroid, ultimobranchial body, and thyroid. Nowhere else in the developing embryo are the intricacies of organogenesis more delicately woven or beautifully balanced or easily disturbed. The majority of this maneuvering is accomplished during the third to eighth week of life, although palatine fusion is not complete until about the twelfth week.

The foregut changes its dimensions through differential growth. The esophagus lengthens as the cervical flexure is reduced, the neck forms, and the back straightens during the seventh week. The stomach appears as a dilation of the foregut during the fifth week and rotates 90° around its longitudinal axis during the sixth week, causing its left side to face anteriorly. During this movement the greater curvature develops through more rapid growth of the original

*Research Division, Department of Toxicology, Hoffmann-La Roche Inc., Nutley, New Jersey 07110.

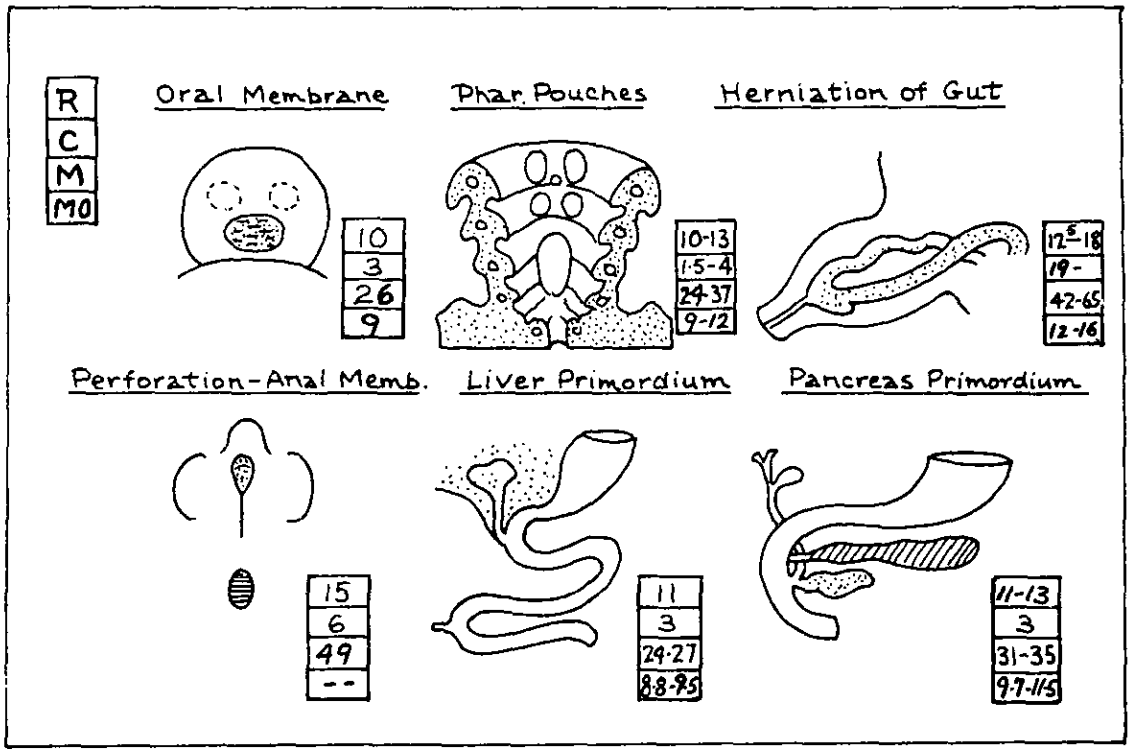

FIGURE 1. Various developmental stages of the digestive system, accompanied by the age in days on which a particular event occurs in the rat (R), mouse (Mo), and man (M) based on fertilization age and in the chick (C) based on incubation age. Modified from Monie (8).

posterior part of the stomach, while the stomach completes its rotation around an anteroposterior axis by the seventh week, causing the greater curvature to face caudally. These movements help to form the omental bursa and force the pylorus with the attached duodenum to the right.

As one might expect, while the stomach and esophagus are undergoing their changes the rest of the gastrointestinal system is being altered also. The liver appears during the third week as a single diverticulum of the duodenum growing into the ventral mesentery. The gall bladder and ventral pancreas bud off the now narrowed liver diverticulum (bile duct) during the fourth week, while the dorsal pancreas appears as a dorsal outgrowth of the duodenum growing into the dorsal mesentery. Identifiable hepatic lobes are present by the sixth week, bile secreted by the twelfth week, and the dorsal and ventral pancreatic buds, aided by both differential growth in the wall of the duodenum and by rotation of the gut, meet and fuse in the dorsal mesentery during the seventh week. Insulin secretion is thought to begin at approximately the fifth month.

The midgut, which extends from the distal half of the duodenum through the proximal two thirds of the transverse colon, is best characterized by its extraordinary elongation and rotation, the latter being in conjunction with an umbilical herniation. The midgut begins its elongation during the fourth to fifth weeks, herniates during the sixth week, and then withdraws from the cord and assumes its normal position during the tenth week. Rotation occurs in a counterclockwise direction around the superior mesenteric artery and amounts to approximately 270° when it is completed, trapping the distal portion of the duodenum between the aorta and the caudal surface of the superior mesenteric artery. When the umbilical hernia is reduced, the ileocaecal junction is located superior to the superior mesenteric artery and just inferior to the liver. The caecum, appendix, and ascending colon develop during the ensuing months, all being recognizable by about six months.

The hindgut, extending from the distal third of the transverse colon to the upper part of the anal canal is intimately associated with those changes which occur in the cloaca. The latter is at its height of development during the fourth week. Between the fifth and seventh weeks a transverse ridge of tissue, the urorectal septum, ap-

pears growing caudally towards the cloacal membrane. When the septum reaches the cloacal membrane its point of contact is later described as the perineal body and the cloaca itself is divided into a urogenital sinus and an anorectal canal covered by a urogenital membrane and an anal membrane.

Urogenital System

The urogenital system, although actually two separate systems, is united both through inductive interactions during development and, especially in the male, through the utilization of a common discharge duct, the penile urethra. However, no matter how intimately interwoven the two systems may be, they must be considered separately for the sake of clarity.

The urinary system (Fig. 2) develops within the intermediate mesodermal ridge which occupies a position lateral to the aorta and anterolateral to the developing vertebral column and its musculature. Three different, overlapping kidney systems develop in rapid succession, appearing in a craniocaudal progression in the intermediate mesodermal ridge between the third and fourth weeks of gestation. The pronephros is transitory and of little importance except in larval anamniotes. The appearance of the mesonephros is characterized by a single Bowman's capsule for each segmentally arranged excretory tubule and a longitudinal collecting duct, the mesonephric duct. The mesonephric duct at first ends blindly just short of the cloaca and then fuses with it at about 26 days. Two days later, the ureteric bud, an outgrowth of the mesonephric duct close to its entrance into the cloaca, penetrates the intermediate mesodermal ridge and induces the metanephros or definitive kidney. The ureteric bud gives rise to the collecting system while the metanephric mesoderm forms the filtering system. These events occur between the seventh and tenth weeks, culminating in functional capacity early in the second half of pregnancy.

As we saw earlier, the urorectal septum separated the primitive urogenital sinus from the anorectal canal, this separation being completed by the seventh week. The primitive urogenital sinus is now modified further into a bladder and

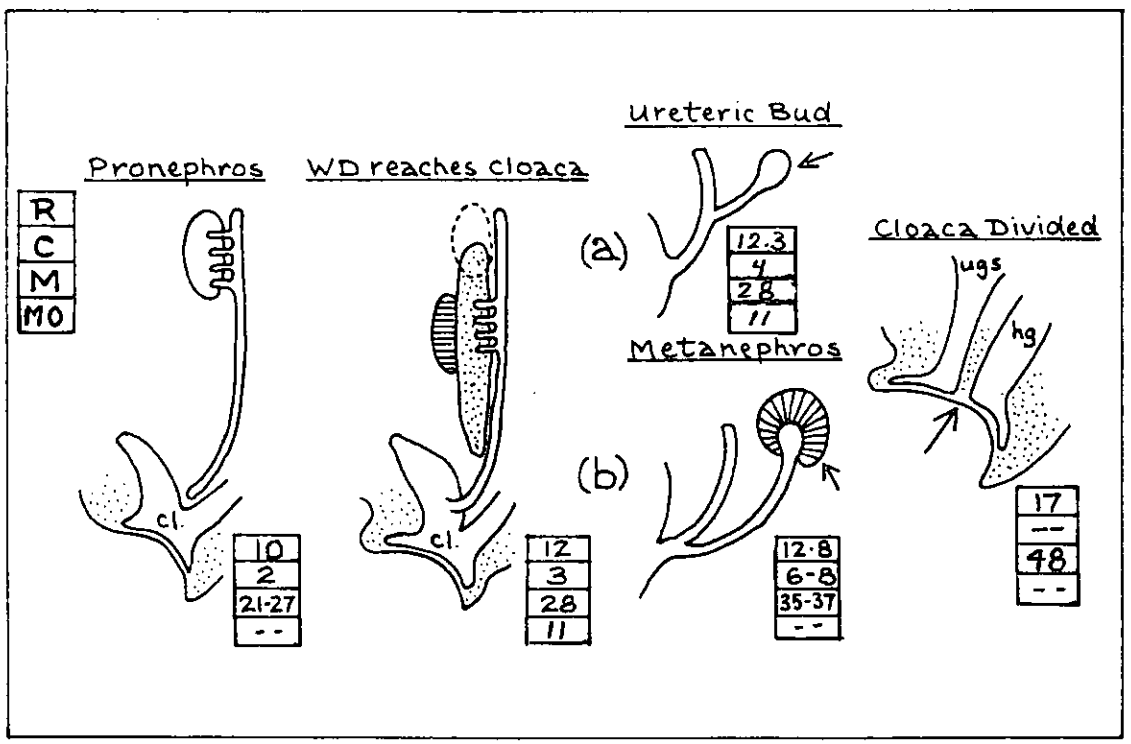

FIGURE 2. Various developmental stages of the urinary system, accompanied by the age in days on which a particular event occurs in the rat (R), mouse (Mo), and man (M) based on fertilization age and in the chick (C) based on incubation age. Modified from Monie (*8*).

two structures, the pelvic part of the urogenital sinus and the definitive urogenital sinus, whose final determination awaits the expression of the sex of the embryo. The bladder wall into which the mesonephric ducts emptied incorporates these ducts until the ureters enter the wall separately while the mesonephric ducts move closer together and inferiorly to enter the pelvic part of the urogenital sinus.

The genital system (Fig. 3) in the human being crystallizes in the sixth week, for it is then that the primordial germ cells complete their migration from the yolk sac into the genital ridge establishing the gonad, and it is also at this time that the establishment of two pairs of genital ducts are completed and the embryo stands in an indifferent bisexual state. The mesonephric duct (Wolffian duct), now in close association with the gonad and emptying into the urogenital sinus, is free to become the main genital duct of the male—the ductus deferens. The paramesonephric duct (Müllerian duct), from which the oviducts and uterus will develop, is also in close approximation to the developing gonad. It begins as an invagination of the coelomic epithelium on the anterolateral surface of the urogenital ridge parallel to the mesonephric duct. Cranially the duct opens into the coelomic cavity (future ostium of the oviduct), caudally it progresses lateral to the mesonephric duct, crosses it ventrally and grows caudomedially to meet the paramesonephric duct from the opposite side at about eight weeks. The two paramesonephric ducts fuse forming the uterine canal which continues to grow caudally until it meets the posterior wall of the urogenital sinus.

Depending upon the sex of the embryo, one of these two duct systems will complete its development and the other will disappear almost completely. In the male the paramesonephric duct (Müllerian duct) disappears, and the mesonephric duct (Wolffian duct) differentiates into its several components: the epididymis, seminal vesicles, and ductus deferens. In the female the mesonephric duct disappears almost completely, and the paramesonephric duct differentiates into the oviduct with its ostium and the corpus and cervix of the uterus.

At about the ninth week of gestation the vagina begins it development from that portion of the urogenital sinus in the region of the fused para-

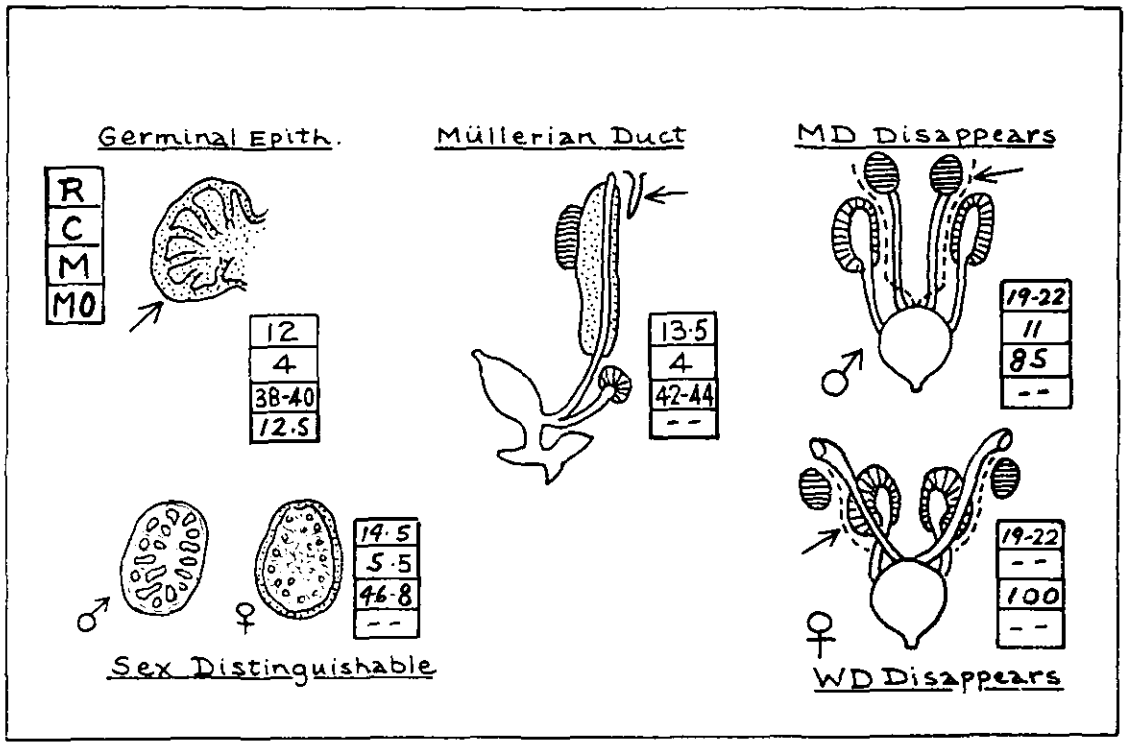

FIGURE 3. Various developmental stages of the reproductive system accompanied by the age in days on which a particular event occurs in the rat (R), mouse (Mo), and man (M) based on fertilization age and in the chick (C) based on incubation age. Modified from Monie (*8*).

Table 1. Comparative gastrointestinal development.

Event	Time, days				Witschi Standard Stages	Streeter's Horizons
	Man	Rat	Mouse	Chick		
Foregut pocket	20.5	9.5	7.8	1.1	13	IX
Hindgut pocket	21.5	11	8.5	3	15	XI
Pharyngeal pouches appear	24	10	8.8	1.5	15	XI
Oral membrane perforates	26	10	9	3	15	XI
Liver anlage	24	11	8.8	2.5	16	XI
Liver with epithelial cords	26		9.5		16	XII
Gallbladder	26		9.7	3.5	17	XII
Pancreas, ventral	31-32	11	9.7	3	17	XIII
Pancreas, dorsal	26	11		4	17	XII
Pancreas, fused	35	13	11.5		27	XVI
Trachea separates from esophagus	29	12.5	11		25	XIV
Stomach appears	31-32	11.5	11.5	3	18	XI-XII
Anal membrane perforates	49	15		6	31	XVIII
Umbilical hernia begins	45	12.5	12.3		27	XVII
Umbilical hernia reduced	65	18	16.3		34	XXIII

Table 2. Comparative urogenital development.

Event	Time, days				Witschi Standard Stages	Streeter's Horizons
	Man	Rat	Mouse	Chick		
Allantois appears	16.5		7			
Pronephros appears	22	10			14	X
Mesonephros appears	24	11.5	9.5	3	16	XI
Mesonephric duct enters urogenital sinus	28	12	11		22	XII
Urorectal septum appearing	28-48	12.5-17			18-33	XII-XVIII
Ureteric bud appears	28	12.3	11	4	23	XIII
Ureteric bud with metanephric "cap"	32	12.5			25	XIV
Metanephros	35-37	12.8		6	26	XV
Germinal epithelium	38-40	12	12.5	4	19	XII
Testis histologically differentiated	46-48	13.5		5.5	28	XVII
Paramesonephric duct appears	42-44	13.5		4	28	XVII
Paramesonephric duct reaches cloaca	49-56	15.5			32	XVIII
Degeneration of paramesonephric duct in male	85	19-22		11	35	XXIII
Degeneration of mesonephric duct in female	100	19-22			35	XXIII
Indifferent swellings of external genitalia	37	19			35	XVIII
Urethral groove closed	84	22			35	XVIII

Table 3. Developmental stages.

Stage	Witschi Standard Stages	Streeter's Horizons
Cleavage and blastula	1-7	I-III
Gastrula	8-11	IV-VII
Primitive streak	12	VIII
Neurula	13-17	IX-XII
Tailbud embryo	18-24	XII-XIII
Complete embryo	25	XIV
Metomorphosing embryo	26-33	XV-XXII
Fetus	34-36	XXIII

mesonephric ducts. By the fifth month the vaginal outgrowth is canalized but remains separated from the urogenital sinus by the hymen.

All that remains to complete the description of the urogenital system is the development of the external genitalia. The cloacal orifice, closed by a membrane, is originally surrounded by elevated cloacal folds which are continuous posteriorly and end in a genital tubercle anteriorly. Genital swellings appear lateral to the urethral folds and by the end of the sixth week the external genitalia of

the male and female are essentially identical. The cloacal folds are divided during the seventh week by the urorectal septum into anal and urethral folds. In the female the genital tubercle enlarges slightly to become the clitoris, the urethral folds do not fuse, becoming the labia minora while the genital swellings enlarge to become the labia majora. The definitive urogenital sinus is modified slightly to form the urethra and the vestibule. In the male the genital tubercle elongates into a phallus drawing the urethral folds into a long urethral groove which fuses forming the penile portion of the urethra by the end of the third month. The pelvic part of the urogenital sinus becomes the prostatic and membranous urethra. The genital swellings enlarge, moving caudally and fusing to form the scrotum. These scrotal swellings are prepared for the descending testes during the third month, but the testes do not complete their descent into the scrotum until between the seventh month of development and birth.

All that remains to be discussed are the tables of development. These include the age in days on which a particular event occurs in the organogenesis of man, rat and mouse based on fertilization age and in the chick according to its incubation age. In many cases these figures are approximations included to create a clearer picture of the time involved during organogenesis and they are not intended to be the "final word."

Because vertebrates have such widely variant periods of development, it is often easier to compare them on the basis of developmental stages which attempt to eliminate all the variables such as length of gestation, growth rate, etc. Witschi developed such a series of 36 standard stages *(1)* and Streeter's Horizons *(2)* are known to all of us. Both of these staging procedures have been included in the developmental tables (Tables 1 and 2 as well and are broadly organized as seen in Table 3.

Some general references *(1-9)*, not intended to be exhaustive by any means, which should aid in a study of comparative mammalian embryology, are appended.

REFERENCES

1. Witschi, E. Development of Vertebrates, W. B. Saunders, Philadelphia and London, 1956.
2. Streeter, G. L. Developmental horizons in human embryos. Contrib. Embryol. 30: 211 (1942); ibid., 31: 27 (1945); ibid., 32: 133 (1948).
3. O'Rahilly, R., and Muecke, E. C. The timing and sequence of events in the development of the human urinary system during the embryonic period proper. Z. Anat. Entwickl.-Gesch. 139: 99 (1972)
4. Otis, E. M., and Brent, R. Equivalent ages in mouse and human embryos. Anat. Rec. 120: 33 (1954).
5. Arey, L. B. Developmental Anatomy. W. B. Saunders, Philadelphia and London, 7th ed., 1974.
6. Altman, P. L., and Dittmer, D. S. Growth Including Reproduction and Morphological Development. American Society for Experimental Biology, Washington, 1962.
7. Langman, J. Medical Embryology. Williams and Wilkins Baltimore, 3rd ed., 1974.
8. Monie, I. E. Comparative development of rat, chick and human embryos. In: Teratologic Workshop Manual (Supplement), Berkeley, California, Pharmacertical Manufacturers Assoc., 1965, p. 146.
9. Shepard, T. H. Catalogue of Teratogenic Agents, Johns Hopkins Univ. Press, Baltimore and London, 1973.