Environmental Health Perspectives
Vol. 21, pp. 247–249, 1977

Pulmonary Edema Due to Tetrachloroethylene

by Ramesh Patel,*† Natesan Janakiraman,‡ and William D. Towne*

A patient with massive exposure to tetrachloroethylene fumes presented with coma and severe pulmonary edema. Sequential blood gases, chest x-rays, and clinical findings showed dramatic improvement with conventional but aggressive management and the patient recovered completely. There was no evidence of permanent renal, hepatic, or central nervous system damage.

Introduction

Tetrachloroethylene (perchlorethylene or "perc") is used widely in the dry cleaning industry as a cleansing agent (*1*). It is also used as an antihelmenthic (*2*). The compound is highly soluble in fat. Toxic exposure to the compound causes mucous membrane, liver, kidney and central nervous system damage. The last leads to coma and death. The development of pulmonary edema from trichloroethylene and other related compounds has been previously described (*3*), but this is the first report of pulmonary edema resulting from exposure to tetrachloroethylene.

Report of a Case

A 21-year old male was found unconscious in a laundry and admitted to Cook County Hospital. On admission to the hospital he was cyanotic, dyspneic and appeared to be in shock. The pulse rate was 88 per minute; blood pressure 80/20 mm Hg; temperature 34.4°C (94°F); respirations 48 per minute. He was deeply comatose and had a peculiar odor to his breath. Frothy material was noted to be issuing from his mouth. Pupils reacted sluggishly to light. The conjunctival, corneal, and gag reflexes were absent. No evidence of trauma could be observed. Examination of the heart was normal. Bubbling rales were auscultated over both entire lung fields and air entry was diminished bilaterally. Abdominal and rectal examinations were normal. There were no abnormalities on lumbar puncture.

After immediate endotracheal intubation and suction, the patient was placed on mechanical ventilatory support with frequent monitoring of arterial blood gases (Table 1). Gastric aspiration was performed and the material obtained was sent for toxicologic studies along with urine and blood samples, which were reported as normal the next day. The patient remained very ill with no clue available as to the etiology of pulmonary edema which was the principal clinical feature. Isoproterenol, 0.8 mg in 1 liter of 5% dextrose, was infused intravenously to maintain systemic arterial pressure after the central venous pressure was determined to be 14 cm of H_2O. A 40-mg bolus of furosemide as well as 250 mg of aminophylline and 10 mg of dexamethasone were administered intravenously. The urinary output averaged about 300 ml/hr on forced diuresis. Six hours after admission, the patient's level of consciousness and pulmonary status showed improvement.

Radiographs of the chest taken at the time of admission and subsequently are shown in Figures 1–3. The patient's serum electrolytes, liver function tests, and renal function were normal on admission.

*Division of Adult Cardiology, Cook County Hospital, Chicago, Illinois.
†Department of Medicine, Loyola Stritch School of Medicine, Maywood, Illinois.
‡Pediatrics Intensive Care Unit, Cook County Hospital and Assistant Professor, Department of Pediatrics, University of Health Sciences, Chicago Medical School, Chicago, Illinois.

Table 1. Blood gases.

Time	Treatment	pH	PO_2	PCO_2
12:10 PM	On admission; room air	7.19	26	60
	After suction; room air	7.23	50	50
12:45 PM	After intubation, 5 l.O_2	7.32	40	30
3:00 PM	On Bennett respirator, 50% FIO_2	7.395	44	31.5
6:15 PM	On Emerson, 50% FIO_2	7.48	120	26
7:00 PM	On T piece, 70% FIO_2	7.40	70	30
2:00 AM	On T piece, 70% FIO_2	7.40	86	30

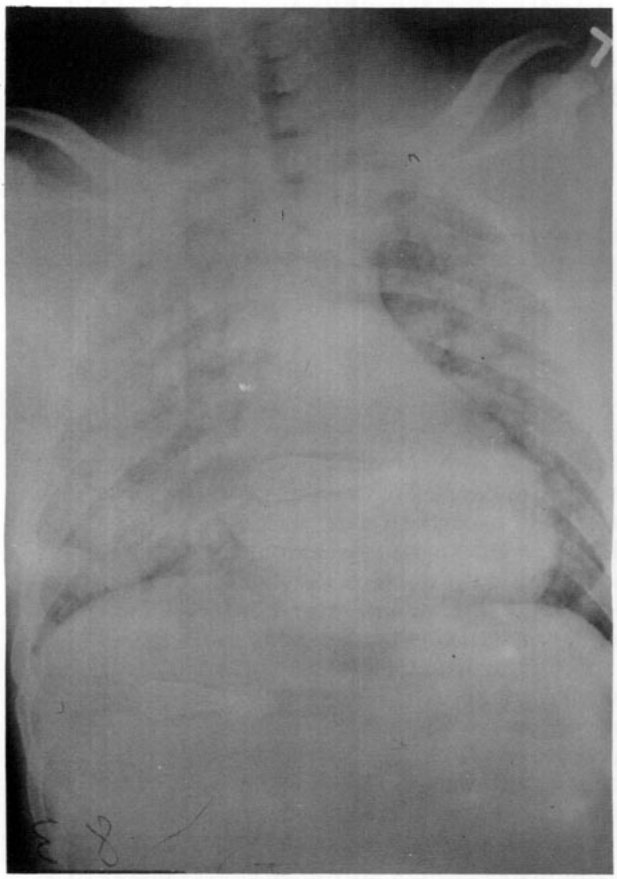

FIGURE 1. Portable chest x-ray taken on admission showing bilateral diffuse, fluffy pulmonary infiltrates consistent with pulmonary edema.

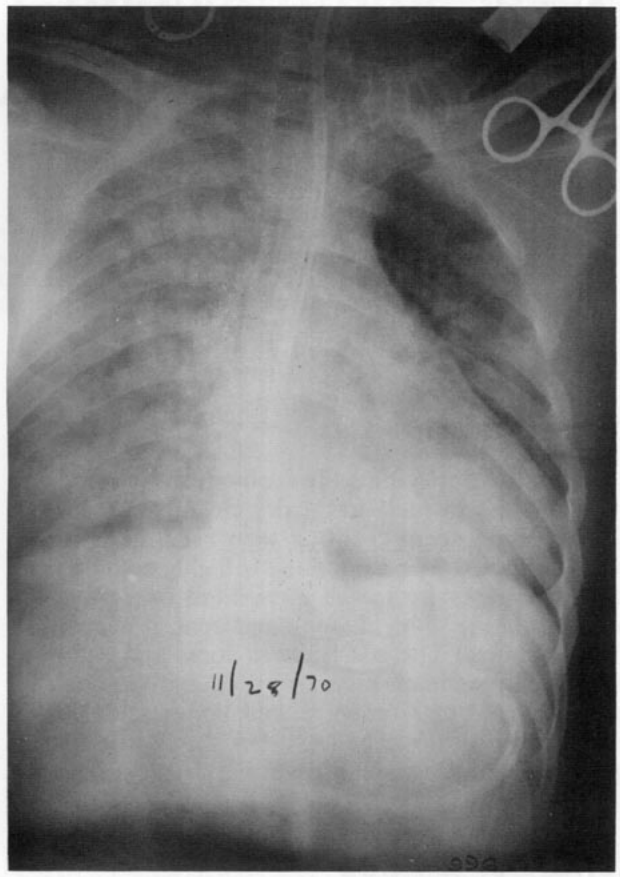

FIGURE 2. Portable chest x-ray taken after 8 hr of hospitalization showing clearing of pulmonary edema.

Four hours after admission it was learned that the patient had been exposed to the vapors of tetrachloroethylene. The patient gradually recovered completely and was discharged four days after admission without any residual abnormality. His liver function tests remained normal throughout his hospital stay and on repeat testing several weeks after discharge.

Discussion

Tetrachloroethylene is the principal solvent of the dry cleaning industry. Its use in garment cleaning has steadily increased during the past three decades. Exposure to the vapors of tetrachloroethylene is capable of providing an anesthetic effect if excessive amounts are inhaled. Overexposure to tetrachloroethylene causes depression of the central nervous system, the severity of which depends upon the duration of exposure (*4*). In two reports, the response in human beings seems to resemble that of trichloroethylene poisoning, i.e., headache, fatigue, nausea, vomiting, mental confusion and temporary blurring of vision (*5*, *6*). Minor organic injury to the liver and kidneys and possibly to the heart has also been reported. Exposure to the fumes

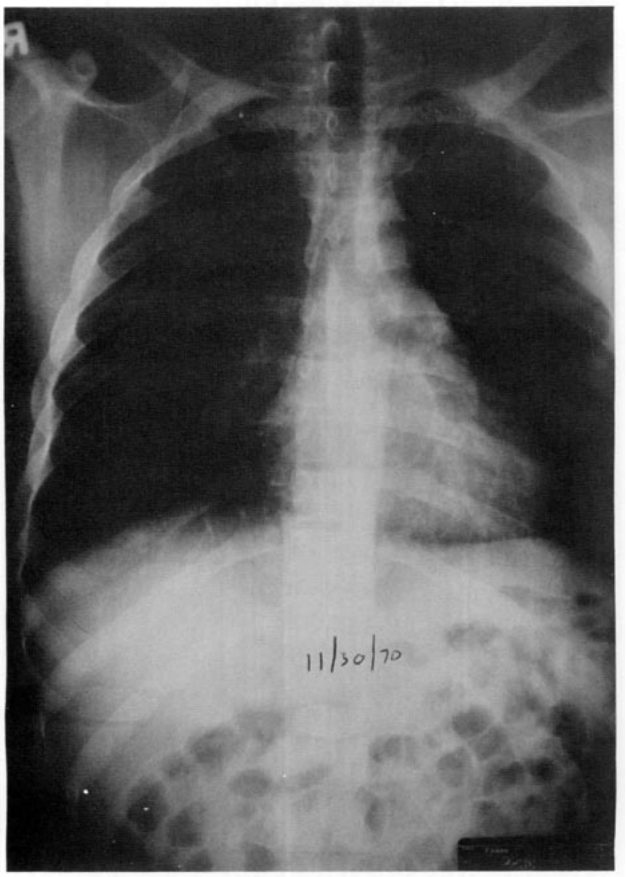

FIGURE 3. X-ray of chest taken 48 hr after admission. Posterior anterior view showing complete resolution and normal heart size.

of tetrachloroethylene results in irritation to the skin and mucous membranes as well. Pulmonary edema and coma may also occur (*3*).

Tetrachloroethylene and other halogenated hydrocarbons are highly soluble in fat. Their effects could be due to direct contact of the original compound or the breakdown products. Tetrachloroethylene is a clear liquid at normal temperature with a molecular weight of 165.83, specific gravity of 1.63, vapor density of 5.8, and no flash or fire point.

More than 200 million pounds of tetrachloroethylene are used yearly in this country. Because of precautionary measures, the incidence of toxicity is small. If concentrations of tetrachloroethylene vapor in air remain below 200 ppm with an average concentration of less than 100 ppm over a 40-hr work week, there will usually be no health hazard. The patient under discussion had probably been exposed to more than 1500 ppm over a sufficient length of time to make him initially dizzy and soon unconscious (*1*). While he lay on the floor continuing to inhale the toxic vapor of tetrachloroethylene, which is 5.8 times heavier than air, hypoxia probably supervened. Hypoxia and/or the direct toxic effects of the breakdown products of tetrachloroethylene like phosgene, carbon tetrachloride, and hydrochloric acid may have caused pulmonary edema (*7*).

The mechanism of pulmonary edema is uncertain but it would appear to have been noncardiac. Since left heart filling pressures were never determined, left ventricular failure remains a possibility. However, there were certainly no clinical signs of cardiac dysfunction at any time in the patient's course.

The more likely pulmonary mechanism may have been related to the direct and/or indirect capillary permeability effects of tetrachloroethylene or its breakdown products.

This report emphasizes the need for strict adherence to the occupational safety acts by private industry in order to prevent such fatal or near fatal accidents.

We gratefully acknowledge the invaluable secretarial assistance of Ms. Suzanne Adams in preparation of this manuscript.

REFERENCES

1. Laundry and Cleaners Allied Trades Association. The Safe Handling of Perchlorethylene-Drycleaning Solvent. New Jersey, p. 1-9.
2. Johnson, S. A Comparative study of bitoscanate, bephenium hydroxynaphthoate and tetrachloroethylene in hookworm infection. Prog. Drug Res. 19: 70 (1975).
3. Harrison, T. R. Principles of Internal Medicine, 6th Ed., McGraw Hill, New York, 1970, p. 656.
4. Stewart, R. D., et al. Accidental vapor exposure to anesthetic concentrations of a solvent containing tetrachloroethylene. Ind. Med. Surg. 30: 8 327 (1961).
5. Stewart, R. D., et al. Human exposure to tetrachloroethylene vapor. Arch. Environ. Health 2: 40 (1961).
6. Rowe, V. K., et al. Vapor toxicity of tetrachloroethylene for laboratory animals and human subjects. Ind. Hyg. Occup. Med. 5: 566 (1952).
7. Robin, E. D., et al. Pulmonary Edema. N. Engl. J. Med. 288: 239 (1973).