Environmental Health Perspectives
Vol. 57, pp. 207-217, 1984

Testicular Toxicity Produced by Ethylene Glycol Monomethyl and Monoethyl Ethers in the Rat

by Paul M. D. Foster,*† Dianne M. Creasy,* John R. Foster*† and Tim J. B. Gray*

Ethylene glycol monomethyl ether (EGME) and ethylene glycol monoethyl ether (EGEE) were administered orally to young male rats at doses varying from 50 to 500 mg/kg/day and 250 to 1000 mg/kg/day for EGME and EGEE, respectively, for 11 days. At sequential times animals were killed and testicular histology examined. The initial and major site of damage following EGME treatment was restricted to the primary spermatocytes undergoing postzygotene meiotic maturation and division. EGEE produced damage of an identical nature, but a larger dose was required to elicit equivalent severity (500 mg EGEE/kg being approximately equivalent to 100 mg EGME/kg). Additionally, within the spermatocyte population, differential sensitivity was observed depending on the precise stage of meiotic maturation: dividing (stage XIV) and early pachytene (stages I–II) > late pachytene (stages VIII–XIII) > mid-pachytene (stages III–VII). Equivalent doses of methoxyacetic acid (MAA) and ethoxyacetic acid (EAA) gave injury similar to the corresponding glycol ether.

When animals were pretreated with inhibitors of alcohol metabolism followed by a testicular toxic dose of EGME (500 mg/kg), an inhibitor of alcohol dehydrogenase (pyrazole) offered complete protection. Pretreatment with the aldehyde dehydrogenase inhibitors disulfiram or pargyline did not ameliorate the testicular toxicity of EGME. In mixed cultures of Sertoli-germ cells, MAA and not EGME produced effects on spermatocytes analogous to that seen *in vivo*, at concentrations approximately equivalent to steady-state plasma levels after a single oral dose of EGME (500 mg/kg). It would seem likely that a metabolite (MAA or possibly methoxyacetaldehyde) and not EGME is responsible for the production of testicular damage.

Introduction

The ability of ethylene glycol mono-*n*-alkyl ethers to produce testicular damage has been known for some time. Wiley et al. (*1*) first demonstrated the testicular effects of ethylene glycol monomethyl ether (EGME) in rabbits in 1938. Stenger et al. (*2*) have shown that the monoethyl derivative (EGEE) can also induce testicular damage in dogs and rats. More recently, Nagano and others (*3*), using a variety of ethylene glycol monoalkyl ethers in studies with orally treated mice, have shown EGME, ethylene glycol monomethyl ether acetate (EGMEA) and EGEE to be the most potent of the series examined in producing adverse testicular effects. EGME has also been shown to produce a decrease in testicular weight in the rat and mouse following inhalation exposure for 2 weeks at 1000 ppm (*4*).

*The British Industrial Biological Research Association, Woodmansterne Road, Carshalton, Surrey SM5 4DS, UK.
†Present address: Imperial Chemical Industries PLC, Central Toxicology Laboratory, Alderley Park, Macclesfield, Cheshire SK10 4TJ, UK.

The objectives of the studies detailed here were, first, to establish the dose-response relationship between testicular damage and oral ingestion of either EGME or EGEE; second, to observe the temporal development of the testicular lesion and deduce the target cell type involved, and, third, to ascertain whether the parent compounds and/or metabolites were responsible for the observed testicular damage.

Methods

Dose-Response, Time-Course Study

Animals were randomly assigned to nine treatment groups containing 36 animals per group. Groups 2 to 5 received EGME by oral gavage at dose levels of 50, 100, 250 or 500 mg/kg/day. Groups 7 to 9 were administered EGEE by the same route at levels of 250, 500 or 1000 mg/kg/day. Groups 1 and 6 were given an equivalent volume of the water vehicle (5 mL/kg/day) and served as control groups for EGME and EGEE, respectively.

Six animals from each group were killed, by cervical dislocation, 6 and 24 hr after a single dose. Further groups received repeated daily doses and were killed after 2, 4, 7 and 11 days. At postmortem, the testes, seminal vesicles, prostate and liver were excised and weighed and testes, epididymides and liver fixed for examination by light or electron microscopy (see below).

Recovery Study

Groups of animals received 500 mg EGME/kg/day by oral gavage for 4 days, control animals receiving an equivalent volume of water vehicle. After cessation of treatment, animals (six per group) were killed from both the treated and control groups at 0, 2, 4 or 8 weeks. Tissues taken for examination were as described above.

Histology

In most experiments, one testis, the epididymides and a sample of liver were fixed in Bouin's fluid for light microscopy. The other testis and a sample of liver were diced and fixed in 4% formaldehyde plus 1% glutaraldehyde in 0.1 M phosphate buffer, pH 7.29 (*5*). In the recovery study, both testes and epididymides were fixed in Bouin's fluid.

For examination by light microscopy, tissues were fixed for 24 hr and processed into paraffin wax. Sections were stained with hematoxylin and eosin and with periodic acid-Schiff technique for the demonstration of the spermatid acrosome (*6*). Definition of the stages of spermatogenesis was based on that used by Leblond and Clermont (*7*).

For examination by transmission electron microscopy, the tissue was stored in fixative at 4°C and processed only if selected by prior examination of the sample taken for light microscopy. Samples were post-fixed in 1% osmium tetroxide, dehydrated in graded ethanols and embedded in Epon/Araldite; 90 mm sections were cut and stained with uranyl acetate and lead hydroxide.

Metabolism and Tissue Distribution of a Single Oral Dose of [^{14}C] EGME

Twelve rats were treated with [^{14}C]methoxy-labeled EGME (500 mg/kg; 25 μCi/kg), dissolved in water by oral intubation. Urine, feces and expired air were monitored for [^{14}C] content over a 48 hr period. Animals were killed after 24 and 48 hr (six animals per time) and tissue radioactivity estimated by sample oxidation by using a Packard Model 306 oxidizer.

Analysis of Urinary Metabolites

Metabolites were analyzed by using a Varian Vista LC 5040 HPLC, fitted with a 300 mm × 5 mm internal diameter column containing Varian Micropak MCH-10 ODS and a 50 mm × 4.6 mm internal diameter column packed with CO:PELL:ODS. Samples (approximately 20,000 dpm) were applied to the column and eluted at 2 mL/min with a linear methanol:water:1% aqueous sulfuric acid gradient. The effluent was monitored by UV absorbence at 200 nm and by liquid scintillation counting of collected 0.3 min fractions. Peaks were compared with those of known unlabeled standards.

Aliquots of collected feces were homogenized in water and homogenate examined for total [^{14}C] by sample oxidation. Samples were also filtered and examined by the HPLC method described above. Expired air from the metabolism chambers was passed through saturated barium hydroxide solution and a water trap for collection of [^{14}C]CO_2 as precipitated carbonate. Following filtration of the barium hydroxide solution, the filtrate was examined for metabolites by HPLC and radioactivity present in the precipitate by sample oxidation, followed by liquid scintillation counting.

Experiments with 2-Methoxy- and 2-Ethoxyacetic Acids *in Vivo*

After suitable doses and periods of exposure had been established for the parent glycol ethers, further groups of animals were treated with the corresponding acetic acids. One group received MAA for 4 days (equimolar to 500 mg/kg/day EGME) and a second EAA 11 days (equimolar to 500 mg/kg/day EGEE), controls received an equivalent volume of water (5 mg/kg/day). Upon sacrifice tissues taken were as described above.

Experiments with Inhibitors of Alcohol Metabolism

In each experiment 24 rats were randomly assigned to four groups. Groups 2 and 4 were treated with inhibitor and groups 1 and 3 received an equal volume of the appropriate control vehicle. One hour later, groups 3 and 4 received EGME (500 mg/kg) by oral intubation and groups 1 and 2 an equivalent volume of water (5 mL/kg). Pyrazole was administered IP at a dose level of 400 mg/kg dissolved in water, disulfiram IP at 100 mg/kg in corn oil and pargyline IP 100 mg/kg in water. These concentrations were known to be effective in inhibiting hepatic alcohol (pyrazole) and aldehyde (disulfiram and pargyline) dehydrogenases.

Animals were killed by cervical dislocation 24 hr after the last dose and the testes and epididymides excised, weighed and fixed in Bouin's fluid. Transverse sections of paraffin wax-embedded material were prepared and stained with hematoxylin and eosin for assessment of testicular damage by light microscopy.

In Vitro Effects of EGME and MAA

Mixed cultures of Sertoli and germ cells from testes of 4-week-old rats were prepared by a modification of the method of Steinberger et al. (*8*) described in detail

elsewhere (*9*). Testes were decapsulated, coarsely chopped and dissociated into individual tubules by incubation with 0.25% (w/v) trypsin. After washing in Hank's balanced salt solution, they were further incubated with 0.1% (w/v) collagenase until the tissue was reduced to small aggregates of Sertoli and germ cells. These were then cultured in 50 mm dishes containing glass coverslips. The culture medium comprised Eagle's minimal essential medium with 10% (v/v) fetal calf serum with the addition of 4 mM L-glutamine, 0.1 mM nonessential amino acids, 100 U/mL penicillin and 100 μg/mL streptomycin. After 24 hr incubation in a humidified atmosphere of 5% CO_2:95% air, the culture medium was replaced with serum-free medium containing appropriate concentrations of EGME (0-50 mM) or MAA (0-10 mM). Coverslips were removed at intervals and cells fixed in Bouin's fluid and stained with hematoxylin and eosin. The culture medium was replaced with appropriately treated medium every 24 hr.

Results

Dose-Response, Time-Course Study

The first significant decrease in relative testicular weight in the EGME group was evident at day 2 after 500 mg/kg/day (Fig. 1). Thereafter, decreases in relative testis weight became more pronounced with increasing dose and were statistically significant in the 250 mg/kg/day group by 7 days. The liver showed decreased relative weight differing from control values in the 100, 250 and 500 mg/EGME/kg groups after 24 hr. Liver

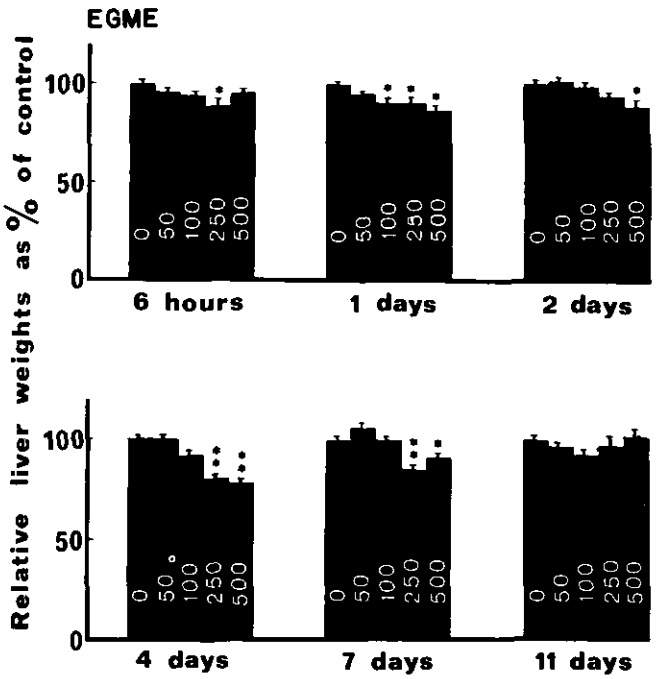

FIGURE 2. Effect of period of EGME exposure on relative liver weight. Numbers in columns refer to dose level (mg/kg/day). Significance: $*p < 0.05$; $**p < 0.01$ compared to corresponding control (Dunnett's test). Vertical bars indicate SE.

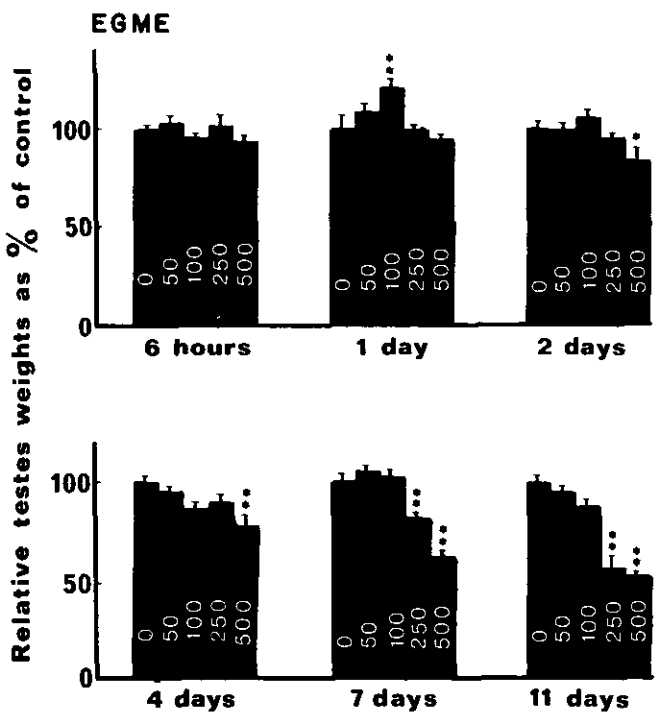

FIGURE 1. Effect of period of EGME exposure on relative testis weight. Numbers in columns refer to dose level (mg/kg/day). Significance: $*p < 0.05$; $**p < 0.01$ compared to corresponding control (Dunnett's test). Vertical bars indicate SE.

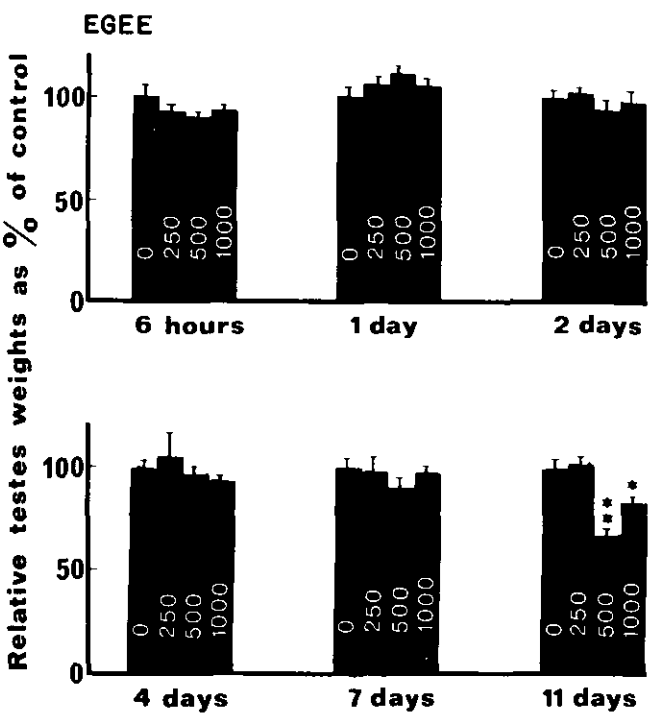

FIGURE 3. Effect of period of EGEE exposure on relative testis weight. Numbers in columns refer to dose level (mg/kg/day). Significance: $*p < 0.05$; $**p < 0.01$ compared to corresponding control (Dunnett's test). Vertical bars indicate SE.

weights also differed in the 250 and 500 mg/kg/day groups on days 4 and 7 but returned to control levels by day 11 (Fig. 2).

No evidence of a significant decrease in relative testis weight was obtained until day 11 in the animals treated with EGEE when decreases were recorded in the 500 and 1000 mg/kg/day groups (Fig. 3). Isolated occurrences of statistically significant differences in relative liver weight were also noted (data not shown). In general, the 500 mg/kg/day group showed greater changes in relative organ weight than the 1000mg/kg/day group.

Recovery Study

Treatment with EGME for 4 days at a dose level of 500 mg/kg/day resulted in marked decreases in liver and testis relative weights (as described above). On allowing the animals to recover after treatment (Table 1), liver weights had returned to normal at the first time point (2 weeks). Testes weights, however, did not return to control values until 8 weeks after cessation of treatment.

Histology

EGME Treatment. Dosing with 50 mg/kg/day produced no testicular abnormalities, but 100, 250 and 500 mg/kg/day resulted in degeneration of pachytene spermatocytes evident 24 hr after a single dose. The proportion of the spermatocyte population affected was directly related to dose. Continued dosing resulted in progressive depletion of spermatocytes and in a maturation depletion of the early spermatid population. Degenerative changes consisted of general cellular shrinkage, increased cytoplasmic eosinophilia and nuclear pyknosis. These changes were restricted to the secondary spermatocytes and to pachytene, diplotene, diakinetic and dividing stages of primary spermatocyte development; the preleptotene, leptotene and zygotene spermatocytes remained unaffected except at the highest dose level. These effects on spermatocyte maturation and division appeared stage-dependent. The most sensitive cells being spermatocytes undergoing division or in early pachytene (stages XIV and I–II, respectively), spermatocytes in late pachytene (stages X–XIII) less so and those in mid-pachytene (stages III–IX) being least sensitive (Figs. 4–6).

After 11 days of dosing with 250 and 500 mg/kg/day, spermatid and late spermatocyte populations were absent. Zygotene spermatocytes showed a marked increase in number indicating maturation arrest. At all dose levels and times the spermatogonia, pre-leptotene spermatocytes, Leydig and Sertoli cells appeared normal.

Ultrastructural examination of testes 24 hr after a single dose showed a proportion of the spermatocyte population in advanced stages of necrosis. An earlier time point (16 hr) was required to show early signs of degeneration; these were again restricted to spermatocytes, the most prominent of the changes was found to be mitochondrial swelling and disruption (Fig. 7), cytoplasmic vacuolation and early condensation of nuclear chromatin. The cytology of the other germ cells and of the Leydig and Sertoli cells appeared normal.

EGME Recovery. The group of animals killed at zero time recovery, i.e., after four daily doses of 500 mg/kg, showed the same distribution and extent of damage as found in the equivalent time kill in the dose-response study described above. Two weeks after cessation of treatment, maturation depletion had progressed to involve all middle and late stage spermatids. Occasional tubules contained newly formed Golgi-phase spermatids, but most contained either early or late pachytene spermatocytes as the most mature cell present. In control animals (of equivalent age) spermatozoal production had begun, evidenced by the presence of sperm in the epididymides. At 4 weeks, recovery had progressed and maturation phase spermatids were frequently seen. By 8 weeks full spermatogenesis was present in the majority of tubules from all animals and all showed epididymal spermatozoa, although quantitatively less than in the age-equivalent controls. Most animals also contained a proportion (<10%) of tubules which appeared totally atrophic, composed only of Sertoli cells.

EGEE Treatment. Dosing of animals with 500 or 1000 mg/kg/day produced spermatocyte degeneration of a severity similar to that seen with EGME administered at 100 mg/kg/day. Although the degree of spermatocyte

Table 1. Relative organ weights of male rats exposed to EGME and allowed to recover from treatment for 2, 4 and 8 weeks.

	Relative organ wt, g/100 g body weight[a]			
	0	Recovery 2 weeks	Recovery 4 weeks	Recovery 8 weeks
Testes				
Control[b]	0.985 ± 0.028	0.473 ± 0.017	0.448 ± 0.010	0.690 ± 0.038
EGME	0.752 ± 0.031*	0.221 ± 0.011*	0.255 ± 0.019*	0.643 ± 0.037
Liver				
Control	4.821 ± 0.115	4.800 ± 0.156	4.368 ± 0.171	3.675 ± 0.095
EGME	3.850 ± 0.061*	4.760 ± 0.067	4.062 ± 0.084	3.651 ± 0.069

[a]Values are means ± SE for six animals.
[b]Animals received 500 mg/kg/day EGME for 4 days and were then allowed to recover. Controls received an equivalent volume of the water vehicle (5 mL/kg/day).
*Significant at $p < 0.001$, compared to corresponding control (Student's t-test).

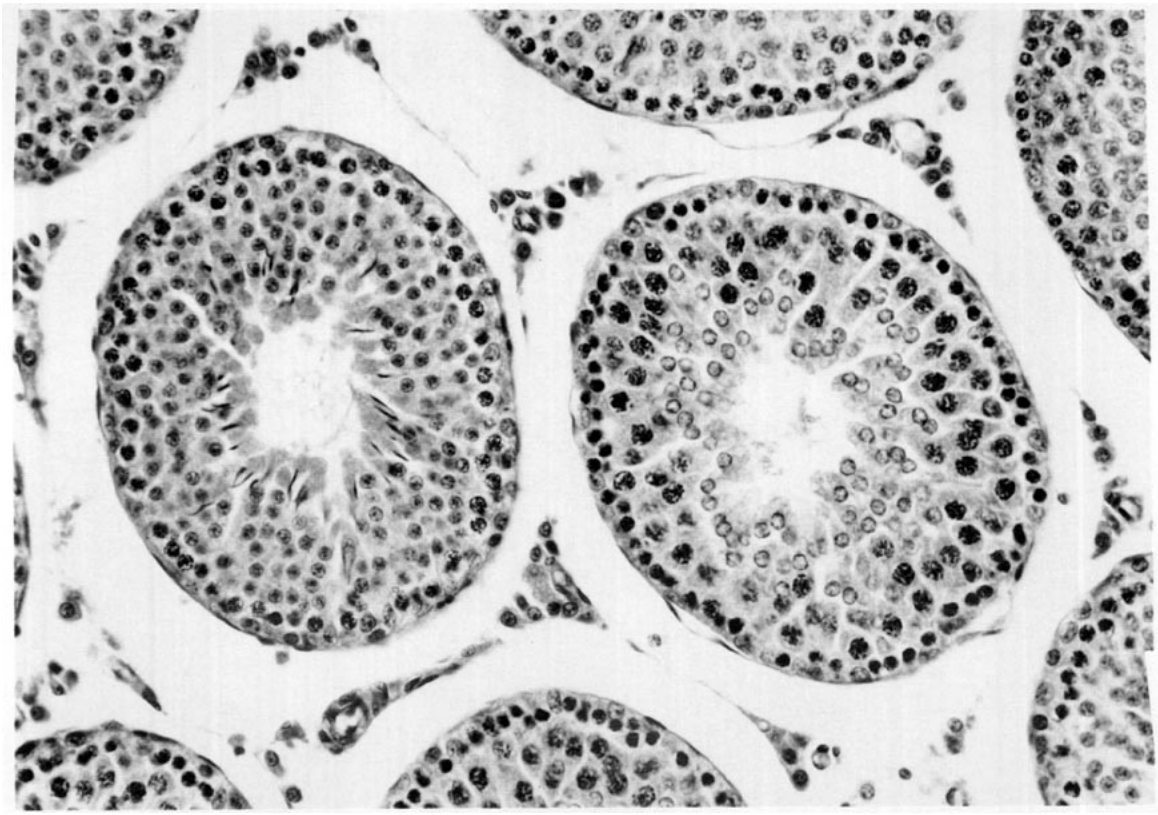

FIGURE 4. Seminiferous tubules from control rat. Tubule in early stage of spermatogenesis (I–III) on the left and in mid-stage (VIII–IX) on the right. Hematoxylin and eosin; ×290.

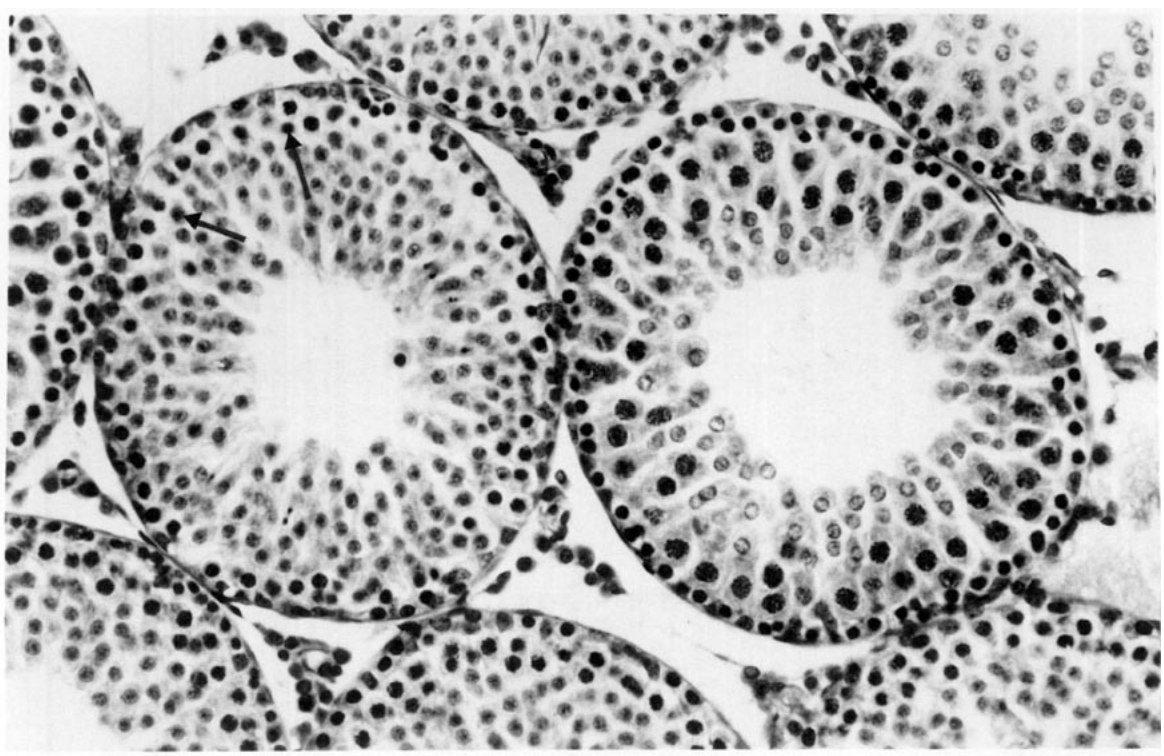

FIGURE 5. Seminiferous tubules from rat treated 24 hr previously with 250 mg EGME/kg. Stage and orientation of tubules as in Fig. 4. Note the early pachytene spermatocyte population shows nuclear pyknosis (arrowed) whereas mid-pachytene spermatocytes are unaffected. Hematoxylin and eosin; ×290.

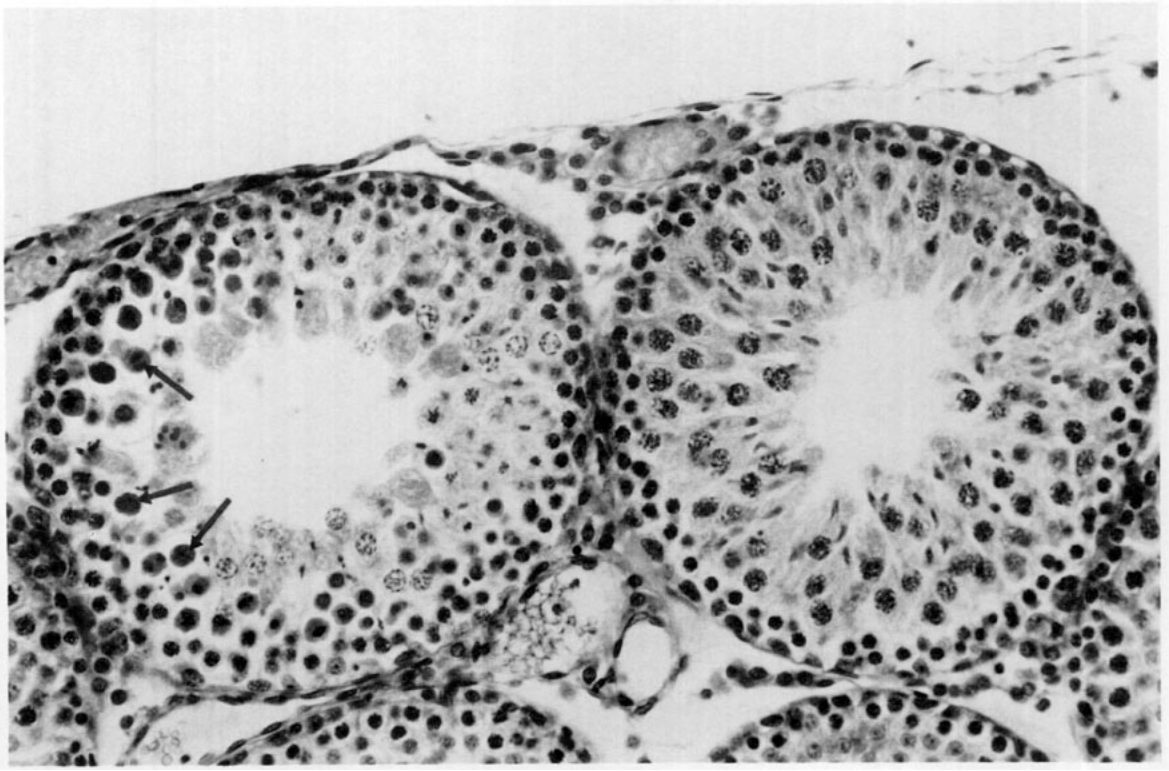

FIGURE 6. Seminiferous tubules from rat treated 24 hr previously with 250 mg EGME/kg. Tubules are in stage XIV (left) and stage XI (right) of spermatogenesis. Many dividing spermatocytes show nuclear pyknosis and cytoplasmic eosinophilia (arrowed), while late pachytene spermatocytes in the stage XI tubule are unaffected. Hematoxylin and eosin; ×290.

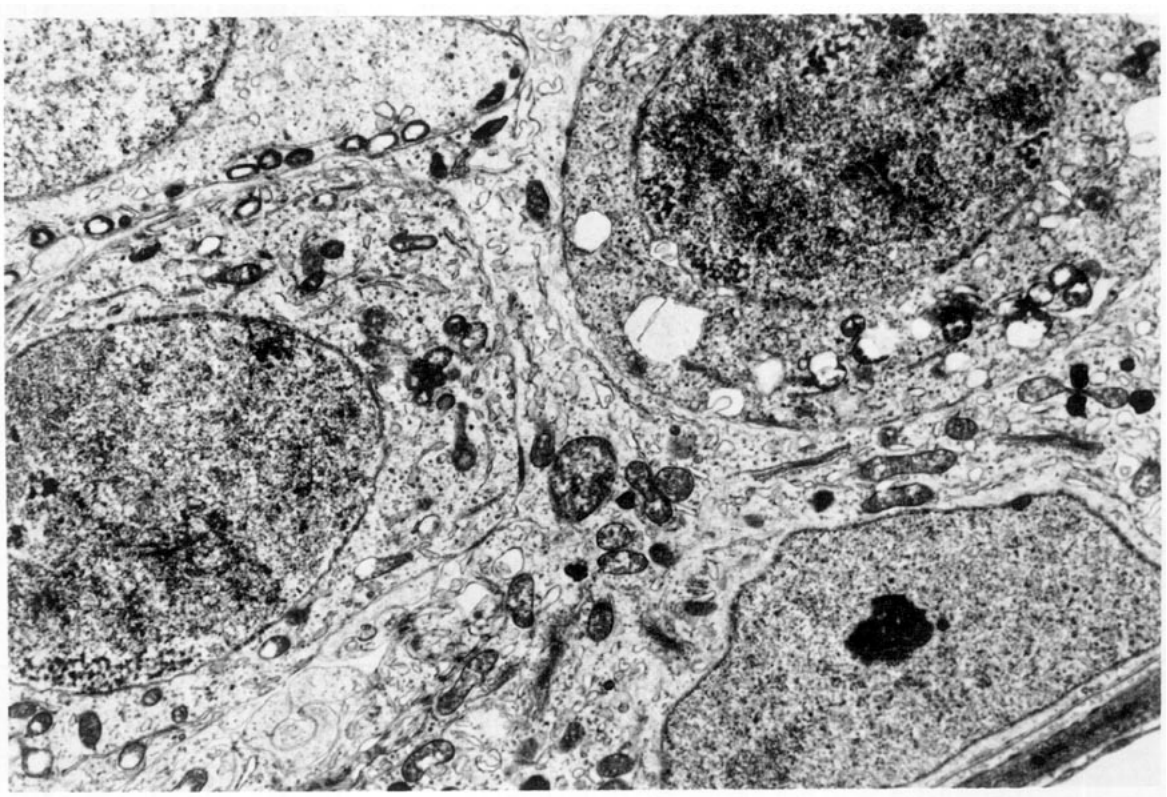

FIGURE 7. Electron micrograph of a seminiferous tubule from a rat treated 16 hr previously with 500 mg EGME/kg. Note cytoplasmic vacuolation and mitochondrial disruption in the spermatocyte surrounded by a Sertoli cell of normal appearance. ×5850.

degeneration was broadly similar for both of the above treatment groups after 11 days of treatment the onset of degeneration was more pronounced with the lower dose level. The target cell types were found to be as described for EGME. Sertoli and Leydig cells, spermatogonia, prepachytene spermatocytes and spermatids were unaffected apart from partial maturation depletion of early stage spermatids.

Liver Histology. None of the compounds examined produced any histological or ultrastructural abnormalities at any dosage.

Tissue Distribution and Urinary Metabolites Following a Single Oral Dose of [^{14}C]EGME

The distribution of radioactivity in urine, feces, exhaled air and tissues is described in Table 2. Within 24 hr, approximately 60% of the dose was recovered in urine, with a further 11% in the 24 to 48 hr period. Feces contained 1% of the dose in the first 24 hr, predominantly as the parent compound. Likewise, radioactivity recovered in expired air was also in the form of EGME. There was no testis-specific uptake or accumulation of radioactivity (approximately 0.15% of dose in 24 hr), label being detected in all the tissues selected for examination. The urinary metabolic profile for EGME is shown in Figure 8. The major metabolite found in urine was MAA (73.1%); EGME (14.8%) was also detected together with a third peak (8.1%) that did not chromatograph with any of the standards used.

Table 2. Distribution of [^{14}C]EGME after a single oral dose.[a]

	Time after dose, hr.	% of administered dose[b]
Urine	0 – 24[c]	58.5 ± 2.3
Feces		1.0 ± 0.2
Exhaled		2.3 ± 0.3
Urine	24–48[d]	11.5 ± 0.8
Feces		0.5 ± 0.1
Exhaled		0.4 ± 0.2
Tissues		12.5 ± 0.9
Total		86.7 (range 81.7–94.5)

[a]Animals received a single oral dose of [^{14}C]EGME (500 mg/kg, 25 μCi/kg) dissolved in water.
[b]Values are means ± SE.
[c]n = 12.
[d]n = 6.

Table 3. Effect of 2-methoxyacetic acid (MAA) on the relative organ weights of testes and liver.[a]

	Relative organ weight, g/100 g body weight[b]	
Tissue	Control	MAA
Testes	0.985 ± 0.028	0.773 ± 0.022*
Liver	4.821 ± 0.115	4.237 ± 0.104†

[a]Animals received MAA by oral gavage at a dose level of 592 mg/kg/day for 4 days or an equivalent volume of water (5 mL/kg/day).
[b]Values are means ± SE for six animals.
*$p < 0.001$ compared to control (Student's t-test).
†$p < 0.01$ compared to control (Student's t-test).

In Vivo Effects of MAA and EAA

Animals treated with 2-methoxyacetic acid exhibited similar changes in relative testis and liver weight as obtained with the corresponding glycol ether given at an equivalent dose for the same period (Table 3). The

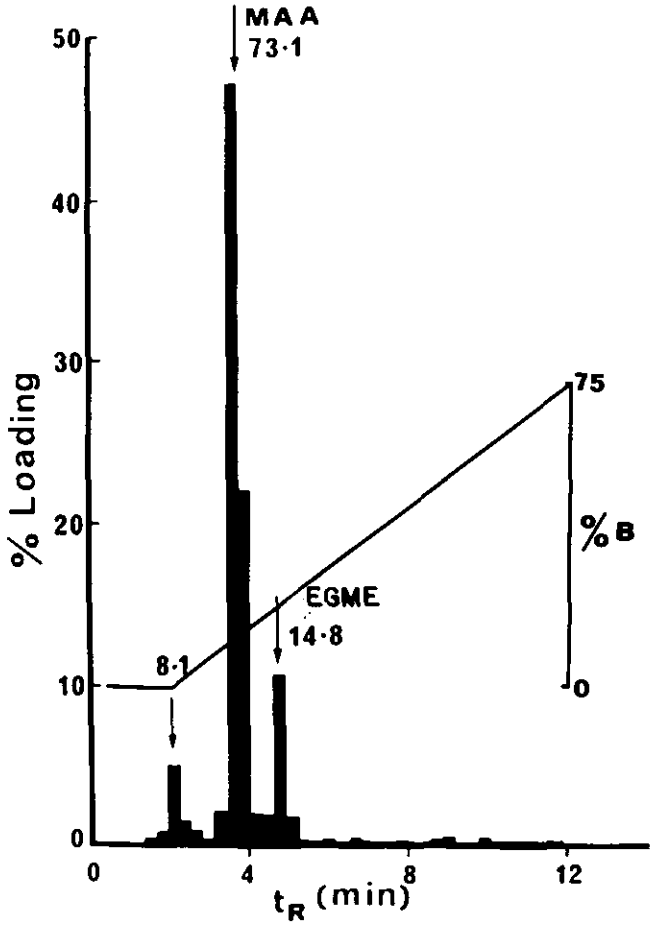

FIGURE 8. Typical HPLC separation of radiolabelled metabolites of [^{14}C]EGME. A 30μL portion of urine (containing approximately 20,000 dpm) was injected into the column and eluted (2 mL/min) with a ternary solvent system comprising (solvent A) water; (solvent B) methanol; (solvent C) 1% v/v aqueous sulfuric acid (held at 7% throughout). Figures represent the percent loading recovered in the peaks indicated; t_R = retention time.

Table 4. Effect of aldehyde and alcohol dehydrogenase inhibitors on the testicular toxicity of EGME and MAA.[a]

Agent	Testicular damage[b]
EGME	+ + +
MAA	+ + +
EGME + pyrazole (400 mg/kg IP)	NAD
EGME + disulfiram (100 mg/kg IP)	+ + +
MAA + disulfiram (100 mg/kg IP)	+ + +
MAA + pargyline (100 mg/kg IP)	+ + +

[a]Inhibitors were given 1 hr prior to treatment with either EGME (500 mg/kg PO) or an equimolar dose of MAA (592 mg/kg PO).
[b]Testicular score (evaluated 24 hr after last dose): NAD = no abnormality detected; + + + = spermatocytes in majority (> 75%) of tubules exhibiting degeneration.

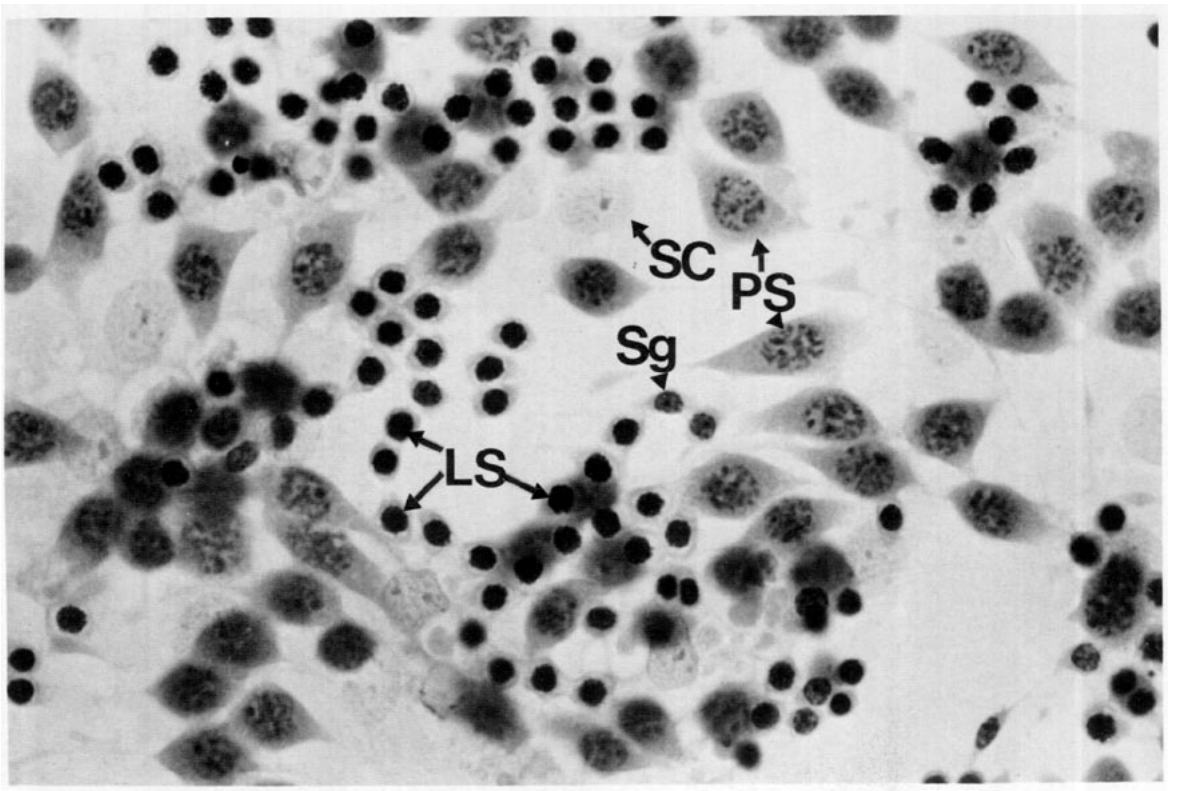

(a)

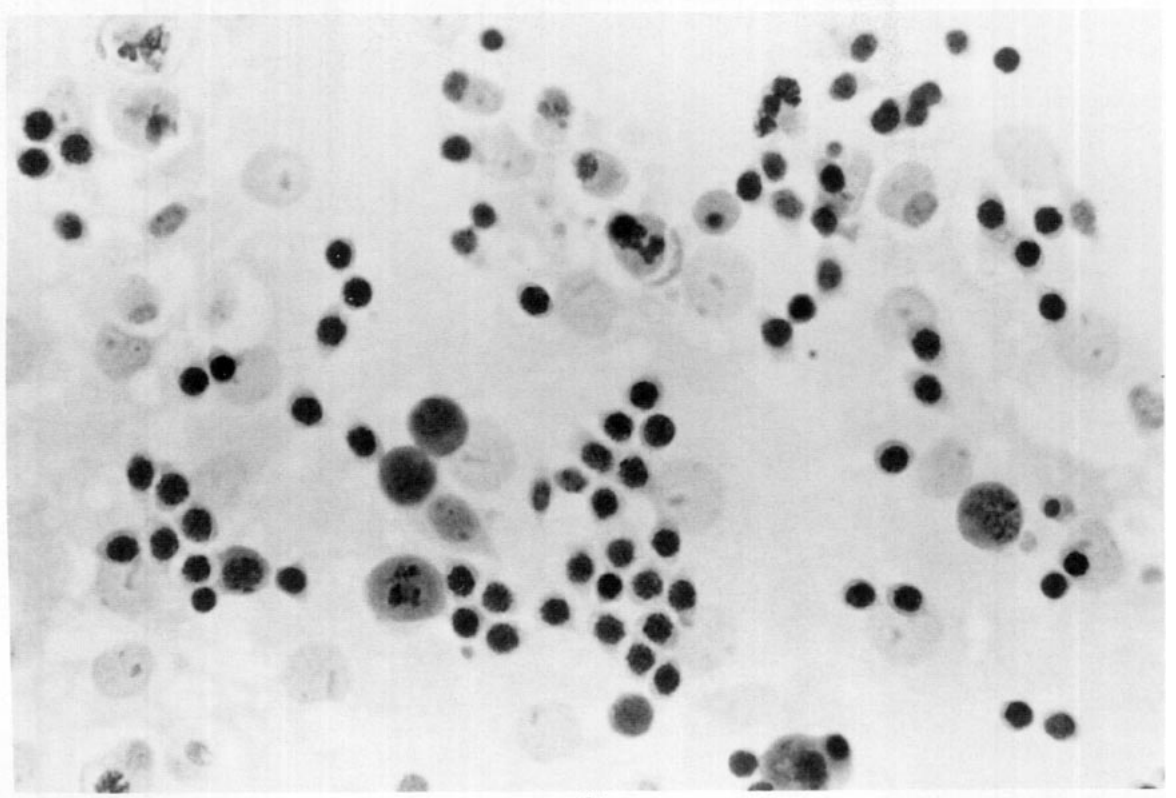

(b)

(b)

FIGURE 9. Sertoli germ cell culture 24 hr after exposure to (a) control medium or (b) 5 mM MAA. Note loss of pachytene spermatocytes (PS). SC refers to Sertoli cells, Sg = spermatogonia, LS = leptotene/zygotene spermatocytes. Hematoxylin and eosin; ×528.

severity and nature of the testicular lesion was essentially similar to that obtained for EGME. Animals treated with EAA for 11 days showed a similar pattern of spermatocyte degeneration and depletion to that of the corresponding glycol ether.

Effects of Metabolic Inhibitors

Pyrazole, an inhibitor of alcohol dehydrogenase was the only inhibitor used which exhibited protective effects against EGME toxicity (Table 4). Inhibition of aldehyde dehydrogenase activity by disulfiram pretreatment had no effect on the degree of testicular damage obtained with EGME, but a similar result was also obtained when MAA was used in conjunction with disulfiram or a further aldehyde dehydrogenase inhibitor (pargyline). None of the treatments produced any significant changes in testis weight, and none of the inhibitors produced any change in testis histology when used alone.

In Vitro Effects of EGME and MAA

Treatment of Sertoli-germ cell cultures at doses up to 50 mM EGME produced no adverse effects. However, MAA treatment produced dose-related changes consisting of initial degeneration and subsequent loss from the culture of the spermatocyte populations. At a concentration of 5 mM these effects were largely restricted to the pachytene spermatocytes (Fig. 9), but at 10 mM earlier stages were also affected.

Discussion

Following oral administration of EGME, a rapid decrease in testis weight associated with testicular cell damage was observed. The degree of degeneration was related to both the dose administered and the period of exposure to the compound.

Within 24 hr of a single dose, damage was observed in the postzygotene spermatocyte population. The severity of this was stage-dependent, with early pachytene and dividing spermatocytes being most sensitive and mid-pachytene least. Prolonged dosing resulted in continued spermatocyte degeneration as well as maturation depletion of the spermatid population, leaving tubules containing only Sertoli cells, spermatogonia and preleptotene spermatocytes. Although zygotene spermatocytes showed slight degeneration with prolonged exposure to high doses, maturation arrest was evident by the increased numbers of cells present. Arrest of spermatocytes at this stage indicated a failure of the cells to accomplish successful transition from zygotene to pachytene. At the ultrastructural level the mitochondria of the spermatocytes showed early evidence of disruption.

Cessation of treatment indicated that the testicular lesion was reversible in the large majority of tubules. Testis weights returned to control values and the majority of tubules regained full spermatogenesis and spermatozoal production within one full spermatogenic maturation cycle (7–8 weeks in the rat). The presence of a small proportion of totally atrophic tubules indicated a loss of spermatogonia, although spermatagonia, when present, appeared morphologically normal, suggesting that they may not be totally resistant at the highest doses and that prolonged treatment might prevent total recovery.

Animals treated with EGEE showed a similar type of damage to that described for EGME, although higher doses were required to produce damage of equivalent severity. Differences in testicular weight and the delayed onset of degeneration and depletion seen after 1000 mg/kg/day compared to 500 mg/kg/day would suggest saturation of some metabolic process or degree of absorption.

The present results indicate that a single oral dose of EGME is predominantly excreted in the urine (approximately 70% in the first 48 hr) in the form of MAA, with no specific uptake or accumulation of radioactivity in the testis. The data obtained were similar to those recently presented by Miller et al. (*10*), although we could show no evidence of $^{14}CO_2$ evolution, only parent compound being detected in expired air. This was almost certainly due to the employment of [^{14}C]methoxy-labeled EGME in our study, the ether bond being more resistant to metabolic attack and therefore not resulting in the excretion of [^{14}C]CO_2. EGEE has also been shown to be metabolized to its corresponding acetic acid derivative and in addition *N*-ethyoxyacetylglycine (*11*). It is possible that the unknown peak obtained in our HPLC analysis of urine from EGME-treated animals is a glycine conjugate of methoxyacetic acid. Further chemical analysis is being carried out to confirm this hypothesis.

In vivo experiments with both MAA and EAA confirmed the decrease in testis weight reported by Miller et al. (*12*) for MAA and additionally showed identical testicular lesions for the metabolites as were encountered with the parent glycol ethers. Experiments with metabolic inhibitors showed that alcohol dehydrogenase is an important activating step in the production of EGME testicular toxicity. Inhibition of this enzyme with pyrazole (*13*) resulted in complete protection. Our experiments have also shown reasonable activity of alcohol dehydrogenase in the testis compared to liver using EGME as substrate (data not shown).

The lack of protection exhibited in EGME-dosed animals pretreated with the aldehyde dehydrogenase inhibitor–disulfiram (*14*) would suggest that methoxyacetaldehyde may be a toxic species (Fig. 10), aliphatic aldehydes being known to possess profound effects on cell division (*15*). The possibility existed that the adverse testicular effects produced by MAA were due to its conversion by aldehyde dehydrogenase to methoxy-

acetaldehyde. However, treatment with either disulfiram or pargylene, an alternative aldehyde dehydrogenase inhibitor (*16*), prior to dosing with MAA showed no protective effects on testicular damage. Alternative possible explanations for MAA activity are that methoxyacetaldehyde is converted to MAA by an enzyme other than aldehyde dehydrogenase (aldehyde oxidase for example) or that concentrations of inhibitor were insufficient to produce inhibition of activity in the testis and experiments are in progress to test these hypotheses.

Results from the testicular cell culture experiments would suggest that EGME *per se* is not responsible for testicular damage. MAA at concentrations approximately equivalent to steady-state plasma levels following 500 mg EGME/kg PO produced analogous effects to that seen *in vivo* by depleting spermatocyte numbers.

Previous studies have shown that EGME can produce marked effects on the bone marrow and hemopoietic systems (*3,4*). Miller et al. (*4*) have also demonstrated the lack of effect of EGME on intestinal epithelium and follicular cells of the ovary, ruling out cell turnover rates as a factor in the target organ specificity of EGME.

The results presented above have shown that EGME and the other compounds studied affect primarily the meiotic cells of the testis while cells undergoing mitotic division appear spared, lending support to the notion that the testicular and bone marrow effects consequent to EGME treatment occur via different mechanisms. In addition MAA, methoxyacetaldehyde or possibly some further testicular metabolites are the likely toxic species responsible for testicular damage produced by EGME. The precise biochemical lesion affecting meiosis in the spermatocytes awaits identification.

This work forms part of a research project sponsored by the U.K. Ministry of Agriculture, Fisheries and Food, to whom our thanks are due. The results of the research are the property of the Ministry of Agriculture, Fisheries and Food and are Crown copyright. The expert technical assistance of Miss L. V. Thomas and Mr. M. W. Cook is gratefully acknowledged.

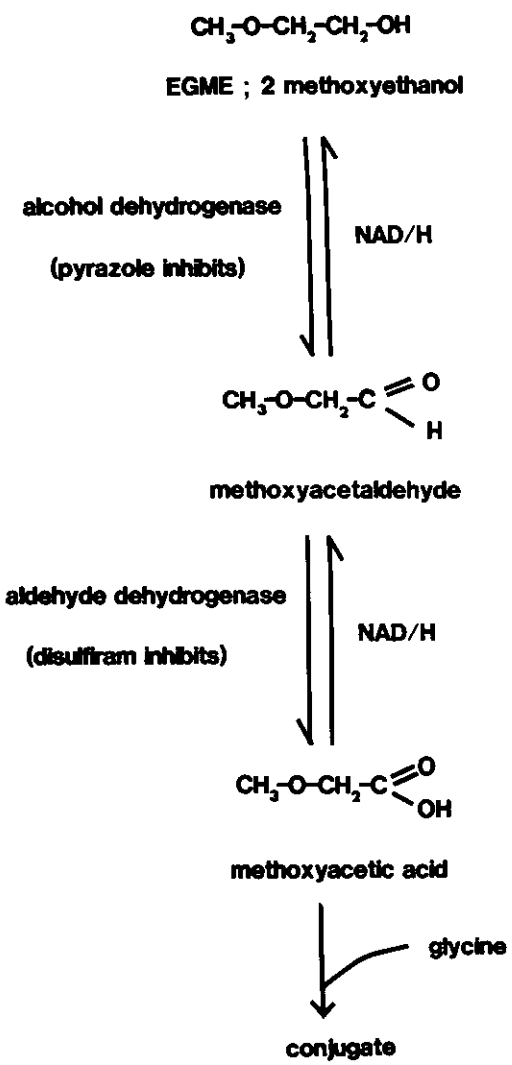

FIGURE 10. Metabolism of EGME in the rat.

REFERENCES

1. Wiley, F. M., Hueper, W. C., Bergen, D. S., and Blood, F. R. The formation of oxalic acid from ethylene glycol and related solvents. J. Ind. Hyg. Toxicol. 20: 269–277 (1938).
2. Stenger, E. G., Aeppli, L., Miller, D., Peheim, E., and Thomann, P. Zur Toxikologie des Aethyleneglykol-monoathylathers. Arzneim. -Forsch. 21: 880–885 (1971).
3. Nagano, K., Nakayama, E., Koyano, M., Oobayashi, M., Adachi, M., and Yamada, T. Testicular atrophy of mice induced by ethylene glycol monoalkyl ethers. Japan. J. Ind. Health 21: 29–35 (1979).
4. Miller, R. R., Ayres, J. A., Calhoun, L. L., Young, J. T., and McKenna, M. J. Comparative short-term inhalation toxicity of ethylene glycol monomethyl ether and propylene glycol monomethyl ether in rats and mice. Toxicol. Appl. Pharmacol. 61: 368–377 (1981).
5. McDowell, E. M., and Trump, B. F. Histologic fixatives suitable for diagnostic light and electron microscopy. Arch. Pathol. Lab. Med. 100: 405–414 (1976).
6. Leblond, C. P., and Clermont, Y. Spermiogenesis of rat, mouse, hamster and guinea pig as revealed by the "periodic acid-fuchsin sulphurous acid" technique. Am. J. Anat. 90: 167–216 (1952).
7. Leblond, C. P., and Clermont, Y. Definition of the stages of the cycle of the seminiferous epithelium in the rat. Ann. N. Y. Acad. Sci. 55: 548–573 (1952).
8. Steinberger, A., Heindel, J. J., Lindsey, J. N., Elkington, J. S. H., Sanborn, B. M., and Steinberger, E. Isolation and culture of FSH responsive Sertoli cells. Endocrine Res. Comm. 2: 261–272 (1975).
9. Gray, T. J. B., and Beamand, J. A. Effect of some phthalate esters and other testicular toxins on primary cultures of testicular cells. Food Chem. Toxicol. 22: 123–131 (1984).
10. Miller, R. R., Hermann, E. A., Langvardt, P. W., McKenna, M. J., and Schwetz, B. A. Comparative metabolism and disposition of ethylene glycol monomethyl ether and propylene glycol monomethyl ether in male rats. Toxicol. Appl. Pharmacol. 67: 229–237 (1978).
11. Jonsson, A. K., Pedersen, J., and Steen, G. Ethoxyacetic acid and *N*-ethoxyacetylglycine: metabolites of ethoxyethanol (ethyl cellosolve) in rats. Acta Pharmacol. Toxicol. 50: 358–362 (1982).
12. Miller, R. R., Carreon, R. E., Young, J. T., and McKenna, M. J. Toxicity of methoxyacetic acid in rats. Fund. Appl. Toxicol. 2: 158–160 (1982).
13. Thonell, M., and Yonetani, T. On the effects of some heterocyclic

compounds on the enzymic activity of liver alcohol dehydrogenase. Acta. Chem. Scand. 23: 255–260 (1969).
14. Marchiner, H., and Tottmar, O. A comparative study on the effects of disulfiram, cyanamide and 1-aminocyclopropanol on the acetaldehyde metabolism in rats. Acta. Pharmacol. Toxicol. 43: 219–232 (1978).
15. Schauenstein, E., Esterbauer, H., and Zollner, H. Aldehydes in Biological Systems. Pion Ltd., London, 1977.
16. Cederbaum, A. I., and Dicker, E. The effect of pargyline on the metabolism of ethanol and acetaldehyde but isolated rat liver cells. Arch. Biochem. Biophys. 193: 551–559 (1979).