Environmental Health Perspectives
Vol. 72, pp. 63-69, 1987

Two-Hour Methyl Isocyanate Inhalation and 90-Day Recovery Study in B6C3F1 Mice

by Gary A. Boorman,* Linda C. Uraih,* Bhola N. Gupta,* and John R. Bucher*

B6C3F1 mice were exposed by inhalation to 0, 3, 10, and 30 ppm methyl isocyanate for 2 hr followed by a 90-day recovery period. Sixteen of eighty (20%) male mice in the 30 ppm group died following exposure. There were no other unscheduled deaths in the mice. Five mice/sex/group were examined at 2 hr or at 1, 3, 7, 14, 28, 49, or 91 days following exposure. Chemical-related changes were restricted to the respiratory system. At 30 ppm there were extensive necrosis and erosion of the respiratory and olfactory epithelium in the nasal cavity. Severe necrosis and epithelial erosion were also found in the trachea and main bronchi. Regeneration of the mucosal epithelium occurred rapidly in the nasal cavity and airways. In the turbinates, mild incomplete olfactory epithelial regeneration persisted to day 91 in the male mice. Intraluminal fibrotic projections covered by respiratory epithelium and bronchial fibrosis were found in the major airways of the 30 ppm male and female mice by day 7. The intraluminal fibrosis persisted to day 91. In males with severe bronchial fibrosis, chronic alveolitis and atelectasis were found. In mice exposed to 3 or 10 ppm, persistent pulmonary changes were not found. These studies indicate that methyl isocyanate inhalation at or near lethal concentrations can cause persistent fibrosis of the major bronchi in mice.

Introduction

It has been necessary to assess more completely the toxicity of methyl isocyanate (MIC) since the toxic gas was accidentally released from an agricultural plant in Bhopal, India (*1,2*). Since thousands were exposed to sublethal concentrations of this gas, the World Health Organization requested that the National Toxicology Program (NTP) perform studies to examine the long-term health effects of exposure to methyl isocyanate. This manuscript reports the lesions found up to 91 days following a 2-hr exposure to MIC in mice.

Materials and Methods

Animals

Male and female B6C3F1 mice (4–6 weeks old) were obtained from Charles River (Kingston, NY) and quarantined for 10 to 21 days prior to exposure. Animals were randomized to exposure groups according to body weight, and were housed five per cage, except during the 2-hr exposure, when they were housed ten per cage. The male and female mice weighed about 24 g and 18 g, respectively, at the time of exposure. Rodent chow (Autoclaved NIH-3, Zeigler Bros., Gardners, PA) and water were available *ad libitum* except during the exposure period. More details on animal husbandry are provided by Bucher et al. (*3*) in this issue.

Exposure Procedures

The complete details of exposure procedures and health and safety aspects are covered separately in this issue (*4*). Exposures were conducted on 3/27/85 and 4/22/85.

Necropsy Procedures

Five animals per sex and group were necropsied 2 hr or 1, 3, 7, 14, 28, 49, or 91 days following exposure. Complete necropsies were performed under a pathologist's supervision. All tissues were fixed in 10% buffered formalin except for selected nasal turbinates of male mice that were fixed in Fowler's fixative as part of an ultrastructural study (*5*). The tissues that were examined routinely included three levels of nasal turbinate (*6*), trachea at the level of the thyroid and at the bifurcation, four lobes of the lung to include major airways, liver, gall bladder, thyroid, parathyroid, esophagus, peribronchial lymph node, brain, kidneys, eye (sectioned to include lids, conjunctiva, and optic nerve), thymus, spleen, heart, and glandular and nonglandular stomach. All lesions noted grossly were also examined. Complete pathologic review was performed on mice killed on days 7 and 91 (*7*). After the tissues were fixed in 10% buffered formalin, they were embedded in par-

*Chemical Pathology Branch and Carcinogenesis and Toxicity Evaluation Branch, National Toxicology Program, National Institute of Environmental Health Sciences, Research Triangle Park, NC 27709.

Table 1. Incidence of nasal cavity lesions in male mice.[a]

Morphological diagnosis	MIC dose, ppm	No. of nasal cavity lesions at various days after exposure							
		0	1	3	7	14	28	49	91
Acute inflammation	0								
	3	1	3		1				
	10	1	3	2	3	1			
	30	1	3	3	3	3		2	1
Respiratory epithelial necrosis	0								
	3		4						
	10	5	3						
	30	5							
Respiratory epithelial erosion	0								
	3	1	4						
	10	5	3						
	30	5	3	3	1				
Olfactory epithelial necrosis	0								
	2								
	10	2	5						
	30	3	3						
Olfactory epithelial erosion	0								
	3								
	10		3	1					
	30	1	3	3					
Olfactory epithelial regeneration	0								
	3								
	10			3	3	2			
	30			3	3	3	5	5	3
Respiratory epithelial metaplasia	0								
	3								
	10								
	30					1	5	5	3
Turbinate adhesions	0								
	3								
	10								
	30				2	1		3	

[a] Five animals per dose group. Because of ultrastructural examination only three nasal cavities were examined for 10 and 30 ppm groups on days 1, 3, 7, 14, and 91. Only four controls were examined on these days.

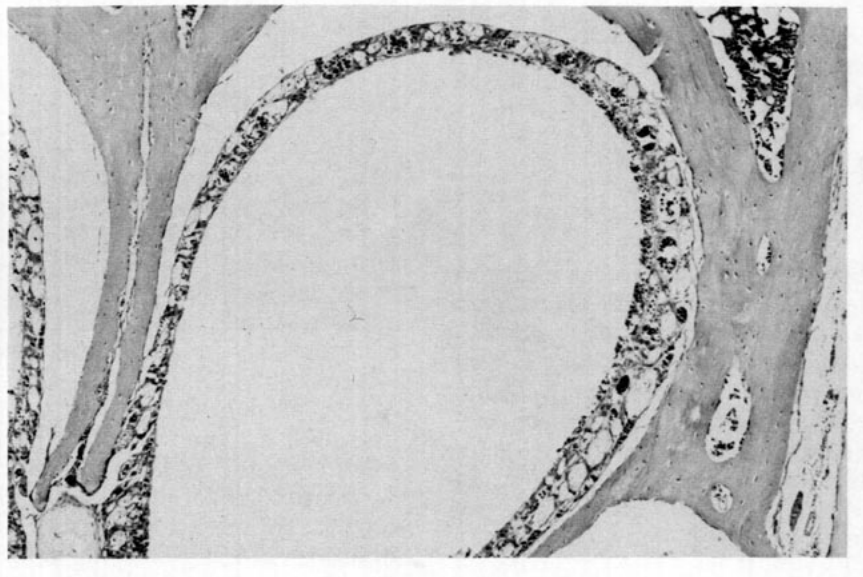

FIGURE 1. *Level II of the nasal cavity of a 30 ppm male mouse on day 1 following exposure with complete denudation of the respiratory* olfactory epithelia. H&E, 83×.

Table 2. Nasal cavity lesions in female mice.[a]

Morphological diagnosis	MIC dose, ppm	No. of nasal cavity lesions at various days after exposure							
		0	1	3	7	14	28	49	91
Acute inflammation	0			1					
	3						1		
	10		5	3	1				
	30	1	5	5	5	1			
Respiratory epithelial necrosis	0								
	3		3						
	10	5	5						
	30	5	1						
Respiratory epithelial erosion	0								
	3								
	10	3	4						
	30	5	5	1					
Olfactory epithelial necrosis	0								
	3								
	10	2							
	30	1	1						
Olfactory epithelial erosion	0								
	3								
	10								
	30		5	3					
Olfactory epithelial regeneration	0								
	3								
	10		4	3	1				
	30			5	5	5	2	2	1
Respiratory epithelial metaplasia	0								
	3								
	10								
	30					1	1	3	2
Turbinate adhesions	0								
	3								
	10								
	30			3	2	2	3	3	1

[a] Five animals were examined for each group.

affin, sectioned, and stained with hematoxylin and eosin. Selected lung and turbinate sections were stained with Mallory trichrome stain for collagen and alcian blue/PAS for mucopolysaccharide.

Pathology Peer Review

All target tissues (nasal cavity, trachea and lung for all animals on all days were reviewed by a second pathologist (R. Brown, Experimental Pathology Laboratories, Inc.) to confirm reported lesions. Additionally, other tissues selected as a comprehensive screen on days 7 and 91 were included in this review. Selected target lesions were reviewed by a Pathology Working Group (*7*).

Results

The exposure results are described by Bucher et al. (*3*). The mice showed few clinical signs except some ruffling of the hair coat in the high dose groups. Unscheduled deaths were not observed except in the 30 ppm group male mice where seven died within 24 hr after removal from the chamber. Two males died on day 2, and an additional seven mice died between days 10 and 78 for a total of 16/80 (20%) unscheduled deaths.

Gross Findings

Significant gross findings were restricted to the respiratory system and the thymus in the high dose animals. Two hours following exposure the lung appeared to deflate incompletely at necropsy, and at later sacrifices, atelectasis was observed at necropsy. The intermediate was the most frequently affected lobe, but occasionally the right anterior was involved. The thymus was observed to be smaller in some high dose males on days 1, 3, and 7.

Microscopic Findings

The significant microscopic findings generally were restricted to the respiratory system, but atrophy of the thymic cortex was also seen in high dose males. The morphology of the lesions in the respiratory system was similar in both sexes. The results are shown in Tables 1–4.

Polymorphonuclear leukocytes in the lumen of the nasal cavity and in the lamina propria were found during the first two weeks of the study. The lesion was more severe in males. Two hours after exposure, intracellular edema, nuclear pyknosis, coagulative necrosis, and erosion of the respiratory and olfactory epithelium were seen in the 10 and 30 ppm male and female mice. At

day 1 there was extensive erosion (Fig. 1) of the respiratory and olfactory epithelium in both sexes. The lesion was more severe and more extensive in the males. The severity and distribution of the lesion correlates with airflow and concentration gradients. The lesion was more severe anteriorly and along the septum and dorsal meatus. In level III, the dorsal lateral recesses of the ethmoturbinates were the least severely affected. By day 3 in females and by day 7 in males regeneration of both the olfactory and respiratory epithelium had occurred. From day 7 through 91, the respiratory epithelium appeared essentially normal in the nasal cavity. The olfactory epithelium recovered more slowly. At day 3, in both males and females, much of the olfactory area was covered by a layer of cuboidal cells one to two cell layers thick. The olfactory epithelium rapidly returned to a more normal appearance, including the presence of rudimentary bipolar olfactory neurons by day 14. The 3 and 10 ppm dosage groups at day 14 appeared essentially normal as compared to controls. In the 30 ppm males and to a lesser extent in females, the area of olfactory epithelium in the dorsal meatus level II showed incomplete regeneration (Fig. 2) and eventually was covered by respiratory epithelium (Tables 1 and 2). Focal areas on the ethmoturbinates also showed incomplete regeneration.

The pulmonary changes generally involved the major bronchi (Tables 3 and 4) and the trachea. Again the lesions were most severe and persistent in the males. In the 10 ppm males and 30 ppm exposure group of both sexes, there was extensive denudation of the respiratory epithelium in the trachea and major bronchi on days 1 and 3 with acute bronchitis and fibrin accumulation in the airways. This was followed by rapid epithelization of the trachea and slower recovery in the major bronchi. In the males, mural fibrosis (mostly lamina propria) and intraluminal fibrosis (Fig. 3) persisted through 91 days. In the females, the bronchial walls appeared normal by day 91, but the intraluminal fibrosis persisted to the end of the study.

In the high dose mice there was an increase of chronic alveolitis that was more extensive in males.

Discussion

Methyl isocyanate at or near the lethal dose caused severe necrosis of the epithelium of the respiratory system. There was a sharp dose response curve since almost complete denudation of turbinates, trachea and major airways was seen at 30 ppm with only minor lesions seen at 3 ppm. The lesions were more severe in males. This may be related to their greater body mass than females and thus more chemical exposure to the epithelial surface of the nasal cavity. The rapidity of epithelization of the turbinates, trachea, and major bronchi was surprising given the extent of the necrosis. At day 3 the epithelium of the nasal cavity was replaced in females, and at day 7 in males. The olfactory epithelium returned to normal in females, and only focal defects were present in males at day 91. While the olfactory epithelium appeared normal morphologically, the functional integrity was not known.

The intraluminal lesions in the major airways appear to result from organization of fibrin and debris in the lumen leading to fibroepithelial projections. These lesions did not completely resolve. It is expected that such lesions would have functional implications as was reported for rats with severely compromised pulmonary function after exposure to methyl isocyanate (*8*). The chronic alveolitis seen in many high dose mice was probably related to decreased pulmonary clearance due to the airway lesions.

Intraluminal fibrosis has been reported for a variety of lung disorders in man (*9*). Intraluminal alveolar buds which appear analogous to the lesions found in the bronchi of MIC-exposed mice were reported in patients with hypersensitivity pneumonitis (*10*), rheumatic pneumonitis (*11*), or inhalation of toxic fumes (*12*). The pathogenesis appears to be denudation of surface epithelium to the basement membranes, collection of fibrin in the alveolar or bronchiolar lumen, migration of fibroblasts into the fibrinous exudate which then replicate and produce connective tissue components, and subsequent epithelialization of the luminal mass (*9*). The distribution of the intraluminal fibrosis in the MIC-exposed mice appears to be restricted to the major bronchi. It might be predicted that the tracheal epithelium was subjected to a higher MIC exposure than the bronchi, but the intraluminal fibrosis did not occur in the trachea. There are several possible explanations for this apparent discrepancy between exposure and the occurrence of fibrosis. The tracheal epithelium may be more resistant to toxic injury or the mucous blanket may be thicker, thereby affording greater protection. Secondly, subepithelial glands are present in the upper part of the trachea of the mouse (*13*) but are lacking in the more peripheral airways. These glands may provide a protected reserve cell for a more rapid epithelialization of the trachea before migration of the fibroblasts could occur. Thirdly, the lung may contain more chemotactic factors than the trachea which may enhance the migration of fibroblasts through epithelial defects (*14,15*) leading to intraluminal fibrosis. Whether the lesion found in the MIC-exposed mice is analogous to the intraluminal fibrosis seen in a variety of conditions in man is not known. Depending on the nature and the severity of the initial epithelial injury, some cases of intraluminal fibrosis in man appear reversible (*9*).

This study suggests that exposure to near-lethal concentrations of MIC caused persistent fibrosis of the major bronchi in mice. At lower doses, the lesion was much less severe and recovery seemed complete at 91 days. Additional groups of mice are being held for up to 2 years to determine the long-term effects of MIC exposure.

The authors would like to acknowledge the help of the Comparative Medicine Branch (Kevin Denny, Carey Copeland, Gorden Caviness, Steve Meyers, and Larry Judd) for animal care and help in necropsies and to Joy Crowson for typing the manuscript.

Table 3. Pulmonary lesions in male mice.[a]

Morphological diagnosis	MIC dose, ppm	No. of nasal cavity lesions at various days after exposure							
		0	1	3	7	14	28	49	91
Bronchial erosion	0								
	3								
	10		4	1	1				
	30		5	5		3	2	1	
Acute bronchitis	0								
	3								
	10		4	1	1				
	30		5	5		3	2	1	
Chronic bronchitis	0								
	3								
	10					1			
	30				5	1		1	2
Bronchial fibrosis (M)[b]	0								
	3								
	10								
	30				5	5	5	4	4
Bronchial fibrosis (L)[c]	0								
	3								
	10								
	30				5	5	5	5	4
Chronic alveolitis	0								
	3	1							
	10					1			
	30				2	2	3	3	4
Atelectasis	0								
	3								
	10								
	30					3	3	3	3

[a] Five animals examined per group.
[b] (M) = Mucosa.
[c] (L) = intraluminal.

Table 4. Pulmonary lesions in female mice.[a]

Morphological diagnosis	MIC dose, ppm	No. of pulmonary lesions at various days after exposure[a]							
		0	1	3	7	14	28	49	91
Bronchial erosion	0								
	3								
	10								
	30		5	4	1				
Acute bronchitis	0								
	3								
	10			4					
	30		5	5	2				
Chronic bronchitis	0								
	3								
	10								
	30				2				
Bronchial fibrosis (M)[b]	0								
	3								
	10				3				
	30				2	3	3		
Bronchial fibrosis (L)[c]	0								
	3								
	10								
	30				3	5	3	4	4
Chronic alveolitis	0								
	3								
	10			1					
	30					1	2	1	2

[a] Five animals examined per group.
[b] (M) = mucosa.
[c] (L) = intraluminal.

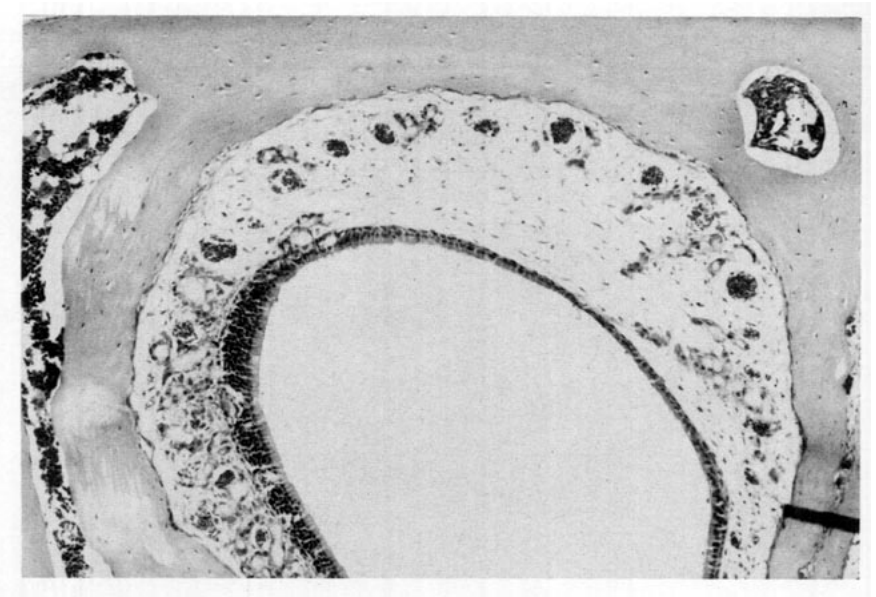

FIGURE 2. Dorsal meatus of level II of nasal cavity from 30 ppm male on day 91. Respiratory epithelial metaplasia in an area normally covered by olfactory epithelium; loss of Bowman's glands in the submucosa. H&E, 109×.

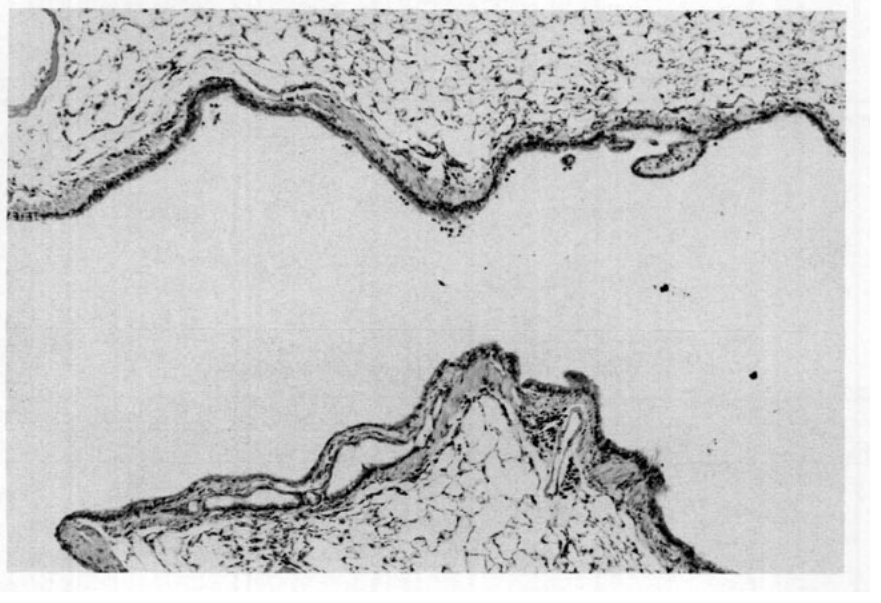

FIGURE 3. Major bronchus from a 30 ppm male mouse on day 91. Intraluminal fibrous projections covered by respiratory epithelium. H&E, 53×.

REFERENCES

1. Heylin, M. Bhopal. Chem. Eng. News 63: 14–15 (Feb. 11, 1985).
2. Lepowski, W. People of India struggle towards appropriate response to tragedy. Chem. Eng. News 63: 16–26 (Feb. 11, 1985).
3. Adkins, B., Jr., O'Connor, R., and Dement, J. Inhalation exposure system used for acute and repeated-dose methyl isocyanate exposures of laboratory animals. Environ. Health Perspect. 72: 45–51 (1987).
4. Bucher, J. R., Gupta, B. N., Adkins, B., Jr., Thompson, M., Jameson, C. W., Thigpen, J. E., and Schwetz, B. A. The toxicity of inhaled methyl isocyanate in F344/N rats and B6C3F1 mice. I. Acute exposure and recovery studies. Environ. Health Perspect. 72: 53–61 (1987).
5. Uraih, L. C., Mitsumori, K., Talley, F. A., Boorman, G. A., and Bucher, J. R. Ultrastructural changes in the nasal mucosa of Fischer 344 rats and B6C3F1 mice following an acute exposure to methyl isocyanate. Environ. Health Perspect. 72: 77–88 (1987).
6. Young, J. T. Histopathologic examination of the rat nasal cavity. Fund. Appl. Toxicol. 1: 309–312 (1981).
7. Boorman, G. A., Gupta, B. N., Uraih, L. C., Brown, R., and Bucher, J. R. Acute methyl isocyanate inhalation and recovery study in B6C3F1 mice. Toxicol. Appl. Pharmacol., in press.
8. Stevens, M. A., Fitzgerald, S., Menache, M. G., and Costa, D. L. Functional evidence of persistent airway obstruction in rats following a two-hour inhalation exposure to methyl isocyanate. Environ. Health Perspect. 72: 89–94 (1987).
9. Basset, F., Ferrans, V. J., Soler, P., Takemura, T., Fukuda, Y., and Crystal, R. G. Intraluminal fibrosis in interstitial lung disorders. Am. J. Pathol. 122: 443–461 (1986).

10. Kawanami, O., Basset, F., Barrios, R., Lacronique, J. G., Ferrans, V. J., and Crystal, R. G. Hypersensitivity pneumonitis in man: light and electronmicroscopic studies of 18 lung biopsies. Am. J. Pathol. 110: 275–289 (1983).
11. Masson, P., Riopelle, J. L., and Martin, P. O. Poumon rhumatismal. Ann. Anat. Pathol. (Paris) 14: 359–382 (1937).
12. Charan, N. B., Myers, C. G., Lakshminarayan, S., and Spencer, T. M. Pulmonary injuries associated with acute sulfur dioxide inhalation. Am. Rev. Respir. Dis. 119: 555–560 (1979).
13. Reznik-Schuller, H. M. The respiratory tract in rodents. In: Comparative Respiratory Tract Carcinogenesis (H. M. Reznik-Schuller, Ed.), CRC Press, Boca Raton, FL, Vol. I, Chapter 4, 1983, pp. 79–94.
14. Crystal, R. G., Bitterman, P. B., Rennard, S. I., Hance, A. J., and Keogh, B. A. Interstitial lung diseases of unknown cause. Disorders characterized by chronic inflammation of the lower respiratory tract. N. Engl. J. Med. 310: 154–166, 235–244 (1984).
15. Bitterman, P. B., Rennard, S. I., Adelberg, S., and Crystal, R. G. Role of fibronectin as a growth factor for fibroblasts. J. Cell Biol. 97: 1925–1982 (1983).