Environmental Health Perspectives
Vol. 72, pp. 125-132, 1987

Eighty-Five Day Postexposure Follow-up Study in Fischer 344 Rats After Repeated Exposures to Methyl Isocyanate Vapor

by Edward H. Fowler* and Darol E. Dodd*

The objectives of this study were to describe the microscopic lesions in the respiratory tract of Fischer 344 rats as a result of 4- or 8-days exposure (6 hr/day) of 3 ppm MIC and to characterize the postexposure development of these lesions up to day 85. All rats survived the exposure regimen, although significant decreases in body weight and encrustation of the eyes, nose, or mouth were observed. During the first 15 days of postexposure, the rats were hypoactive and had increased respiratory rates. Male mortality was as high as 63%; only 5% of the MIC-exposed females died. The cause of death was interpreted to be respiratory compromise complicated by anorexia and probably dehydration as well. During the next 28 postexposure days, 48% of the male survivors died, while only 3% of the female survivors died. Throughout the 85-day postexposure period, body weight gains in the MIC-treated groups were consistently below control values. Inflammatory and squamous metaplastic lesions of the respiratory tract, observed the day following completion of either the 4- or 8-day exposure regimen, decreased in both frequency and/or severity in survivors of the 85-day postexposure period, indicating recovery from the cytotoxic and irritating effects of MIC vapor. The squamous metaplastic epithelium was replaced by regenerative epithelium beginning in the deeper portion of the respiratory tract. Maturation of collagen occurred in the areas of submucosal fibroplasia.

Introduction

Acute inhalation studies with methyl isocyanate (MIC) vapor in Fischer 344 rats determined the 6-hr LC_{50} value to be 6.1 ppm (*1,2*). MIC vapor was determined to be a potent irritant, resulting in extensive damage to the respiratory mucosa in Fischer 344 rats, B6C3F1 mice, and Hartley guinea pigs (*2,3*). Subsequently, a repeated exposure study was conducted in which groups of male and female F344 rats were exposed to 3.1, 0.6, 0.15, or 0.0 (control) ppm of MIC vapor 6 hr per day for two 4-day periods separated by a 2-day rest (*4,5*). Only the 3.1 ppm exposure regimen resulted in biologically significant changes, and these were confined to the respiratory tract.

The objectives of this study, initiated in 1982 (prior to the Bhopal tragedy), were to more fully describe the lesions in the rat respiratory tract as a result of 4 or 8 days of exposure to MIC vapor and to characterize the subsequent development of these lesions during a 3-month recovery period.

Materials and Methods

Details of the materials, vapor generation methods, and analytical procedures used in this study have been described previously (*4*). Briefly, vapors of MIC-nitrogen gas were metered from a stainless-steel cylinder (*1*) containing liquid MIC into stainless-steel and glass chambers (4350 L) operated at an airflow rate of 1200 L/min. Chamber air was analyzed for MIC approximately three times per hr with a Perkin-Elmer 3920B gas chromatograph equipped with a nitrogen-phosphorus detector. A Perkin-Elmer automatic gas sampling system was used for chamber sampling. Calibration of the gas chromatograph was performed with liquid injections of MIC in *n*-hexane standard solutions which were prepared volumetrically. The minimum detection limit was approximately 100 ppb.

Animals Species, Source, and Husbandry

Male and female Fischer 344 rats [COB® CDF® (F-344)/CrlBR], 34 to 36 days of age, were received from Charles River Breeding Laboratories (Portage, MI). Upon arrival, fecal samples were examined for intestinal parasites by zinc sulfate flotation. The results were negative. The animals were kept on a 12-hr light/dark photoperiod throughout the study. Water, supplied by an automatic watering system, and powdered feed (Purina #5002) supplied by Ralston Purina Company (Richmond, IN) were available *ad libitum* except during inhalation exposures. All rats were numbered by toe clipping and housed two per cage in stainless-steel, wire-

*Bushy Run Research Center, Union Carbide Corporation, R. D. 4, Mellon Road, Export, PA 15632.

mesh cages (separated by test group and sex). A layer of Deotized Animal Cage Board® (Shepherd Specialty Papers, Inc., Kalamazoo, MI) was placed under each shelf of cages except during inhalation exposures.

Body weight and physical condition of all rats were followed for approximately 2 weeks prior to randomized assignment into exposure groups. At the time of group assignment, only animals with body weights within two standard deviations of the group mean for each sex were used in the study. Any animal in poor health or having eye lesions was rejected from group assignments.

Group Assignment and Exposure Regimen

The group size was 72/sex for the MIC-exposed rats and 25/sex for the air only (control) rats. The rats assigned to the MIC group were divided into 8-day (48/sex) and 4-day (24/sex) exposure subgroups. The target chamber concentration for the MIC-exposed rats was 3.0 ppm. For the 8-day subgroup, exposures were 6 hr/day for 4 consecutive days. After 2 days of rest, animals were exposed for an additional 4 consecutive days. Control animals were exposed to air alone. The 4-day subgroup was introduced into the chambers during the second 4-day regimen of the 8-day subgroup. Therefore, the 4-day, 8-day, and control rats, designated for sacrifice the day following their final exposure, were all sacrificed and necropsied the same day. The study design called for postexposure evaluations of rats at 1, 15, 43, and 85 days following termination of exposures (Table 1). Because of the unexpected number of deaths during the postexposure period, the number of rats sacrificed at these evaluation periods were fewer than planned.

Necropsy and Evaluation Procedures

Animals were observed for signs of toxic effects daily. Body weights were determined on the morning preceding the first, fourth, fifth, and eighth exposure and again preceding sacrifice. During the postexposure period, rats were weighed weekly. All rats were necropsied, but only respiratory tissues (i.e., nasal passages, larynx, trachea, bronchi, and lungs) were saved in 10% NBF for evaluation. Tissues were embedded in paraffin (following decalcification of the nasal tissues), sectioned at 5 microns, and stained with hematoxylin and eosin.

Body weight changes were compared by *t*-test. The actuarial life table method of Cutler and Ederer (*6*) was used for survival analysis. A fiducial limit of 0.05 (two-tailed) was used as a critical level of significance.

Table 1. Original design for postexposure sacrifices.

Sacrifice number	Postexposure day	Group identification	Number to be killed per sex
1	1	4-day exposure	8
		8-day exposure	8
		8-day control	5
2	15	4-day exposure	8
		8-day exposure	10
		8-day control	5
3	43	4-day exposure	8
		8-day exposure	10
		8-day control	5
4	85	8-day exposure	10
		8-day control	5
5	Optional	8-day exposure	10
		8-day control	5

Results and Discussion

Chamber Concentrations and Environmental Conditions

The mean analytical chamber concentration for each exposure day was 3.0 ppm. No MIC was detected in the control chamber. A brief overexposure occurred during the first hour of exposure day 5. An MIC concentration as high as 12.6 ppm was detected, but the time-weighted average for the first hour was only 4.6 ppm. Nominal chamber concentrations were not calculated because the concentration of the MIC in the head space of the generation cylinder was not determined. Daily mean chamber temperature and relative humidity for all exposure groups ranged from 72° to 77°F and 33 to 44%, respectively. The housing quarters for the postexposure period were within a temperature range of 71° to 76°F and had a relative humidity range of 32 to 50% for the majority of time.

Animal Observations

During the exposure regimen, several cases of perinasal, perioral, or periocular wetness and/or encrustation were observed in the 3.0 ppm male and female rats. Approximately one-third of the MIC-exposed males had audible respiration during the second week of exposure (days 5 through 8). A few female rats had perineal wetness. No clinical abnormalities were observed in the control rats.

For MIC-exposed survivors, the most frequent observation was increased respiratory rate in both males and females, 8-day or 4-day treated, during postexposure days 1 through 15. In addition, hypoactivity was frequently observed in the 3.0 ppm rats. A few cases of perinasal, perioral, or periocular wetness and/or encrustation, as well as ataxia, were observed. No new clinical signs appeared during the postexposure period and clinical signs decreased in frequency with time.

Body Weights

Figure 1 illustrates the mean body weights for rats exposed to either 4 or 8 days of 3.0 ppm of MIC and for control animals. As expected from the first repeated exposure study (*4,5*), MIC-treated rats had a large decrease in body weight compared to control animals during the exposure regimen. In general, the magnitude of the decrease in body weight was greater in the 8-day

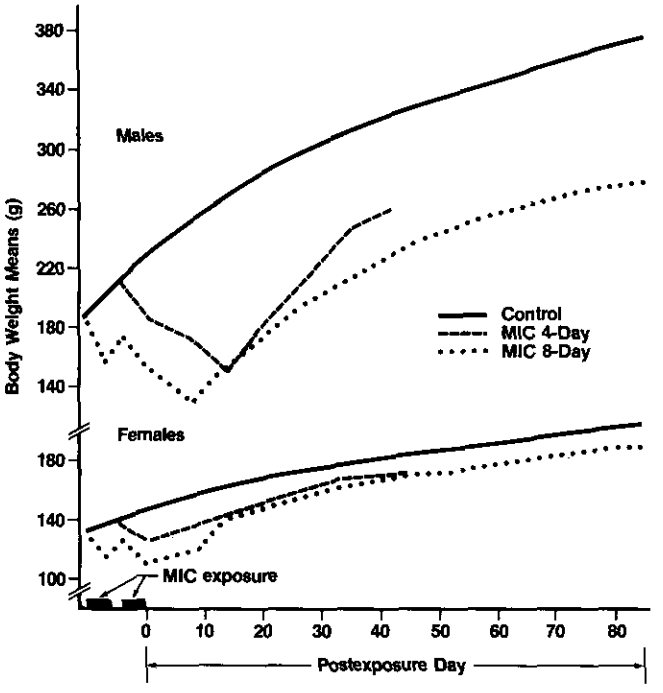

FIGURE 1. Body weights for male and female Fischer 344 rats following either 4 or 8 days of exposure to 3.0 ppm of methyl isocyanate vapor.

MIC-exposed rats than in the 4-day exposed rats. Recovery from body weight loss in female rats began soon after the last MIC exposure. However, in MIC-exposed males, recovery from body weight loss did not begin until postexposure week 3. In MIC-exposed male rats, recovery from body weight loss took longer in the 4-day group than in the 8-day group, although the 4-day group recovered more weight. This was not the case for female rats, in which the time and magnitude of recovery from body weight loss were comparable for the 4-day and 8-day MIC-treated groups. The air-exposed control animals had body weight gains at each weighing period throughout the study.

Mortality

No deaths were observed during either the 4- or 8-day MIC exposure regimen. However, 63% of the MIC-exposed male survivors died during postexposure days 2 through 15, while only 5% of the female survivors died during this time interval. For each sex, the cumulative survival between the 4-day and the 8-day MIC-treated rats were similar (Table 2). For the postexposure period of 16 through 43 days, 10 of 21 male survivors (48%) and 1 of 35 female survivors (3%) died. No deaths occurred during the postexposure period of 44 through 85 days. No control rats died during the study. The cause of death appeared to be respiratory compromise complicated by anorexia, and probably dehydration as well, as evidenced by the rats' empty stomachs at the time of necropsy. The failure to eat and drink was attributed to degeneration and necrosis of the olfactory epithelium produced by the MIC vapor, as it is generally accepted that rats are stimulated to eat by smell. The observed mortality difference between sexes was not observed in previous acute studies (*1–3*). Differences in mortality between sexes have been observed with F344 rats exposed to acrolein vapor, another potent cytotoxic and irritating chemical (*7*), but no explanation was given for the difference.

Pathology

Sacrifice the Day Following the Final Exposure

The only consistent gross lesion observed in rats sacrificed on the day following the 4- or 8-day exposure was evidence of pulmonary congestion. More female rats had evidence of congestion than did male rats in both the 4-day and the 8-day exposure groups. Nasal cavities were flushed with formalin at the time of necropsy, but were not opened until after fixation; and therefore, gross lesions were not detected in the upper respiratory tract.

Inflammation and squamous metaplasia were present with the same relative frequency in the upper respiratory tract in the 4- and 8-day rats (Table 3). The only principal difference was the less frequent squamous metaplasia and submucosal fibroplasia in the bronchioles of male rats exposed for 4 days compared to those exposed for 8 days. There was also a greater frequency of regenerative epithelial hyperplasia in the lungs and tracheas of the female rats exposed for 8 days than was observed in the 4-day exposed animals (Fig. 2). The severity of lesions between the 4- and 8-day exposed rats was not appreciably different.

Sacrifice on Postexposure Day 15

No male rats were sacrificed on postexposure day 15 because of the large number of deaths that occurred between postexposure days 1 and 15 (Table 2). Among the female rats sacrificed at this time, only one had pulmonary congestion at necropsy.

The microscopic lesions are presented in Table 3. While squamous metaplasia was still evident in the upper respiratory tract, namely the nasal passages and larynx, it could no longer be observed in the trachea or the bronchioles. However, the frequency of regenerative epithelial hyperplasia was increased from that seen on postexposure day 1, especially in the lungs of the 4-day exposed rats and in the tracheas of the 8-day exposed rats.

Sacrifice on Postexposure Day 43

Male and female rats from both the 4- and 8-day exposure groups were sacrificed and necropsied on postexposure day 43 (Table 2). Nearly all of the male rats had evidence of pulmonary congestion at necropsy,

Table 2. Number of Fischer 344 rats sacrificed or found dead after exposure to 3.0 ppm of MIC vapor for 4 or 8 days.

Sex	Exposure group	No. starting study	No. sacrificed, Day 1	15	43	85	No. found dead, Days 1–15	16–43	44–85
Male	Control	25	5	0	10	5	0(0)[a]	0(0)	0(0)
	8 day	48	8	0	6	3	24(50)	7(15)	0(0)
	4 day	24	8	0	2	—	11(46)	3(13)	—
Female	Control	25	5	5	5	5	0(0)	0(0)	0(0)
	8 day	48	8	10	10	10[b]	3(6)	0(0)	0(0)
	4 day	24	8	8	7	—	0(0)	1(4)	—

[a] Numbers in parentheses indicate percent dead.
[b] Seven of the remaining 8-day exposed female rats were not sacrificed.

Table 3. Frequency of lesions in the respiratory tract of Fischer 344 rats exposed 4 or 8 days to 3.0 ppm of MIC vapor and sacrificed on postexposure days 1 and 15.

	Postexposure day 1						Postexposure day 15		
	Males			Females			Females		
Organs/lesions	4-day	8-day	Control	4-day	8-day	Control	4-day	8-day	Control
Nasal passages									
Number examined	8	8	5	8	8	5	8	10	5
Rhinitis	6	7	0	8	8	0	0	1	0
Ulceration/erosion	2	0	0	5	0	0	0	0	0
Squamous metaplasia	8	8	0	8	8	0	6	7	0
Larynx									
Number examined	8	8	5	8	8	5	8	9	5
Laryngitis	1	1	0	0	2	0	1	1	0
Regenerative hyperplasia	0	1	0	0	0	0	5	5	0
Squamous metaplasia	7	8	0	8	8	0	6	4	0
Trachea									
Number examined	8	8	5	8	8	5	8	10	5
Tracheitis	4	6	0	5	6	0	0	1	0
Regenerative hyperplasia	0	2	0	0	3	0	1	10	0
Squamous metaplasia	6	7	0	7	8	0	0	0	0
Lungs/bronchioles									
Number examined	8	8	5	8	8	5	8	10	5
Bronchiolitis	5	6	0	7	4	0	0	0	0
Pneumonitis	0	4	0	0	2	0	1	4	0
Regenerative hyperplasia	2	2	0	0	7	0	7	10	0
Squamous metaplasia	1	5	0	5	7	0	0	0	0
Submucosal fibroplasia	1	6	0	0	0	0	0	0	0

whereas only one female rat had any color change in the lungs.

Table 4 lists the frequency of microscopic lesions observed from rats sacrificed on postexposure day 43 from the 4- and 8-day exposure groups. Squamous metaplasia from the nasal passages to the bronchioles was observed in a few male rats from the 8-day group, but for the most part, the squamous metaplasia was confined to the upper portion of the respiratory tract, and regenerative hyperplasia of mucosal epithelium was present in the trachea and bronchioles. Submucosal fibroplasia was still present in the bronchioles of male rats from both the 4- and 8-day exposure groups, but by this time the character of the fibrous connective tissue core was changing to consist of more mature fibrous tissue, and the polypoid projections into the lumina were not as pronounced (Fig. 3).

Sacrifice on Postexposure Day 85

Only male and female rats from the 8-day exposure group were scheduled for sacrifice on postexposure day 85 (Table 2). Only three male rats from the 3.0 ppm exposure group were alive at this point. Seventeen of the 3.0 ppm-exposed female rats survived, ten of which were necropsied and examined microscopically with five control rats from the male and female groups. At necropsy, only one MIC-exposed female rat had any evidence of pulmonary congestion.

Table 4 lists the frequency of lesions observed at postexposure day 85. There was still evidence of squamous metaplasia in the upper respiratory tract and regenerative epithelial hyperplasia in the lower tract, especially in the male rats, which had more severe lesions compared to the females. Submucosal fibroplasia was still

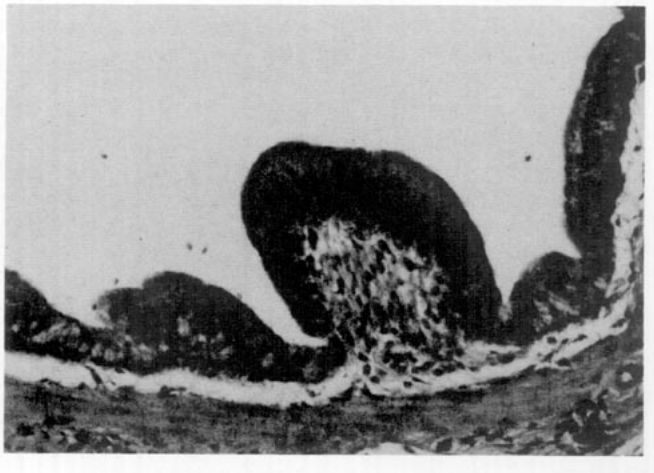

FIGURE 2. Regenerative epithelium covering a small area of submucosal fibroplasia in a female rat exposed to 3.0 ppm of MIC vapor for 8 days. H & E, × 160.

evident, with the central portion of the polypoid projections consisting of dense fibrous connective tissue (Fig. 4). Mucous plugs were present in terminal bronchioles and alveoli in a few rats of both sexes (Fig. 5).

Sacrifices performed on postexposure days 15, 43, and 85 revealed a progressive resolution of the changes initially observed on the day following termination of MIC exposures. The squamous metaplasia initially observed throughout the mucosal epithelium down to and including the respiratory bronchioles was replaced by regenerative mucosal epithelium. The regenerative mucosal epithelium first seen in the lower respiratory tract proceeded cephalad as time progressed. Epithelial regeneration looked different with time: the cells were less numerous and cuboidal rather than columnar due to maturation of the new epithelium. Inflammation was reduced in both frequency and severity throughout the respiratory tract with time, and there appeared to be little evidence of residual effect in the pulmonary tissues at 85 days postexposure.

Rats Found Dead

The most significant and consistent finding at necropsy was pulmonary congestion, which was observed in almost all of the rats found dead and usually involved most of the lung parenchyma. Also observed at the time of necropsy was a lack of ingesta in the stomachs of many of the rats that died.

Table 5 presents the principal microscopic findings in the rats found dead. Autolytic changes were present in some of the tissues, making critical evaluation difficult or impossible depending on the extent of the autolysis. The most consistent changes observed in the nasal tissues were congestion, present in most of the rats, and degeneration or necrosis of respiratory and/or olfactory mucosa, which were more frequently observed in the rats that died shortly after termination of exposures. Squamous metaplasia was observed in the nasal tissues in only those male and female rats exposed for 8 days to the MIC vapor.

The most common finding in the larynges of the rats that died was squamous metaplasia. However, in the

Table 4. Frequency of lesions in the respiratory tract of Fischer 344 rats exposed 4 or 8 days to 3.0 ppm of MIC vapor and sacrificed on postexposure days 43 and 85.

	Postexposure day 43						Postexposure day 85			
	Males			Females			Males		Females	
Organs/lesions	4-day	8-day	Control	4-day	8-day	Control	8-day	Control	8-day	Control
Nasal passages										
Number examined	2	6	10	7	10	5	3	5	10	5
Rhinitis	0	4	0	0	0	0	2	0	1	0
Ulceration/erosion	0	0	0	0	0	0	0	0	0	0
Squamous metaplasia	0	6	0	3	4	0	3	0	1	0
Larynx										
Number examined	2	6	10	7	10	5	3	5	10	5
Laryngitis	0	0	0	0	0	0	0	0	2	0
Regenerative hyperplasia	0	0	0	2	0	0	0	0	1	0
Squamous metaplasia	2	1	0	0	2	0	0	0	2	0
Trachea										
Number examined	2	6	10	7	10	5	3	5	10	4
Tracheitis	0	2	0	0	0	0	0	0	1	0
Regenerative hyperplasia	2	0	0	3	4	0	2	0	0	1
Squamous metaplasia	0	1	0	0	0	0	0	0	0	0
Lungs/bronchioles										
Number examined	2	6	10	7	10	5	3	5	10	5
Bronchiolitis	0	4	0	0	0	0	1	0	0	0
Pneumonitis	1	5	0	0	0	0	2	0	0	0
Regenerative hyperplasia	2	5	0	6	6	0	3	0	1	0
Squamous metaplasia	0	2	0	0	0	0	0	0	0	0
Submucosal fibroplasia	1	3	0	0	0	0	2	0	0	0

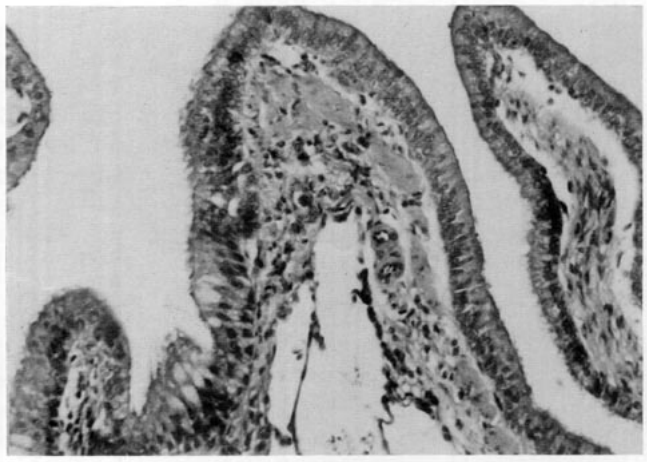

FIGURE 3. Mature fibrous connective tissue in the core of two intraluminal polyps arising in the bronchiolar wall of a male rat 43 days after 8 days of exposure to 3.0 ppm of MIC vapor. H & E, × 160.

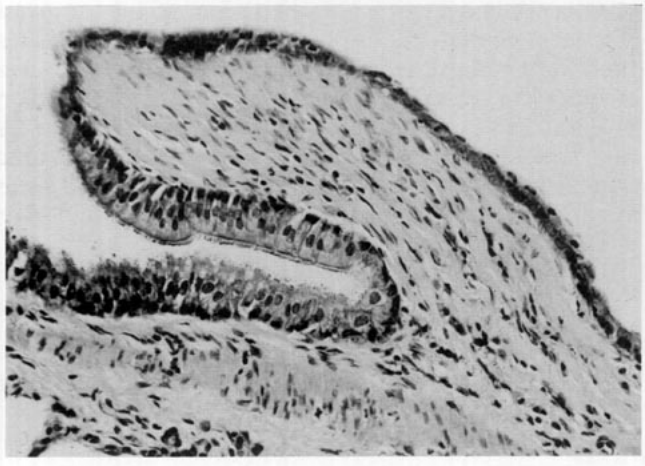

FIGURE 4. Intraluminal polyp consisting of mature fibrous connective tissue covered by regenerative epithelium in a bronchiolar wall of a male rat 85 days after 8 days of exposure to 3.0 ppm of MIC vapor. H & E, × 160. (Reprinted courtesy of Academic Press.)

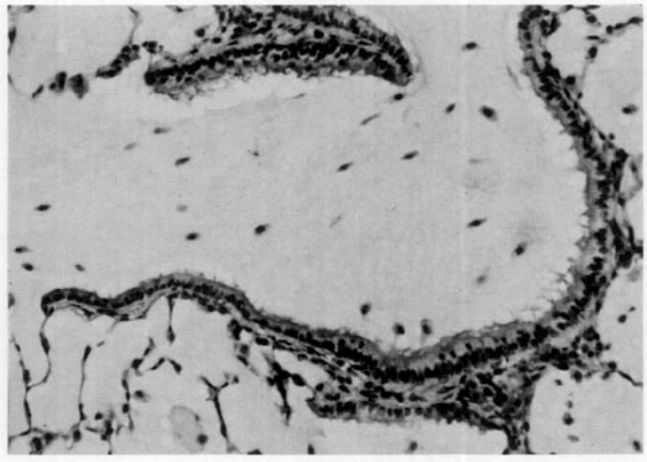

FIGURE 5. Mucus present in the terminal bronchiole and alveoli of a male rat 85 days following exposure to 3.0 ppm of MIC vapor for 8 days. H & E, × 160. (Reprinted courtesy of Academic Press.)

Table 5. Frequency of lesions in the respiratory tract of Fischer 344 rats that died following exposure to 3.0 ppm of MIC vapor for 4 or 8 days.

	Males		Females	
Organs/lesions	*4-day*	*8-day*	*4-day*	*8-day*
Nasal passages				
Number examined	14	30	1	3
Congestion	10	30	0	2
Rhinitis	2	4	0	1
Degeneration/necrosis	9	16	0	3
Regenerative hyperplasia	0	3	0	0
Squamous metaplasia	0	7	0	3
Larynx				
Number examined	13	31	1	3
Laryngitis	1	0	0	0
Necrosis	0	3	0	0
Regenerative hyperplasia	0	1	0	0
Squamous metaplasia	12	18	1	3
Trachea				
Number examined	11	31	1	3
Necrosis	1	5	0	0
Congestion	1	3	0	0
Regenerative hyperplasia	0	20	0	1
Squamous metaplasia	1	1	0	1
Edema	0	3	0	0
Lungs				
Number examined	14	31	1	3
Congestion	13	30	1	2
Edema	7	19	1	2
Hemorrhage	6	9	1	1
Pneumonitis	9	16	0	1
Hyaline membrane	0	8	0	1
Necrosis	0	19	0	2
Regenerative hyperplasia	0	15	0	1
Squamous metaplasia	0	8	0	0
Submucosal fibroplasia	4	7	0	0

tracheas, the most frequent lesion observed was epithelial regeneration, especially in the 8-day exposed male rats. Necrosis was present in the laryngeal and tracheal epithelium from a few male rats exposed for 8 days to MIC vapor.

The lungs revealed a number of changes which appeared different from, or more severe than, the changes observed in the sacrificed rats. Congestion, and occasionally hemorrhage, was observed in many of the rats that died. Edema, inflammation, and hyaline membrane depositions were changes that appeared either only in rats that died (edema, hyaline membranes) or more severely (pneumonitis) in these rats (Figs. 6–8). The pneumonia was manifested in various ways, either as bronchopneumonia, diffuse fibrinous or fibrinopurulent pneumonia, or interstitial pneumonia. Necrosis, epithelial regeneration, and squamous metaplasia of bronchiolar epithelium were observed only in the dead male or female rats exposed to MIC vapor for 8 days. Submucosal fibroplasia was confined to the male rats and was observed with about equal frequency and severity as in the sacrificed rats.

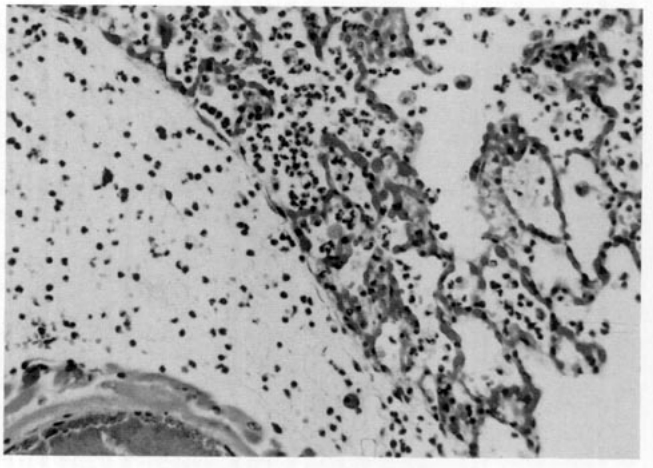

FIGURE 6. Perivascular edema, congestion, and pneumonia in the lung of a male rat that died 10 days following 8 days of exposure to 3.0 ppm of MIC vapor. H & E, × 160.

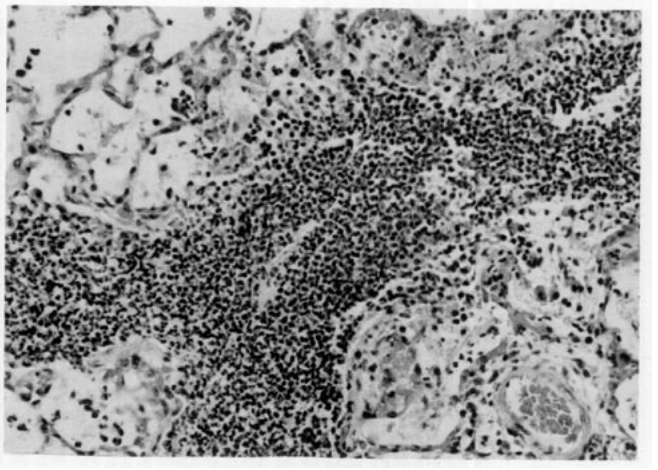

FIGURE 8. Suppurative bronchopneumonia extending from the bronchiole into the alveoli in a male rat that died 39 days following 8 days of exposure to 3.0 ppm MIC vapor. H & E, × 160.

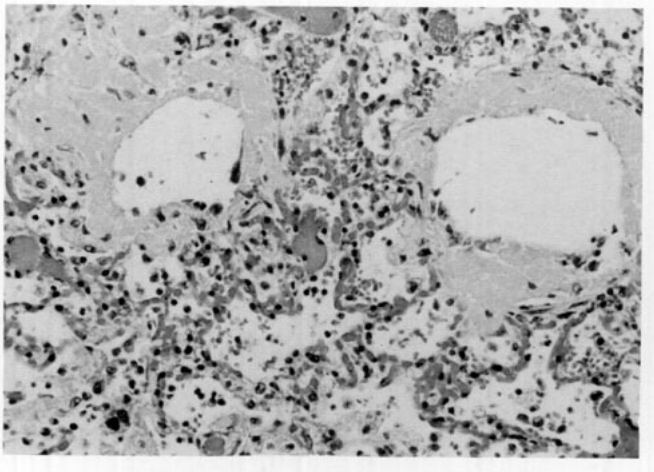

FIGURE 7. Hyaline membrane formation and congestion in the lung of a male rat that died 5 days following 8 days of exposure to 3.0 ppm of MIC vapor. H & E, × 160. (Reprinted courtesy of Academic Press.)

The fact that edema and hyaline membrane deposits were observed in some of the rats that died following repeated exposures to MIC vapor is a noteworthy difference from those animals that were sacrificed, and probably contributed to the death of the rats by respiratory insufficiency. The infusion of lungs with 10% NBF, as was performed in these studies, is not considered the most appropriate method for detection of lung edema because infusion tends to remove evidence of mild pulmonary edema (*8*).

Similarities to Acrolein Exposure

The lung lesions induced in male F344 rats by inhalation of 4.0 ppm of acrolein vapor 6 hr/day for 62 days of exposure were similar to some of those observed in rats exposed to MIC vapor in that bronchiolar epithelial necrosis, bronchiolar mucopurulent plugs, and focal pneumonitis occurred with acute rhinitis (*7*). The severity of pulmonary lesions with respect to acrolein vapor inhalation was described as being somewhat more variable from animal to animal and from one area of the lung to another in the same rat (*7*) than were the lesions observed in the MIC vapor-exposed rats in both of the repeated exposure studies (*4,5*). None of the 3.1 ppm or 3.0 ppm MIC vapor-exposed rats completed the exposure regimen without some evidence of damage involving the bronchioles and upper respiratory tract. However, involvement of the alveoli was quite variable (negligible or slight) in many of the rats.

Conclusions

F344 rats exposed to 3.0 ppm of MIC vapor for 4 or 8 repeated exposures of 6 hr/day developed lesions in the respiratory tract which reflected the cytotoxic and irritating nature of MIC. Substantially more male rats died following 4 or 8 days of repeated exposures to MIC vapor than did females. Rats that died had evidence of more severe pulmonary lesions, including edema, hyaline membrane formation, and pneumonia in the lungs, than did the survivors. Rats found dead also had little evidence of ingesta in their stomachs, which suggested that perhaps the degeneration of the olfactory mucosa in the nasal passages had resulted in their failure to eat. Recovery of rats was followed up to 85 days. Repair of the injured respiratory mucosa took the form of replacement of the metaplastic epithelium by regenerative epithelium, beginning first in the deeper portion of the tract. The regenerative epithelium matured as time progressed. The submucosal fibroplasia developed into more mature collagen that retracted, causing shrinkage of the polypoid projections observed in the lumina of bronchioles. The inflammation observed throughout the respiratory system immediately following termination of exposures decreased in both frequency and severity as the time after exposure increased. It is concluded

that recovery of the respiratory tract was substantial in the F344 rat during the 85 days of postexposure, with the few remaining residual lesions consisting of regenerative airway epithelium and small areas of submucosal fibroplasia.

The authors wish to thank the inhalation staff and Irwin Pritts for conducting the exposures; the necropsy and histology staff for performing the necropsies and preparing the slides; and Gayle DiSalvo for preparing the photographic prints. The authors also wish to thank Kathleen McCabe for typing the manuscript.

REFERENCES

1. Dodd, D. E., Fowler, E. H., Snellings, W. M., Pritts, I. M., and Baron, R. L. Acute inhalation studies with methyl isocyanate vapor. Part I. Methodology and LC_{50} determinations in guinea pigs, rats, and mice. Fundam. Appl. Toxicol. 6: 747–755 (1986).
2. Fowler, E. H., and Dodd, D. E. Respiratory tract changes in guinea pigs, rats, and mice following a single six-hour exposure to methyl isocyanate vapor. Environ. Health Perspect. 72: 109–116 (1987).
3. Fowler, E. H., and Dodd, D. E. Acute inhalation studies with methyl isocyanate vapor. Part II. Respiratory tract changes in guinea pigs, rats, and mice. Fundam. Appl. Toxicol. 6: 756–771 (1986).
4. Dodd, D. E., and Fowler, E. H. Methyl isocyanate subchronic vapor inhalation studies with Fischer-344 rats. Fundam. Appl. Toxicol. 7: 502–522 (1986).
5. Dodd, D. E., Fowler, E. H., Snellings, W. M., and Pritts, I. M. Methyl isocyanate eight-day vapor inhalation study with Fischer 344 rats. Environ. Health Perspect. 72: 117–122 (1987).
6. Cutler, S. J. and Ederer, F. Maximum utilization of the life table method in analyzing survival. J. Chronic Dis. 8: 699–713 (1958).
7. Kutzman, R. S., Popenoe, E. A., Schmaeler, M., and Drew, R. T. Changes in rat lung structure and composition as a result of subchronic exosure to acrolein. Toxicology 34: 139–151 (1985).
8. Hammond, T. G., and Mobbs, M. Lung oedema—microscopic detection. Appl. Toxicol. 4: 219–221 (1984).