Environmental Health Perspectives
Vol. 73, pp. 115-123, 1987

Experimental Induction of Ovarian Sertoli Cell Tumors in Rats by *N*-Nitrosoureas

by Akihiko Maekawa,* H. Onodera,* H. Tanigawa,* K. Furuta,* J. Kanno,* T. Ogiu,† and Y. Hayashi*

Spontaneous ovarian tumors are very rare in ACI, Wistar, F344 and Donryu rats; the few neoplasms found are of the granulosa/theca cell type. Ovarian tumors were also rare in these strains of rats when given high doses of *N*-alkyl-*N*-nitrosoureas continuously in the drinking water for their life-span; however, relatively high incidences of Sertoli cell tumors or Sertoli cell tumors mixed with granulosa cell tumors were induced in Donryu rats after administration of either a 400 ppm *N*-ethyl-*N*-nitrosourea solution in the drinking water for 4 weeks or as a single dose of 200 mg *N*-propyl-*N*-nitrosourea per kg body weight by stomach tube. Typical Sertoli cell tumors consisted of solid areas showing tubular formation. The tubules were lined by tall, columnar cells, with abundant, faintly eosinophilic, often vacuolated cytoplasm, and basally oriented, round nuclei, resembling seminiferous tubules in the testes. In some cases, Sertoli cell tumor elements were found mixed with areas of granulosa cells.

The induction of ovarian Sertoli cell tumors in Donryu rats by low doses of nitrosoureas may provide a useful model for these tumors in man.

Introduction

There is a need for good animal models for human ovarian tumors. Spontaneous ovarian tumors are rare in rats, and there are few useful methods of experimental induction of ovarian tumors in this species (*1*). This paper describes the experimental induction of ovarian Sertoli cell tumors by *N*-alkyl-*N*- nitrosoureas as a potential animal model of human ovarian tumors.

Materials and Methods

Four strains (ACI/N, Slc:Wistar, F344/DuCrj, and Donyru) of female rats were used for this study. The housing conditions of the animals and occurrence of spontaneous tumors in all strains except Donryu rats have been described in previous papers (*2–5*).

Ten forms of *N*-alkyl-*N*-nitrosoureas were used in these carcinogenicity studies: *N*-methyl-*N*-nitrosourea (MNU); *N*-methyl-*N'*-acetyl-*N*-nitrosourea (Ac-MNU); *N*-carboxymethyl-*N*-nitrosourea (CMNU); *N*-ethyl-*N*-nitrosourea (ENU); *N*-propyl-*N*-nitrosourea (PNU); *N*-butyl-*N*-nitrosourea (BNU); *n*-butyl-*N'*,*N'*-dimethyl-*N*-nitrosourea (D*i*M-BNU); *N*,*N'*-dibutyl-*N*-nitrosourea (B-BNU); *N*-*i*-butyl-*N*-nitrosourea (*i*-BNU); and *N*-amyl-*N*-nitrosourea (ANU). Ten- to eleven-week-old rats were administered solutions of these chemicals in their drinking water for their life-span. The dose levels used, with the exception of the experiment using low doses of ENU in F344 rats, were the maximum dose tolerated in each strain of rat. Detailed results have been published previously (*6–20*).

Two additional experiments were carried out using Donryu rats. In the first experiment, (Experiment 1), forty 10-week-old rats were administered a 400 ppm solution of ENU in the drinking water for 4 weeks. In the second experiment (Experiment 2), 80 rats were given a single dose of 200 mg PNU per kg body weight by stomach tube. After the treatment, the animals in both experiments were divided into two subgroups. One-half of the rats in each experiment were then maintained on a standard diet, and the other half were administered a diet containing 0.25% phenylbutazone for 2 years. One hundred animals were also maintained as untreated controls. Observations were continued until week 110, when all survivors were sacrificed. The purpose of these two experiments was to investigate the promoting potential of phenylbutazone in rats. A short report has been published on these experiments (*21*).

Results

Spontaneous Ovarian Tumors

Eight ovarian tumors were seen in untreated rats. The tumor incidences in ACI, Wistar, F344, and Donryu

*Division of Pathology, Biological Safety Research Center, National Institute of Hygienic Sciences, Kamiyooga 1-18-1, Setagaya-ku, Tokyo 158, Japan.
†Laboratory of Ultrastructure Research, Aichi Cancer Center Research Institute, Kanokoden 81-1159, Tashiro-cho, Chikusa-ku, Nagoya 464, Japan.

rats were 1/209 (0.5%), 3/100 (3%), 2/297 (0.7%), and 2/96 (2.1%), respectively. Histologically, six ovarian tumors were granulosa/theca cell tumors (Plates 1 and 2), and the other two were fibromas.

Ovarian Tumors in Treated Rats

Table 1 summarizes incidences and types of ovarian tumors in rats given *N*-alkyl-*N*-nitrosoureas continuously in the drinking water for a life-span and lists other target organs. All these chemicals were strongly carcinogenic; the target organs differed with the compound and strain of rats used. Incidences of ovarian tumors, however, were very low in all experiments; only a few Sertoli cell tumors were observed in Donryu rats given B-BNU or ANU, and in F344 rats given low doses of ENU. Table 2 shows the incidences and histological types of ovarian tumors observed in Donryu rats given a 400 ppm ENU solution in the drinking water for 4 weeks (Experiment 1) or a single dose of 200 mg PNU per kg body weight by stomach tube (Experiment 2). In this table, the numbers of rats in each subgroup were totaled within each experiment, because no modifying activity of phenylbutazone for induction of ovarian tumors was observed. Ovarian tumors were induced at incidences of about 50% in both experiments. Mean survival times of rats with ovarian tumors were 52.7 weeks in Experiment 1 and 78.6 weeks in Experiment 2. In contrast, only two tumors were found in 96 untreated control rats, and the mean survival time of tumor-bearing animals was 109.5 weeks. Many other neoplasms, such as tumors of the uterus, kidney, mammary gland, and intestine, and leukemias were also observed in both experiments.

The majority of the induced ovarian tumors were unilateral. Tumors were round, oval or irregular in shape, and of various sizes. Their cut surfaces were usually solid, although occasional cyst formation and areas of hemorrhage were evident. On histological examination, most of the ovarian tumors induced were found to be Sertoli cell tumors which consisted of solid areas of tubular formation. The tubules were lined by tall, columnar cells, with abundant, faintly eosinophilic, often vacuolated cytoplasm and basally oriented, round nuclei. These tubules were separated by thin fibrovascular stroma and resembled seminiferous tubules in the testis (Plates 5–10). There was variation in the size and form of the tubules. In some cases, hyaline bodies of varying sizes, which were positive for PAS, were observed in the cytoplasm of tumor cells or in the lumen of tubules (Plate 11). Mitotic figures were usually rare. No histological findings suggesting that these tubules had arisen from downgrowth of the surface epithelium were found in any case. In cases diagnosed as Sertoli cell tumors mixed with granulosa cell tumors, histological patterns ranging from typical tubular structures to those more characteristic of granulosa cell tumors were observed within single tumor nodules, and differentiating between Sertoli cell tumors, granulosa cell tumors, and mixed tumors was sometimes difficult (Plates 12–

Table 1. Target organs, incidences, and types of ovarian tumors in rats given *N*-alkyl-*N*-nitrosoureas continuously in the drinking water.

$$R_1\text{–}\overset{\displaystyle NO}{\overset{|}{N}}\text{–}\underset{\underset{\displaystyle O}{\|}}{C}\text{–}R_2$$

Chemicals	R_1	R_2	Strains of rats	Dose[a], ppm	Target organs	Incidences[b] and types of ovarian tumors
MNU	CH_3	NH_2	Donryu	400–100	Nervous system forestomach	0/96
			F344	200–100	Nervous system tongue, glandular stomach	0/79
			ACI/N	200	Nervous system kidney, heart	0/33
Ac-MNU	CH_3	$NH{\cdot}COCH_3$	ACI/N	66–13	Nervous system glandular stomach	0/90
CMNU	CH_2COOH	NH_2	Donryu	400–100	Small intestine, mammary gland	1/112 (fibroma)
ENU	C_2H_5	NH_2	Donryu	400–100	Bone marrow	0/104
			F344	400	Small intestine	0/40
			F344	10–0.3	Nervous system intestine	2/203 (2 Sertoli)
PNU	n-C_3H_7	NH_2	Donryu	600–150	Bone marrow	1/109 (fibrosarcoma)
			F344	400	Thymus, small intestine	0/39
BNU	n-C_4H_9	NH_2	Donryu	400–100	Bone marrow	0/54
			F344	400	Upper digestive tract	0/39
D*i*M-BNU	n-C_4H_g	$N(CH_3)_2$	Donryu	400–100	Bone marrow, vagina	0/100
i-BNU	i-C_4H_9	NH_2	Donryu	400–100	Small intestine	0/77
B-BNU	n-C_4H_9	$NH{\cdot}n$-C_4H_9	Donryu	400–100	Mammary gland	3/69 (3 Sertoli)
ANU	n-C_5H_{11}	NH_2	Donryu	400–100	Forestomach, bone marrow	4/101 (3 Sertoli, 1 fibroma)

[a] In all experiments, rats were administered solutions of these chemicals daily in their drinking water for the life-spans.
[b] Number of rats with ovarian tumors/number of rats treated.

Table 2. Incidences and histological types of ovarian tumors induced in Donryu rats given ENU or PNU, and mean survival times of rats with ovarian tumors.

Experiment number	Treatment	Number of rats	Ovarian tumors: Incidence[a]	Ovarian tumors: Histological types	Mean survival time, weeks
1	400 ppm ENU in the drinking water for 4 weeks	33	16 (2)[b] (48.5%)	11 Sertoli 5 Sertoli + granulosa[c] 2 granulosa	52.7 (46–74)[d]
2	Single 200 mg PNU/kg body weight by stomach tube	76	39 (6)[b] (51.3%)	20 Sertoli 15 Sertoli + granulosa 8 granulosa 1 osteosarcoma 1 fibroma	78.6 (61–109)
Control		96	2 (2.1%)	2 granulosa	109.5 (109–110)

[a]Numbers of rats with tumors.
[b]Numbers of rats with bilateral ovarian tumors.
[c]Granulosa includes granulosa and granulosa/theca cell tumors.
[d]Numbers in parentheses are ranges of survival time.

15). In most tumors, proliferation of Leydig-cell or theca-cell elements was not apparent.

Discussion

Generally, spontaneous ovarian tumors are uncommon in rats (*1*). Of the few spontaneous ovarian tumors arising in F344 rats, the most common type was granulosa/theca cell tumors (*22,23*). Our results were in good agreement with the findings in other laboratories. Recently, however, Gregson et al. (*24*) reported that the most commonly observed ovarian tumors in Sprague-Dawley rats were tubular adenomas arising from downgrowth of the surface epithelium. The occurrence of tubular structures in ovarian tumors of rats and mice is well documented (*1, 25–29*); however, the classification and nomenclature of tubular adenomas in experimental animals is complicated and controversial. Tubular adenomas of mice are generally accepted as arising from downgrowth of the surface epithelium (*28*). It is possible that Sertoli cell tumors, which are sex cord tumors, may have been included in the tubular adenoma category reported by others because tubular structures resembling seminiferous tubules were apparent in some reported cases.

Methods such as transplantation of the ovary, hormonal treatment, irradiation, or administration of chemical carcinogens have been used in attempts to induce ovarian tumors in rats. For example, granulosa-theca cell tumors can be induced in rats by the transplantation of the ovary to various ectopic sites such as the spleen (*30*) and also by intrasplenic transplantation of the ovary coupled with 7,12-dimethylbenzanthracene (DMBA) treatment (*31*). Granulosa/theca cell tumors appear to be hormonally active, because in rats with these tumors, hyperplastic proliferation of the uterus, vagina, or mammary gland is observed.

There is little direct evidence that hormones are responsible for the induction of tumors. There is also little experimental evidence that ovarian tumors can be induced in rats by irradiation, although this is the oldest and most effective method for induction of ovarian tumors in mice (*32*). Polycyclic hydrocarbons such as DMBA and 3-methylcholanthrene have mainly been used for chemical induction of ovarian tumors. Although they result in good tumor yields in mice, there are only a few reports of success in rats. In one report, Kato et al. (*33*) succeeded in inducing ovarian tumors in rats by treatment with DMBA. Most of these DMBA-induced tumors were adenocarcinomas that were considered to originate from the surface epithelium (Plate 16), suggesting a useful experimental model for human ovarian carcinomas. Sertoli cell tumors of the ovary are quite rare both in human beings and rats, and there has been no previous report of their successful high yield, other than the recent report by Stoica et al. (*34*). Our study suggests a useful experimental animal model for Sertoli cell tumors.

In several ovarian tumors observed in the present study, histological patterns ranging from typical tubular structures to those more characteristic of granulosa cell tumors were observed within single tumor nodules. Sertoli cell differentiation has been seen in mouse granulosa cell tumors (*28*), and Knowles (*35*) also described mixtures of both elements in rat ovarian tumors induced by ENU coupled with radiation treatment. There is a degree of architectural and cytological overlap between these two neoplasms in human beings (*36*). Mixed tumors observed in the present study indicate that Sertoli and granulosa cell elements are homologous, with a common origin from the sex cord.

Recently, Knowles (*35,37*) reported low incidences of ovarian tumors, which showed tubular formation and were interpreted as of Sertoli cell type, in Harwell Mouth Tumor rats given ENU together with radiation. Stoica et al. (*34*) also reported induction of Sertoli cell tumors of the ovary of Sprague-Dawley and BD-IV rats by intraperitoneal on transplacental treatment with ENU. These data and our present results show conclusively that such nitrosoureas as ENU and PNU can induce Sertoli cell tumors in some strains of rats. Incidences of ovarian tumors were very low when high doses of these nitrosoureas were given to rats in the drinking water for a life-span (Table 1). High doses of

N-nitroso compounds show a pronounced organotropism in rats. Development of other tumors such as ovarian tumors is masked by the elimination of animals early in the study because of selective induction of specific tumors with short latent periods. For example, as shown in Table 1, continuous oral administration of ENU at doses of 400 to 100 ppm rapidly and selectively induced erythroleukemias in Donryu rats, and no ovarian tumors were detected in a total of 104 treated rats (*12*). The fact that the amounts of the chemicals given in the present two experiments described in this paper were low might explain the high rate of induction of ovarian tumors. Another important factor may be variation in susceptibility of different strains of rats. Only two Sertoli cell tumors were found in a total of 203 F344 rats given low doses of ENU (*9*), (Table 1). Schmähl and Habs (*38*) reported that the location of tumors induced by *N*-nitroso compounds depends not only on the chemical structure of individual carcinogens, but also on the administration route, strains of rats used, or dose of the compounds. Our results are consistent with their opinion.

The possible hormonal function of Sertoli cell tumors observed in the present study is still uncertain and is the focus of ongoing research in our laboratory.

REFERENCES

1. Carter, R. L., and Ird, E. A. Tumors of the ovary. In: Pathology of Tumors in Laboratory Animals, Vol. 1, Part 2 (V.S. Turusov, Ed.), IARC, Lyon, 1976, pp. 189–200.
2. Maekawa, A., and Odashima, S. Spontaneous tumors in ACI/N rats. JNCI 55: 1437–1445 (1975).
3. Maekawa, A., Kurokawa, Y., Takahashi, M., Kokubo, T., Ogiu, T., Onodera, H., Tanigawa, H., Ohno, Y., Furukawa, F., and Hayashi, Y. Spontaneous tumors in F344/DuCrj rats. Gann 74: 365–372 (1983).
4. Maekawa, A., Onodera, H., Tanigawa, H., Furuta, K., Kodama, Y., Horiuchi, S., and Hayashi, Y. Neoplastic and non-neoplastic lesions in aging Slc:Wistar rats. J. Toxicol. Sci. 8: 279–290 (1983).
5. Maekawa, A., Onodera, H., Tanigawa, H., Furuta, K., Matsuoka, C., Kanno, J., Ogiu, T., and Hayashi, Y. Spontaneous neoplastic and non-neoplastic lesions in aging Donryu rats. Jpn. J. Cancer Res. (Gann) 77: 882–890 (1986).
6. Fujii, K., Nakadate, M., Ogiu, T., and Odashima, S. Induction of digestive tract tumors and leukemias in Donryu rats by administration of 1-amyl-1-nitrosourea in drinking water. Gann 71: 464–470 (1980).
7. Maekawa, A., Odashima, S., and Nakadate, M. Induction of tumors in the stomach and nervous system of the ACI/N rat by oral administration of 1-methyl-3- acetyl-1-nitrosourea. Z. Krebsforsch. 86: 195–207 (1976).
8. Maekawa, A., Ogiu, T., Matsuoka, C., Onodera, H., Furuta, K., Tanigawa, H., and Odashima, S. Induction of tumors of the small intestine and mammary gland of female Donryu rats by continuous oral administration of N-carboxymethyl-N-nitrosourea. J. Cancer Res. Clin. Oncol. 106: 12–16 (1983).
9. Maekawa, A., Ogiu, T., Matsuoka, C., Onodera, H., Furuta, K., Kurokawa, Y., Takahashi, M., Kokubo, T., Tanigawa, H., Hayashi, Y., Nakadate, M., and Tunimura, A. Carcinogenicity of low doses of N-ethyl-N-nitrosourea in F344 rats. A dose-response study. Gann 75: 117–125 (1984).
10. Maekawa, A., Matsuoka, C., Onodera, H., Tanigawa, H., Furuta, K., Ogiu, T., Mitsumori, K., and Hayashi, Y. Organ specific carcinogenicity of N-methyl-N-nitrosourea in F344 and ACI/N rats. J. Cancer Res. Clin. Oncol. 109: 178–182 (1985).
11. Odashima, S. Development of leukemia in rats by oral administration of N-nitrosobutylurea in the drinking water. Gann 60: 237 (1969).
12. Ogiu, T., Nakadate, M., and Odashima, S. Rapid and selective induction of erythroblastic leukemias in female Donryu rats by continuous oral administration of 1-ethyl-1-nitrosourea. Cancer Res. 36: 3043–3046 (1975).
13. Ogiu, T., Nakadate, M., and Odashima, S. Induction of leukemias and digestive tract tumors in Donryu rats by 1-propyl-1-nitrosourea. JNCI 54: 887–893 (1975).
14. Ogiu, T., Nakadate, M., Furuta, K., Maekawa, A., and Odashima, S. Induction of tumors of peripheral nervous system in female Donryu rats by continuous oral administration of 1-methyl-1-nitrosourea. Gann 68: 491–498 (1977).
15. Ogiu, T., Kajiwara, T., Furuta, K., Takeuchi, M., Odashima, S., and Tada, K. Mammary tumorigenic effect of a new nitrosourea, 1,3-dibutyl-1-nitrosourea (B-BNU), in female Donryu rats. J. Cancer Res. Clin. Oncol. 96: 35–41 (1980).
16. Ogiu, T., Matsuoka, C., Furuta, K., Takeuchi, M., Maekawa, A., Nakadate, M., and Odashima, S. Induction of angiogenic tumors in the duodenum of female Donryu rats by continuous oral administration of N-isobutyl-N-nitrosourea. Gann 74: 342–350 (1983).
17. Takeuchi, M., Maekawa, A., Tada, K., and Odashima, S. Leukemia and vaginal tumors in female Donryu rats by continuous oral administration of 1-butyl-3,3-dimethyl-1-nitrosourea in the drinking water. JNCI 56: 1177–1181 (1976).
18. Takeuchi, M., Ogiu, T. Nakadate, M. and Odashima, S. Induction of duodenal tumors in F344 rats by continuous oral administration of N-ethyl-N-nitrosourea. JNCI 64: 613–616 (1980).
19. Takeuchi, M., Ogiu, T., Nakadate, M., and Odashima, S. Induction of duodenal tumors and thymomas in Fischer rats by continuous oral administration of 1-propyl-1-nitrosourea. Gann 71: 231–237 (1980).
20. Takeuchi, M., Ogiu, T., Matsuoka, C., Furuta, K., Maekawa, A., Nakadate, M., and Odashima, S. Induction of digestive-tract tumors in F344 rats by continuous oral administration of N-butyl-N-nitrosourea. J. Cancer Res. Clin. Oncol. 107: 32–37 (1984).
21. Maekawa, A., Onodera, H., Tanigawa, H., Kanno, J., Furuta K., and Hayashi, Y. Induction of Sertoli cell tumors in the rat ovary by N-alkyl-N-nitrosoureas (short communication). J. Cancer Res. Clin. Oncol. 111: 173–176 (1986).
22. Goodman, D. G., Ward, J. M., Squire, R. A., Chu, K. C., and Linhart, M. S. Neoplastic and nonneoplastic lesions in aging F344 rats. Toxicol. Appl. Pharmacol. 48: 237–248 (1979).
23. Solleveld, H. A., Haseman, J. K., and McConnel, E. E. Natural history of body weight gain, survival, and neoplasia in the F344 rat. JNCI 72: 929–940 (1984).
24. Gregson, R. N., Lewis, D. J., and Abbott, D. P. Spontaneous ovarian neoplasms of the laboratory rat. Vet. Pathol. 21: 292–299 (1984).
25. Engle, E. T. Tubular adenomas and testis-like tubules of the ovaries of aged rats. Cancer Res. 6: 578–582 (1946).
26. Frith, C. H., Zuna, R. E., and Morgan, K. A morphologic classification and incidence of spontaneous ovarian neoplasms in three strains of mice. JNCI 67: 693–702 (1981).
27. Lemon, P. G., and Gubareva, A. V. Tumors of the ovary. In: Pathology of Tumors in Laboratory Animals, Vol. 2 (V. S. Turusov, Ed.), IARC, Lyon, 1979, pp. 385–410.
28. Murphy, E. D. Characteristic tumors. In: Biology of the Laboratory Mouse (E. L. Green, Ed.), Dover Publishing Inc., New York, 1966, pp. 521–562.
29. Rehm, S., Dierksen, D., and Deerberg, F. Spontaneous ovarian tumors in Han: NMRI mice: histologic classification, incidence, and influence of food restriction. JNCI 72: 1383–1395 (1984).
30. Biskind, G. R., and Biskind, M. S. Experimental ovarian tumors in rats. Am. J. Clin. Pathol. 19: 501–521 (1949).
31. Hilfrich, J. A new model for inducing malignant ovarian tumors in rats. Br. J. Cancer 28: 46–54 (1973).
32. Furth, J., and Furth, O. B. Neoplastic diseases produced in mice by general irradiation with X-rays. I. Incidences and types of neoplasms. Am. J. Cancer 28: 54–65 (1936).
33. Kato, T., Yakushiji, M., Tsunawaki, A., and Ide, K. Studies on experimental ovarian tumors. Ovarian tumors developed in rats

receiving chemical carcinogen 9,10-dimethyl-1,2-benzanthracene. Kurume Med. J. 21: 11–19 (1974).
34. Stoica, G., Koestner, A., and Capen, C. C. Testicular (Sertoli's cell)-like tumors of the ovary induced by N-ethyl-N-nitrosourea (ENU) in rats. Vet. Pathol. 22: 483–491 (1985).
35. Knowles, J. F. Cancer of rat ovaries: Sertoli cell or granulosa-theca cell tumors? (Short communication.) Br. J. Cancer 48: 301–305 (1983).
36. Fox, L. Sex cord-stromal tumours of the ovary. J. Pathol. 145: 127–148 (1985).
37. Knowles, J. M. Reduction of N-nitroso-N-ethylurea-induced neurogenic tumors by X-radiation: a life-span study in rats. JNCI 72: 133–137 (1984).
38. Schmähl, D., and Habs, M. Carcinogenicity of N-nitroso compounds: Species and route differences in regard to organotropism. Oncology 37: 237–242 (1980).

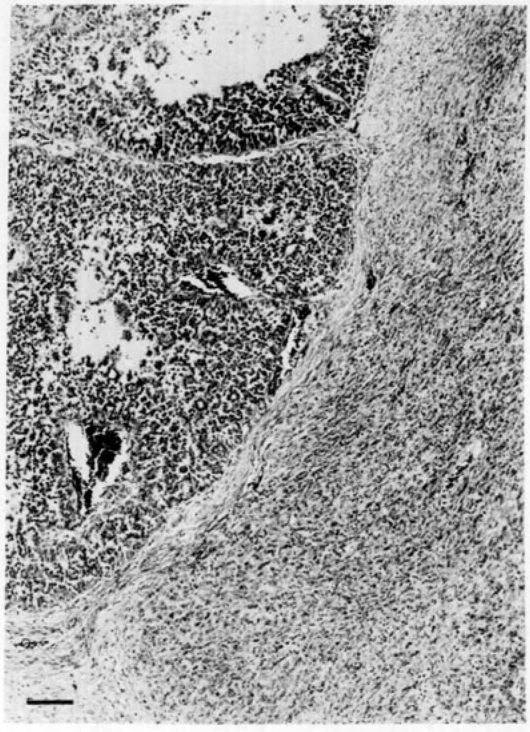

PLATE 1. Granulosa/theca cell tumor. Folliclelike areas composed of granulosa cells are surrounded by elongated fibroblastlike theca cells. H&E. Bar = 100 μm.

PLATE 2. Silver staining of granulosa/theca cell tumor. Dense pericellular arrangement of reticulin fibers is prominent in the area comprising theca cell elements, while fibers are observed as a delicate network enclosing clumps of tumor cells in granulosa cell element. Bar = 100 μm.

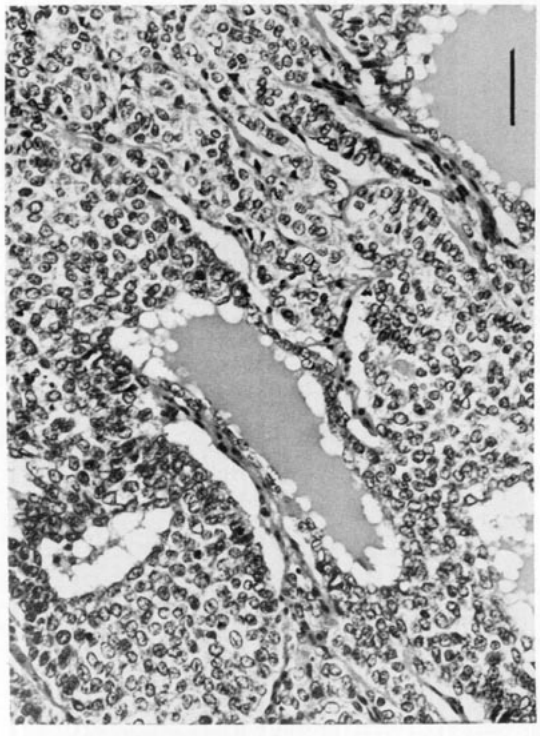

PLATE 3. Granulosa cell tumor. Vacant areas are visible within folliclelike areas. H&E. Bar = 50 μm.

PLATE 4. Granulosa cell tumor. Tumor cells are arranged in pseudopalisading pattern around the vessels. H&E. Bar = 50 μm.

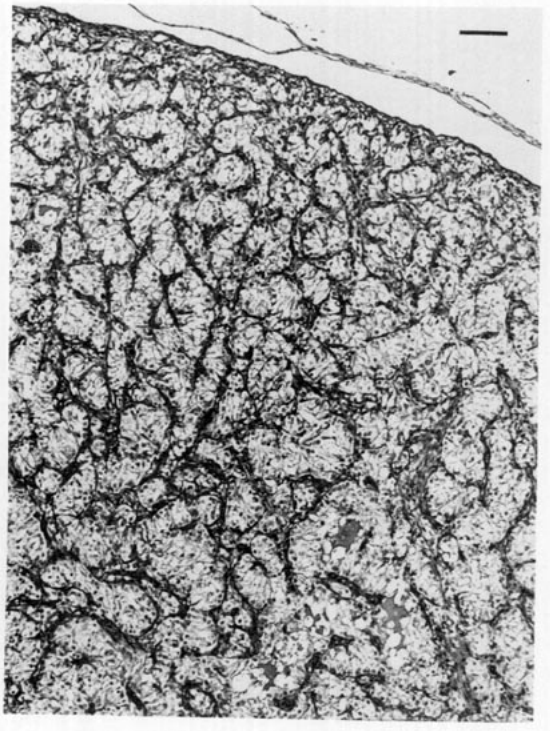

PLATE 5. Typical Sertoli cell tumor. Tubular structures separated by thin fibrovascular stroma are prominent. H&E. Bar = 100 μm.

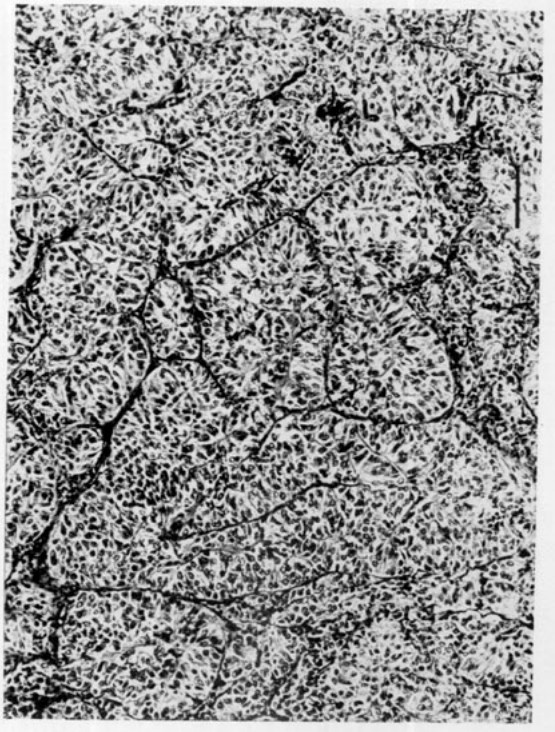

PLATE 6. Sertoli cell tumor. Tubular structures consist of spindle-like tumor cells with randomly oriented nuclei. H&E. Bar = 100 μm.

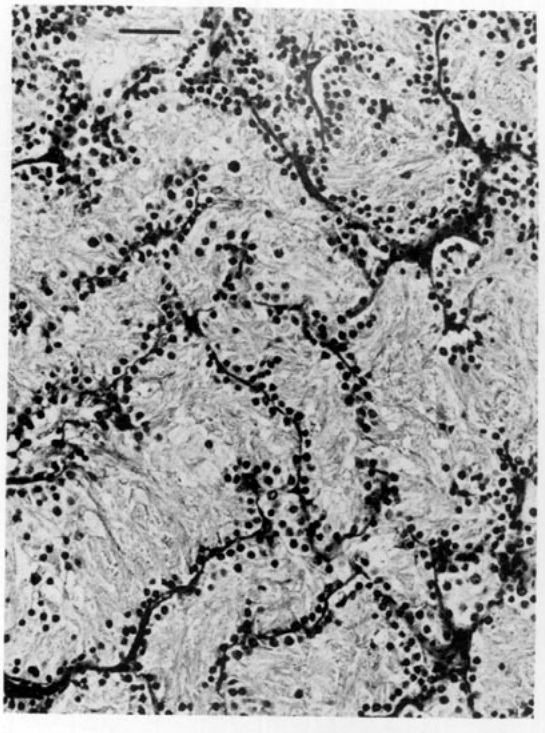

PLATE 7. Sertoli cell tumor. Tubules are lined by tall, columnar cells, with abundant, vacuolated cytoplasm and basally oriented, round nuclei. H&E. Bar = 100 μm.

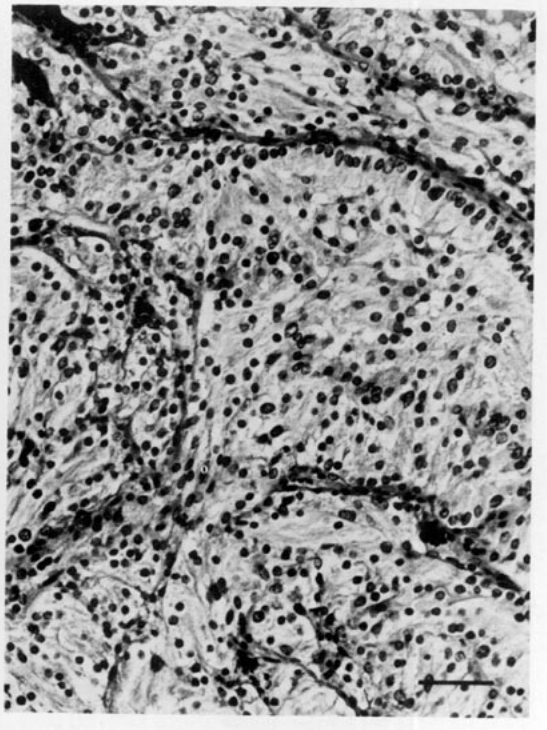

PLATE 8. Sertoli cell tumor. H&E. Bar = 50 μm.

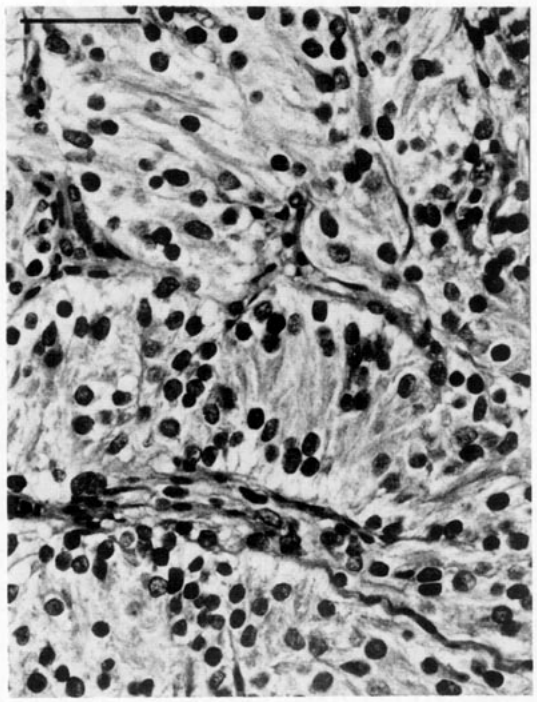

PLATE 9. Higher magnification of Plate 8. No mitotic figures are evident. H&E. Bar = 50 μm.

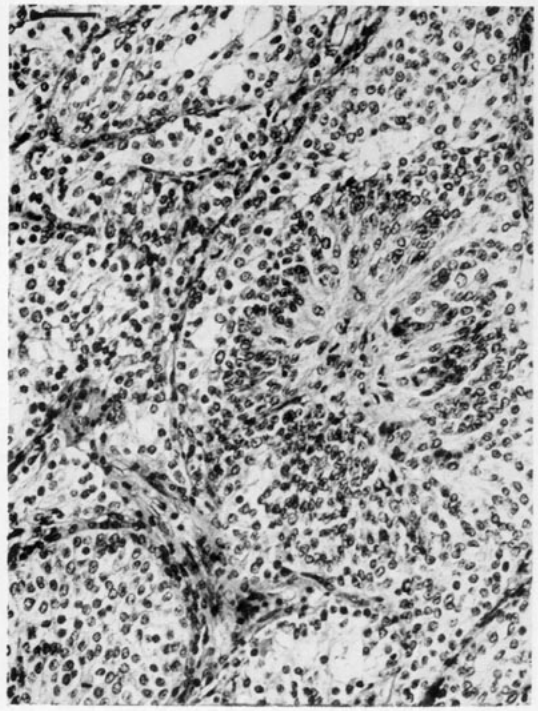

PLATE 10. Sertoli cell tumor with less evident tubular structure than seen in Plates 5–9. The large tubule in the center seems to have been formed by proliferation of tumor cells with invagination of the surrounding basement membrane. H&E. Bar = 50 μm.

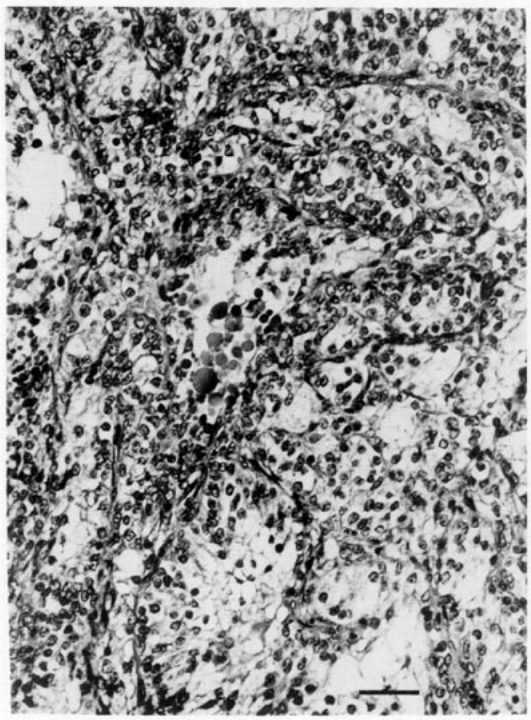

PLATE 11. Sertoli cell tumor. Various sized eosinophilic bodies are observed in the lumina of tubules. H&E. Bar = 50 μm.

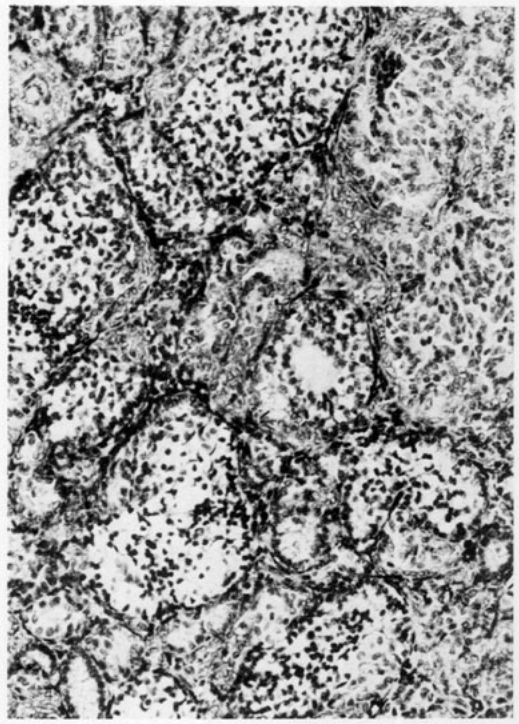

PLATE 12. Granulosa cell tumor differentiating to Sertoli cell type. Tubular structure is less evident and vacant areas are found in the center of folliclelike areas. H&E. Bar = 50 μm.

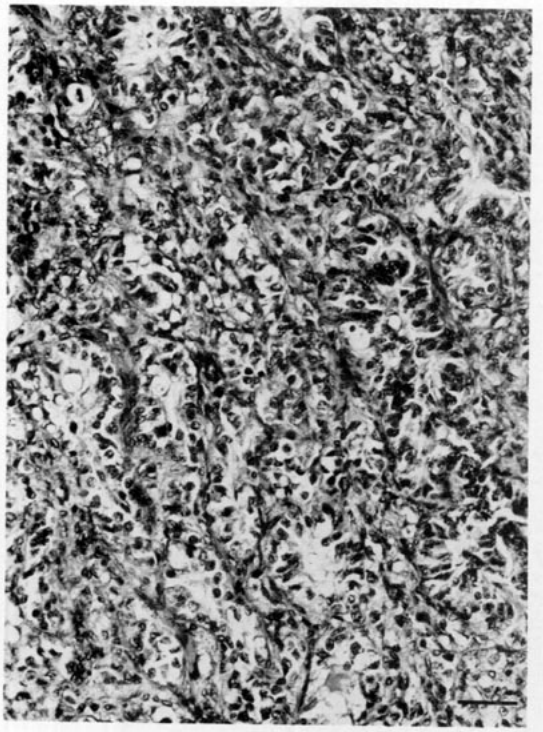

PLATE 13. Another example of granulosa cell tumor differentiating to Sertoli cell type. Tubular structure is also less evident, but some areas resemble seminiferous tubules. H&E. Bar = 50 μm.

PLATE 14. Sertoli cell tumor mixed with granulosa cell tumor. H&E. Bar = 100 μm.



PLATE 15. Another example of tumor with both elements. H&E. Bar = 100 μm.

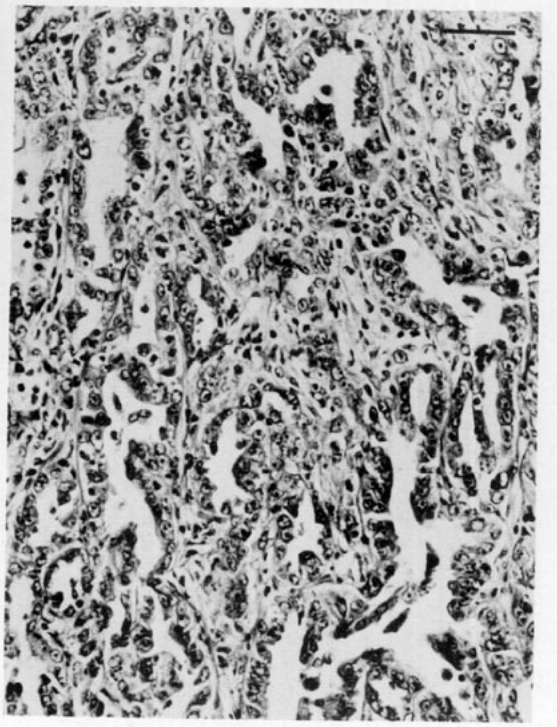

PLATE 16. Adenocarcinoma of the ovary observed in rats treated with DMBA (photograph supplied by Dr. Kato, Kurume Medical College, Kurume, Japan). H&E. Bar = 50 μm.