Environmental Health Perspectives
Vol. 73, pp. 157-169, 1987

Effects of Long-Term Nitrogen Dioxide Exposure on Rat Lung: Morphological Observations

by Kentaro Kubota,* Masataka Murakami,* Shinji Takenaka,* Kiyoyuki Kawai,† and Hiroko Kyono†

Rats continuously exposed to NO_2 at 0.04, 0.4, and 4.0 ppm for as long as 27 months were submitted to morphological observation and electronmicroscopic morphometry of the lung.

At 4 ppm exposure for 9 months, bronchial epithelium showed typical proliferation, which progressed further at 18 months. At this stage, proliferation of type II alveolar epithelium and edematous extension of interstitial tissue were evident and yielded fibrosis at 27 months.

At 0.4 ppm, morphological changes in 18-month specimens were still ambiguous, although a tendency toward epithelial changes, as well as interstitial edema of the alveolar wall, was noticed under the electron microscope. Slight but definite alteration of the epithelium became evident after 27 months. At 0.04 ppm there were no remarkable changes throughout the entire exposure period.

The morphometry revealed concentration- and duration-dependent increases in arithmetic mean thickness (AMT) of the alveolar wall. At 4 ppm, increase of AMT started as early as 9 months, became significant at 18 months, and showed a slight decrease at 27 months. This decrease was interpreted as a recovery of alveolar epithelium and decreased amount of septal edema, which in turn led to fibrosis. At 0.4 ppm, a slight increase of AMT started at 18 months and extended significantly in 27 months. A similar but insignificant tendency was found even at 0.04 ppm.

The morphological alterations were parallel to the concentration and duration of exposure. These findings suggested that an intensive study should be conducted to confirm whether alterations were due to prolonged exposure and/or due to elevated sensitivity of the aged lung.

Introduction

When animals were exposed to high concentrations of NO_2, they died due to hemorrhage, edema, and cell infiltration in the lung. The study of long-term NO_2 exposure is important for elucidating the effects on humans exposed to polluting agents in the atmosphere (*1,2*).

There are a number of reports, including a series of works by Freeman and his colleagues, concerning the morphological effects on the lungs of relatively low concentrations of NO_2 for 1 month or longer (*3–11*). The common fundamental lesions in these studies are found mainly at both the airways and bronchopulmonary junction, and include: uneven arrangement, shortening, or loss of cilia in ciliated epithelium, and hypertrophy, hyperplasia, and hypersecretion of nonciliated epithelium; fibrous thickening of connective tissue at the terminal end of air tracts; and damage and desquamation of type I epithelial cells and subsequent proliferative response of type II epithelial cells. Extremely high levels of NO_2 exposure induced emphysema (*3–6,8,10,11*), and the pathological findings in the lung from this disease were reported (*12–14*). There were, however, very few reports on effects of NO_2 at a low level over a lifetime under well-controlled experimental conditions. Moreover, the usual descriptive pathology is insufficient to evaluate the degree of such mild or focal lesions caused by ambient levels of NO_2 concentration and to compare studies.

The experimental methods used in this study included not only ordinary light and electron transmission microscopy, but also electron microscopic morphometry as described by Weibel et al. (*15,16*) to obtain quantitative data on pathological findings (*17–21*). Pathological changes were evaluated objectively.

Materials and Methods

Experimental Conditions

Animals. Two-month-old male rats of JCL/Wistar strain (SPF) were exposed continuously (24 hr/day) to three concentration levels of NO_2 (0.04 ± 0.008, 0.40

*Basic Medical Sciences Division, National Institute for Environmental Studies, Yatabe, Tsukuba, Ibaraki, 305, Japan.
†National Institute of Industrial Health, 21-1 Nagao 6-chome, Tama-ku, Kawasaki 214, Japan.

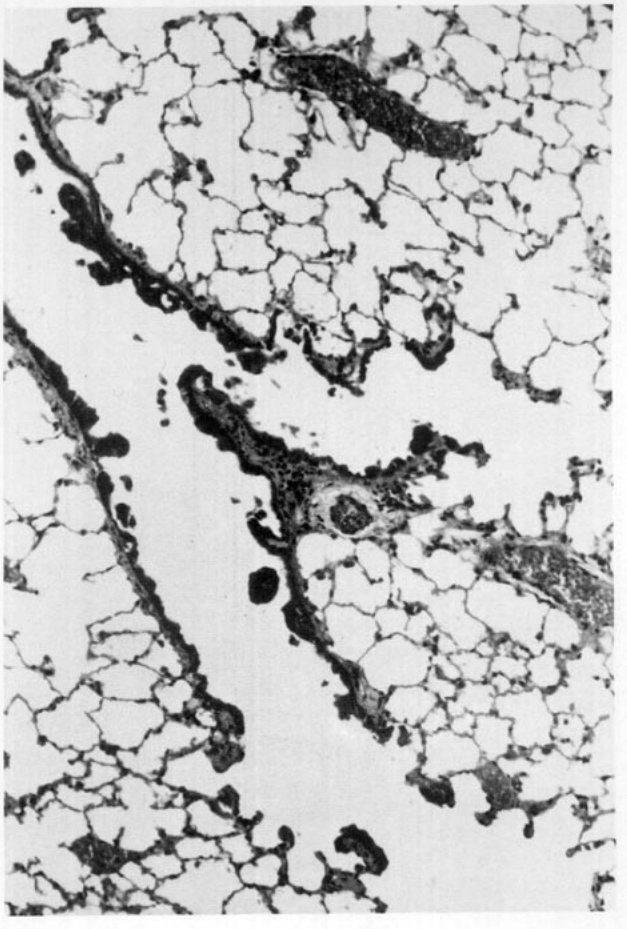

FIGURE 1. Terminal airway from a rat exposed to 4 ppm NO_2 for 18 months. Typical picture of continuous NO_2 exposure with hypertrophy and proliferation of the epithelium of terminal airway. ×40.

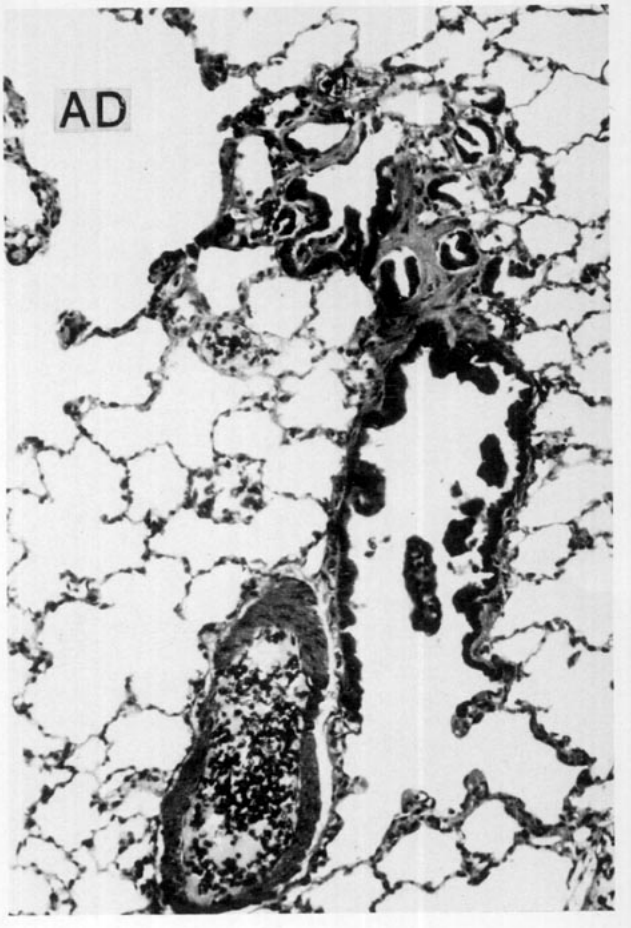

FIGURE 2. Terminal airway from a rat after exposure to 4 ppm NO_2 for 27 months. Hypertrophy and proliferation of the bronchial epithelium as well as thickened alveolar duct (AD) are remarkable. ×40.

± 0.04, and 4.0 ± 0.4 ppm) for 9, 18, and 27 months. One group served as a control. The exposure procedure and the time course of the survival of exposed animals in the present study were reported in detail previously by Sagai et al. (*22*). Three or four animals selected randomly from each group were used for morphological observation and electron microscopic morphometry.

Serological Examination. Serological testing such as complement binding response was conducted for the serum of all experimental rats at the time of the experiment in order to detect any trace of lung infection. A few animals showed an increase of antibody response to *B. bronchoseptica* and Sendai virus; the positive ratios for all experimental animals were 7.9 and 1.2%, respectively. Nevertheless, pathological changes induced by infection were not observed in the lungs of any animals. The indices of electron microscopic morphometry of the lungs of all control animals measured at each exposure time were within the normal range. These findings confirmed that no pathogenic microbes, including those causing respiratory infection, altered the lungs of rats used in this study.

Morphometry Procedure

Tissue Preparation. The thorax was opened under anesthesia with sodium pentobarbital. Ice-cold isotonic glutaraldehyde fixative (1.5% glutaraldehyde in 0.088 M cacodylate buffer at pH 7.4 with 1.5% dextran, osmolarity 330 mOsm) was dropped from a height of 20 cm and was instilled through a needle inserted in the trachea *in situ*, and at the same time depletion was accomplished by cutting the femoral artery. Subsequently, the lung was filled with the fixative and fully re-enlarged inside the opened thorax. When the inserted needle was withdrawn, the excess fixative overflowed, leaving the lung fixed at about 50% volume level of total lung capacity. Vertical slices of about 2 mm thickness through the hilar region of the lung were cut and fixed overnight in the same fixative. The slice was cut into 10 to 15 pieces and postfixed with 1% OsO_4 solution for 1 hr. Dehydration began with 70% alcohol; the tissue was then passed through propylene oxide and embedded in Epon 812.

The remaining portions of lung tissue were prepared

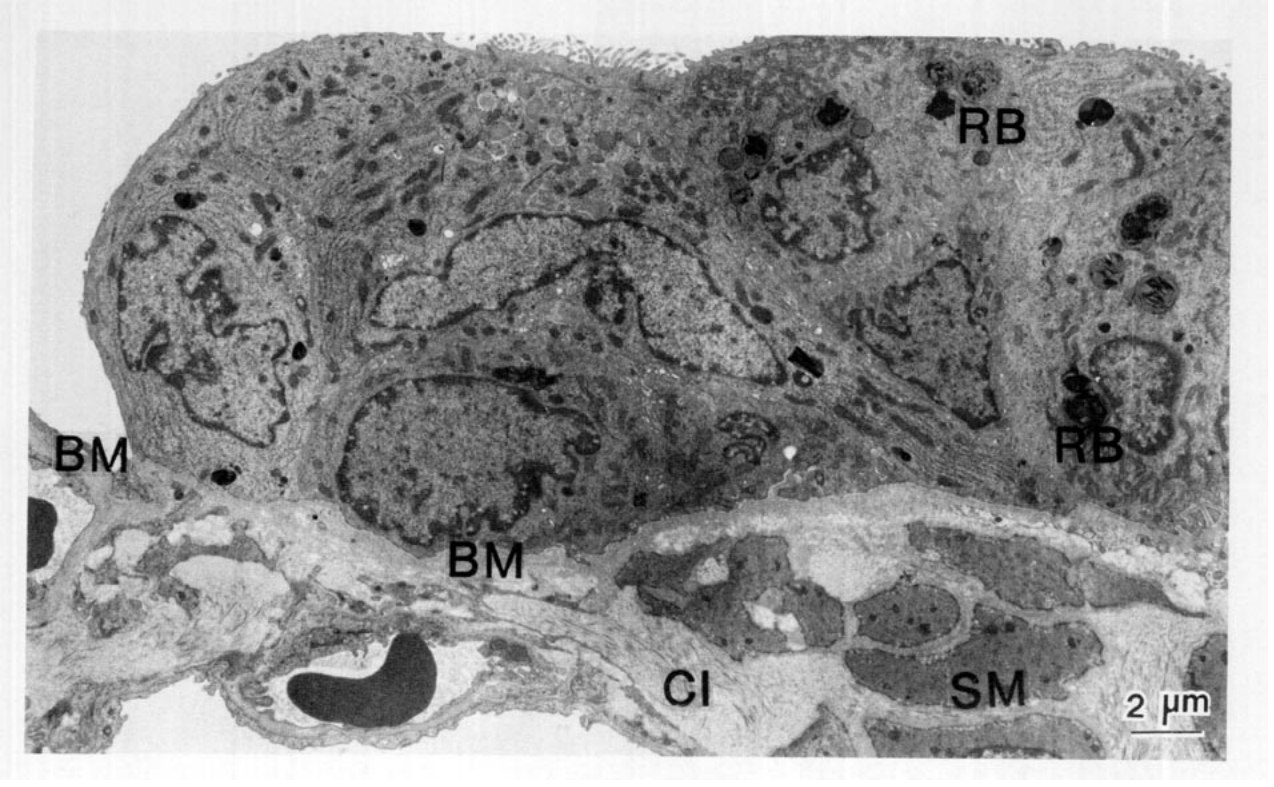

FIGURE 3. Tissue from the bronchial terminal after exposure to 4 ppm NO_2 for 27 months. Proliferation of nonciliated epithelium and increase of collagen (Cl) are remarkable. Moderate amounts of residual bodies (RB) with osmiophilic inclusions and lysosomes appeared in the cytoplasm of nonciliated epithelium. Prominent rough surface endoplasmic reticulum in the nonciliated epithelium coincided with enhanced basophilic staining with hematoxylin in light microscopic preparations. (SM) smooth muscle; (BM) basement membrane.

as paraffin-embedded sections for light microscopic observation.

Sampling for Electron Microscopic Morphometry. Lung sections from two rats of each group were used for electron microscopic morphometry. Sections of 1 μm thickness were cut from pieces of lung chosen randomly, stained with toluidine blue, and screened under a light microscope. Four blocks containing lung parenchyma wide enough for morphometric purposes were chosen. Thin sections were cut with a diamond knife, transferred onto the supporting grid (Maxtaform H_2), and stained with uranyl acetate and lead citrate.

As these sections covered 15 to 20 spaces of the supporting grid, the lung areas were systematically recorded on electron micrographs at initial magnification of × 2000 from the consecutive fields of grid corners, and 10 grid corners were used for counting.

Alveoli adjacent to the ends of the terminal bronchioles and to the small blood vessels were excluded from the counts, and alveoli at the more peripheral regions were subjected to measurement.

Morphometry. Electron micrographs were projected to a final magnification of ×8000 on a screen by the coherent multipurpose test system described by Weibel et al. (*15*), and the arithmetic mean thickness of the air-blood barrier (AMT) was measured. AMT was measured for 80 micrographs per group, consisting of 10 micrographs from four sections each of two experimental animals.

AMT was expressed without any correction for shrinkage or elongation factors in the course of sample preparation because the procedure used was the same for all groups observed (*20*).

Volume Density of Alveolar Wall Components (VdAWT). Volume density of each alveolar wall compartmental component was counted by the point counting method. A test sheet containing 293 cross points was placed on each micrograph and the number of points distributed on each component counted. Student's *t*-test for the mean of 80 micrographs and χ^2-test for the pooled sum of total points on each component of all 80 micrographs were applied to evaluate statistical significance.

Mean Number of Alveolar Cells and the Volume Density per Cell. A differential cell count was made of all cells of the alveolar wall with visible nuclei in 80 micrographs in each group. Comparison of cell numbers was made using the sum of cells per group appearing in a unit area of section used. Volume density per cell was calculated as the number of points per mean number of cells with visible nuclei found in the measured area.

Results

4 ppm NO_2

Typical morphological changes appeared in the lungs of rats exposed to NO_2 at 4 ppm for 9 months. The lesions were hypertrophy and hyperplasia of bronchial

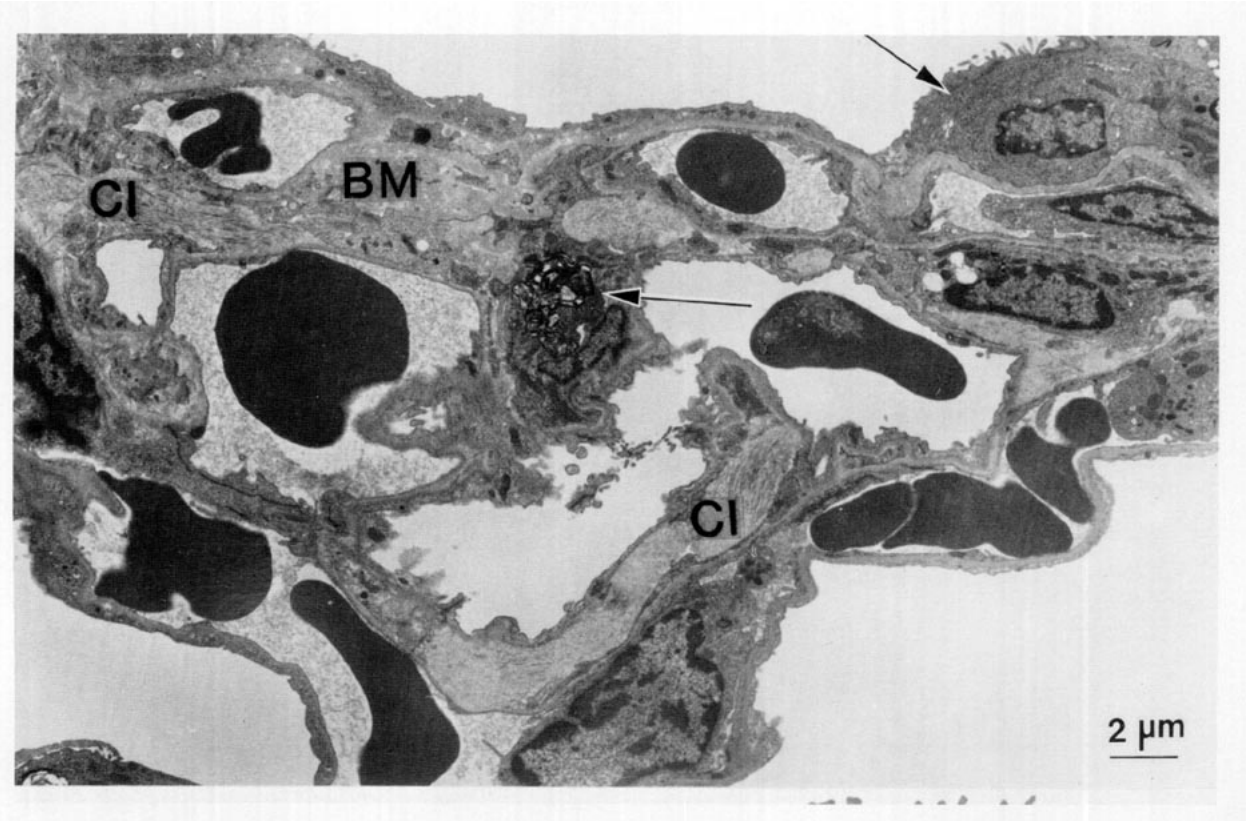

FIGURE 4. Tissue from a rat after exposure to 4 ppm NO_2 for 27 months. Proximal region of alveolar duct where the last cuboidal cell of respiratory bronchiole is seen at upper right (→). Note greatly thickened basement membrane (BM), as well as increase of collagen fibers (Cl). Osmiophilic inclusion appeared in an interstitial cell (←).

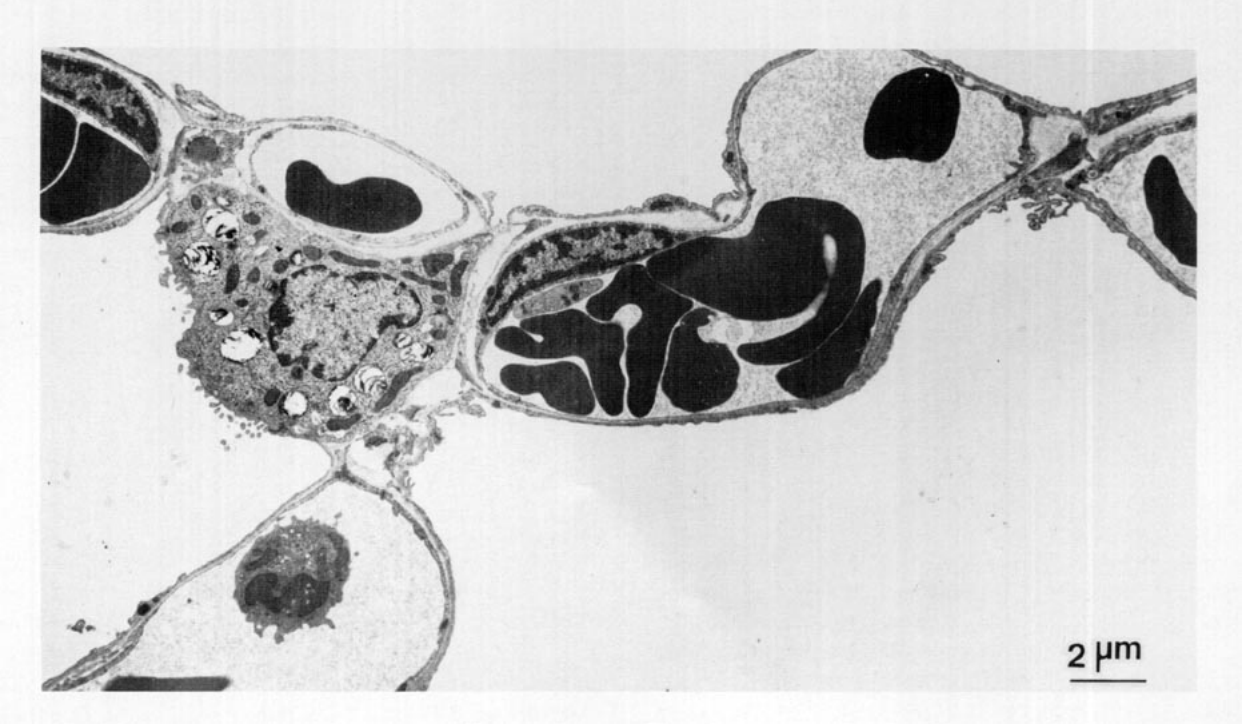

FIGURE 5. Alveolar wall from a 20-month-old rat (control for 18-month exposure). Note smooth surface of air-blood barrier and delicate thin layer of basement membrane.

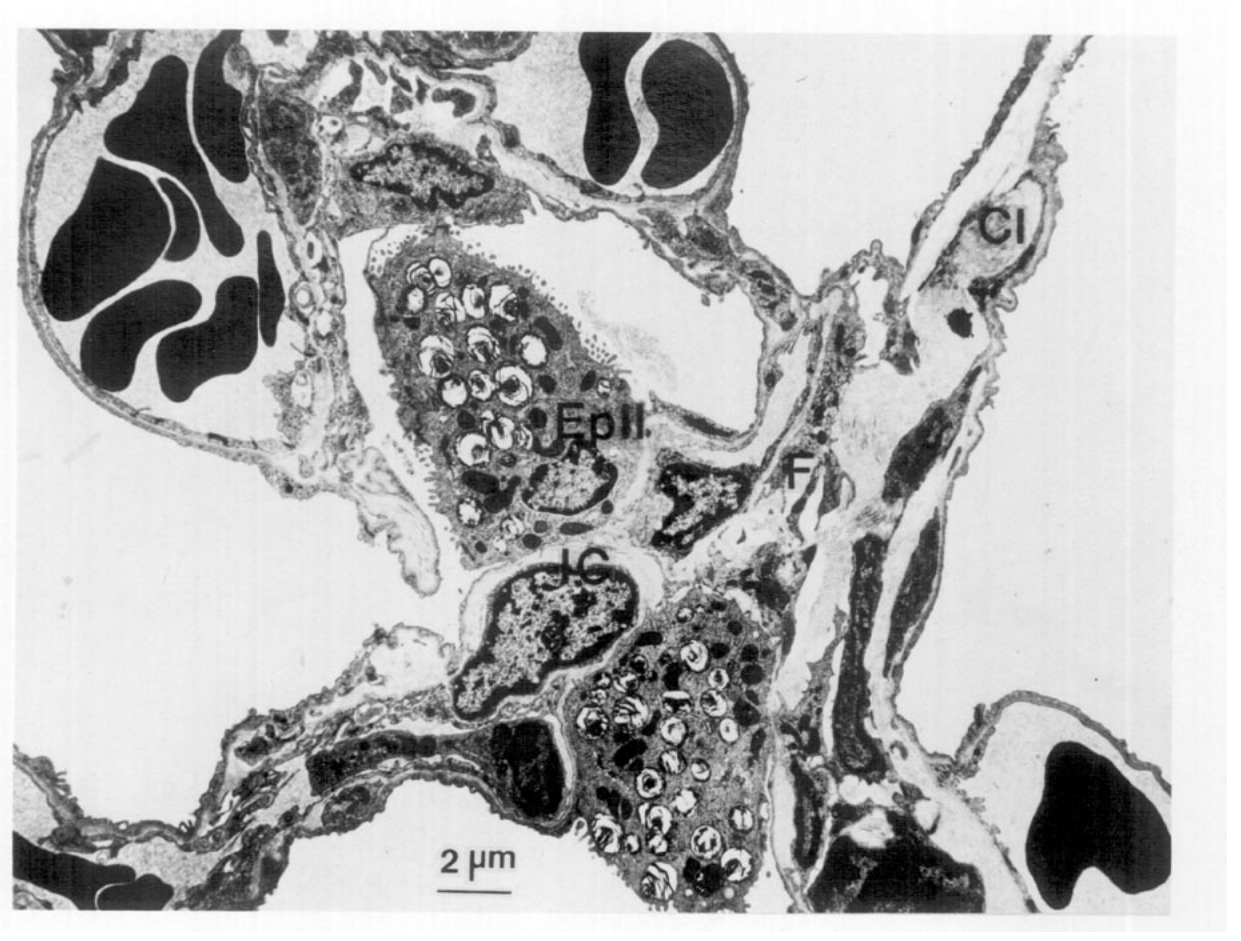

FIGURE 6. Alveolar wall from a rat that received 4 ppm NO_2 for 18 months. Increased number of alveolar cells are remarkable. Extended interstitium is filled with interstitial cells (IC), fibroblasts (F), and collagen fibers (Cl). Note also proliferation of type II epithelial cells (Ep 11) with abundant lamellar bodies.

mucosa, and thickening of walls in the area through the bronchopulmonary junction to the alveolar duct, with cell infiltration and increase of Clara cells. These findings have already been reported at various concentrations of NO_2 and are thought to be typical of NO_2 exposure. The lesions progressed according to the prolongation of exposure (Figs. 1 and 2).

After 27 months of exposure, morphological changes of bronchiolar mucosa remained on the same level as at 18 months; however, the lesions in the area from bronchopulmonary junction to the proximal alveoli progressed more severely, and the interstitial fibrosis and hyperplasia of epithelium seemed to progress steadily. Pathological changes in walls of the more peripheral alveoli were obscure, and the alveolar structure was maintained very well until 27 months of exposure, and no emphysema developed.

Electron microscopic observation proved that various components of alveolar wall changed depending on NO_2 concentration and exposure periods. The following findings were observed: hypertrophy of type I and type II cells, increase of cellular organella, increase of homogeneous matrix of interstitial tissue, polymorphic change of interstitial cells, increase of collagen fibers in the interstitium, and heterogenity of endothelium in the vasa. Intracellular edema, degeneration, and necrosis were seldom found. Appearance of macrophages and infiltration of inflammatory cells into the alveolar wall were not conspicuous throughout the inhalation period (Figs. 3–7).

Findings such as those described are too qualitative and local to give an understanding of to what extent and how the lesion developed. Morphometric quantification helps to elucidate the time-course image of pathological change and the concentration-dependent change clearly, in addition to facilitating an understanding of qualitative morphological alterations.

The time course of alveolar lesions seemed to show two phases: the first phase was from 9 to 18 months of exposure, and the second phase was from 18 to 27 months. Various kinds of tissue components increased in the first phase, but decreased in the second phase.

Phase 1. At 9 months, a decrease in cell number (Fig. 8*B*) and an increase in cell volume of type I epithelium (Fig. 8*C*) were observed. As a result of these changes, the comparative ratio of type II cell number to type I cell number increased (Fig. 9).

At 18 months, an increase of cell number (Fig. 10*B*)

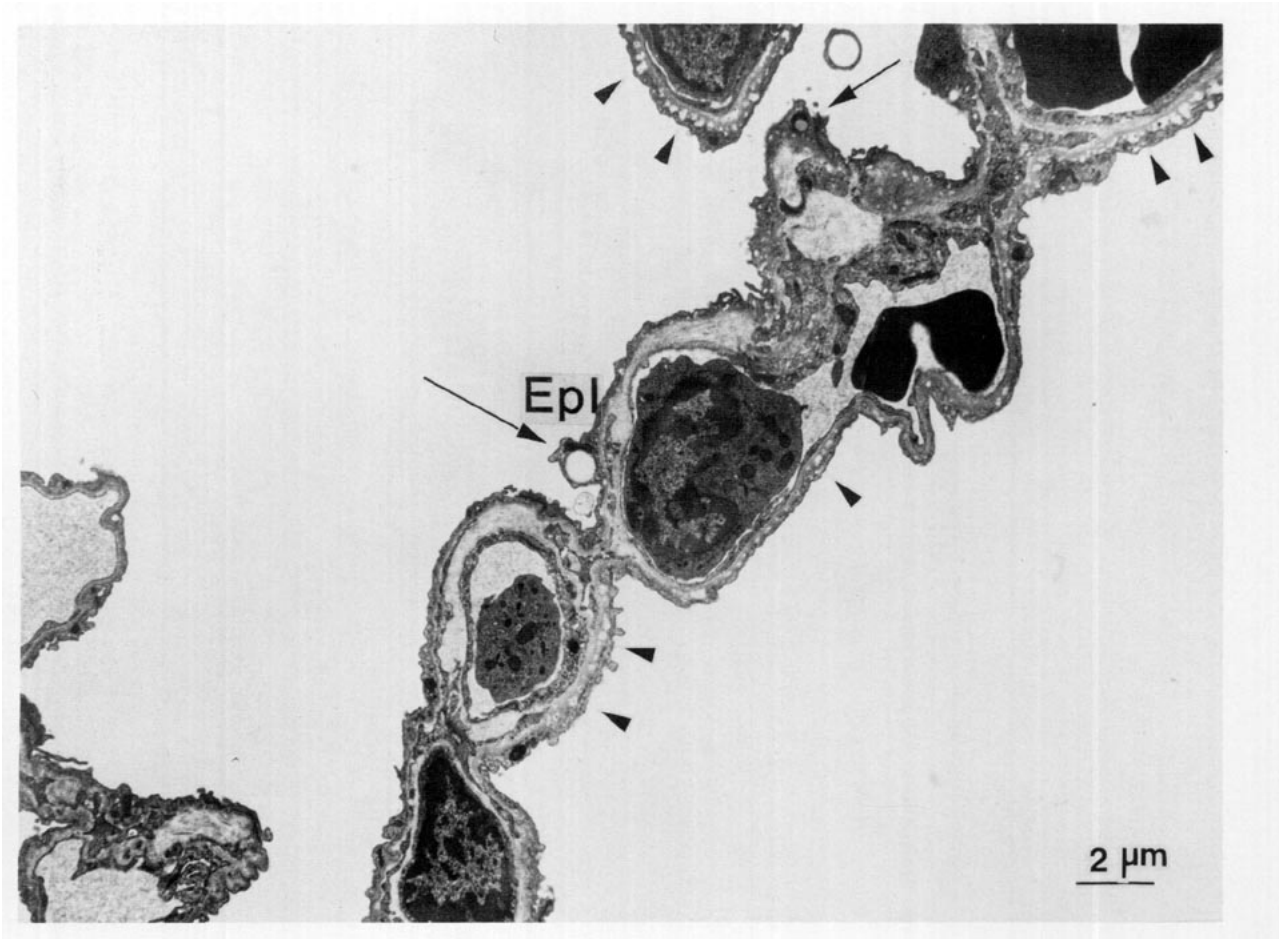

FIGURE 7. Alveolar wall from the peripheral region of alveolus after exposure to 4 ppm NO_2 for 18 months. Thickening of air-blood barrier is prominent compared with normal area at left side. Affected part of attenuated type 1 epithelium contains small vacuoles and vesicles (Ep 1 →). Electron lucent vesicular structure appeared in the basement membrane underlying this epithelium (▲).

and volume of type II cells (Fig. 10*C*), an increase of interstitium (Fig. 11), and a change in the endothelium were noticed. From these findings, it was assumed that at 4 ppm NO_2 exposure, the change of alveolar walls began as a change in type I cells and very slowly extended to type II cells and other cellular components. The lesions of bronchial mucosa appeared in the early stage of exposure, and the change of distal alveoli followed.

Phase 2. Electron microscopy showed evidence of recovery of the alveolar epithelium during months 18 to 27. However, the total volume of interstitial tissue, including either cellular or noncellular components, decreased (Fig. 11), and electron micrographs indicated that interstitial edema was replaced by collagen fibers (Fig. 12*A*,*B*).

The *de novo* synthesis of fiber in interstitium did not always mean complete recovery, and the possibility of functional disturbance was also suggested. Accordingly, the lesions of the alveolar wall were progressing to the next pathological phase during this period.

It is evident that the lesions of the alveolar wall progressed very slowly under long-term exposure to 4 ppm NO_2. Some of the lesions of the alveolar epithelium appeared to be repaired, whereas other lesions of the interstitium were always progressive.

0.4 ppm

The lesion was generally milder than 4 ppm, and the initial time was delayed. The morphological change of bronchiolar epithelium, bronchopulmonary junction, and alveolar walls was detectable at 18 months by electron microscopy (Fig. 13), but no definite morphological change was discerned by light microscopy until month 27.

As evidenced by morphometric indices, AMT (Table 1, Fig. 14*A*,*B*) and various indicators concerning interstitium (Fig. 11) increased according to exposure time. Interestingly, alveolar epithelium showed a tendency toward recovery at 27 months in the same pattern as at the 4 ppm level (Figs. 8–10).

The lesions at the 0.4 ppm level corresponding to the first phase at 4 ppm progressed very slowly, and the degree of the alteration was emphasized with time, though the degree of alteration was slight. After a fully prolonged exposure period, the typical pathological lesion was seen.

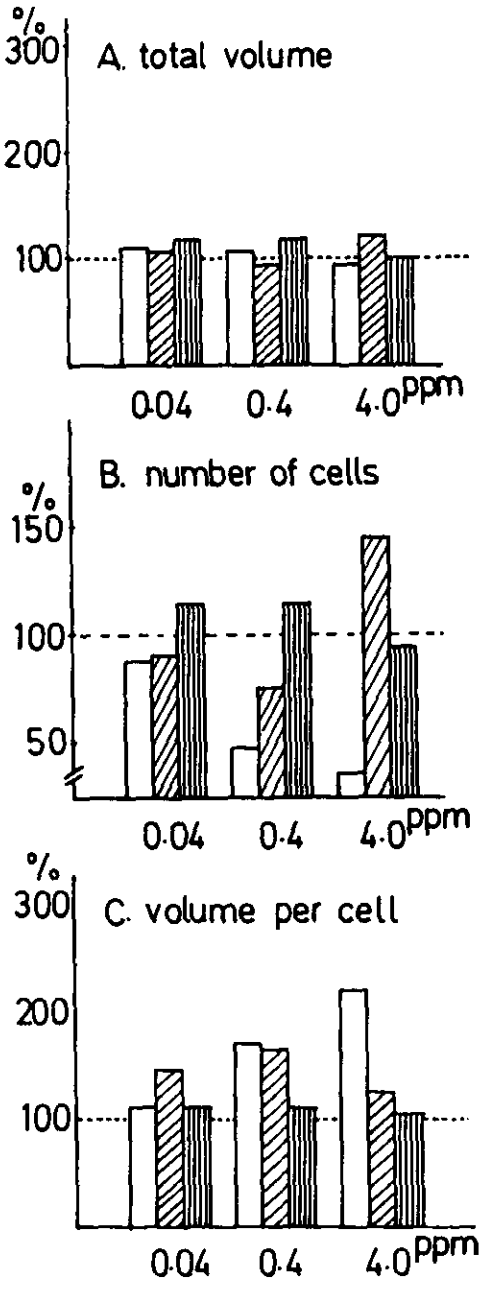

FIGURE 8. Changes in type I epithelium of the alveolar wall in NO_2-exposed rats. (□ = 9-month exposure; ▨ = 18-month exposure; ▥ = 27-month exposure.) (*A*) Total cell volume; (*B*) number of cells; (*C*) volume per cell, or *A* divided by *B*. All values are expressed as percentage of exposed group to corresponding control values.

0.04 ppm

The difference of morphological findings between the control group and the 0.04 ppm-exposed group from 9 to 27 months could not be determined by light and electron microscopy. However, morphometric indices showing the tendency of increment of AMT (Table 1, Fig. 14*A*,*B*), interstitial components (Figs. 11 and 15), and the pattern of variation of alveolar type II cells (Fig. 10) depending on exposure period suggested that reactions similar to those at the 0.4 ppm level were expressed in a milder form.

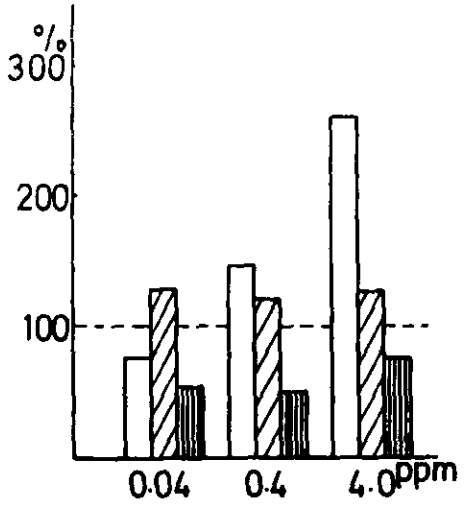

FIGURE 9. Numerical ratio of type II cells to type I cells of the alveolar wall in NO_2-exposed rats. (□ = 9-month exposed; ▨ = 18-month exposed; ▥ = 27-month exposed.)

Discussion

Effects of Chronic NO_2 Exposure

Morphological findings in rats chronically exposed to NO_2 were summarized in the "Introduction." The character of lesions, particularly of 4 ppm groups, was the same as reported in other studies (*3–5,8,10*). At the 4 ppm level or lower, we could not find any sign of inflammatory cell infiltration or enlargement of the lymphatic system, or emphysema.

Freeman et al. (*5*) and Stephens et al. (*7,23*) indicated that typical lesions occurred in rats exposed to 2 ppm NO_2 for 2 years. Compared with these results (*5,7,23*), the lesions induced by 4 ppm were more severe. Furiosi et al. (*24*) also found hypertrophy of bronchial epithelia in rats exposed to 2 ppm for 425 days. Evans et al. (*10*) reported that exposure to 1 to 2 ppm for life clearly induced lesions of the epithelial lining of the airway, although these lesions were not as severe.

Little work has been done on the effects of chronic exposure to 2 ppm or less. Wagner et al. (*25*) reported that they could not gain any positive results from several species of rodents, including rats and mice, exposed intermittently to 1 ppm for 6 hr/day or 5 days/week for 18 months. Their histological description also included some inflammatory changes common to both experimental and control groups. Exposure to 0.8 ppm for 33 months occasionally induced slight morphological alterations in the small bronchiolar epithelia, but the result was evaluated to be negative on the whole (*4*). Blair (*26*) observed the emphysematous hyperextension of alveoli and the thickening of alveolar wall in the mouse exposed to 0.5 ppm for as long as 12 months. However,

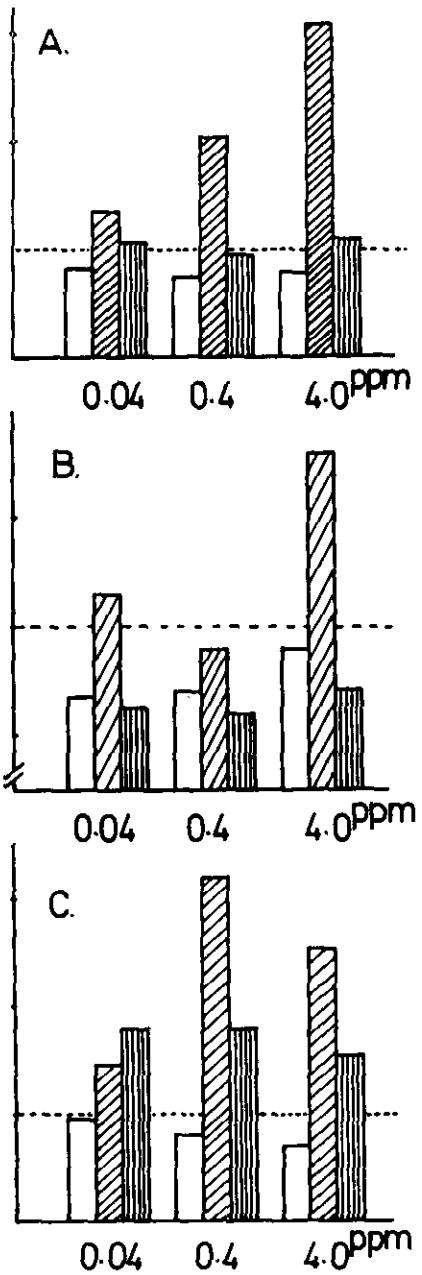

FIGURE 10. Changes in type II epithelium of the alveolar wall in NO_2-exposed rats. (□ = 9-month exposed; ▨ = 18-month exposed; ▥ = 27-month exposed.) (*A*) Total cell volume; (*B*) number of cells; (*C*) volume per cell, or *A* divided by *B*. All values are expressed as percentage of exposed group to corresponding control values.

lack of the typical lesion induced by NO_2, appearance of pneumonia, and inflammatory changes require prudent interpretation.

Port et al. (*27*) exposed mice to 0.1 ppm NO_2 with a 2 hr peak of 1 ppm NO_2 daily for 6 months. The emphysematous changes in the lung were dilated respiratory bronchioles and alveolar ducts. Tissue destruction appeared and numerous broken and/or stretched

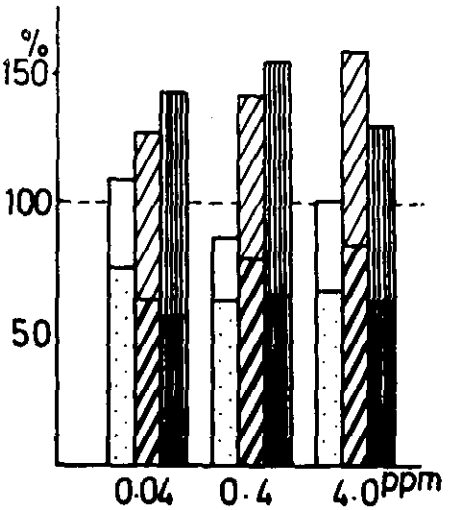

FIGURE 11. Total volume of interstitium in NO_2-exposed rats. (⊡ = 9-month exposed; ▨ = 18-month exposed; ▥ = 27-month exposed.) The upper portion of the bar represents noncellular elements; the lower portion represents cellular elements.

alveolar septa were seen with the scanning electron microscope. Yamamoto et al. (*28*) exposed rats to 0.5 ppm and 1.0 ppm of NO_2 for 7 months. Changes in cilia included swelling (0.5 ppm) and a decrease in number, or loss (1.0 ppm). They also observed hyperplasia of type II cells (0.5 and 1.0 ppm), decrease in number of lamellar bodies in type II cells (1.0 ppm), and interstitial edema of alveolar walls (1.0 ppm).

In the present study, at 0.4 ppm, the slight degree of morphological alterations appeared later than 18 months and extended to the typical lesion at 27 months. From these results, it was assumed that NO_2 exposure to 0.4 ppm or more should certainly induce definite injury to the lung tissue under long enough exposure periods.

Initial Lesions

In addition to long-term exposure at low levels, there were some reports about lesions induced by low level exposure for 2 or 3 months. Nakajima et al. (*29*) noticed the proliferation of the terminal bronchiolar epithelia and edematous swelling of alveolar epithelia in the lungs of mice exposed to 0.5 to 0.8 ppm for 1 to 1.5 months. Crapo et al. (*30*) exposed rats to 2 ppm NO_2 for 23 hr/day with twice daily spikes of 6 ppm for 30 min each for 6 weeks. Both the increased number and increased thickness of alveolar type I cells were demonstrated morphometrically. A 10 to 15% increase was found in both interstitial cells and interstitial matrix. The number of alveolar type II cells increased by about 40%.

Kyono and Kawai (*19*) clearly detected the typical lesions in lungs of rats exposed to 3 ppm or more for 1 month and the slight morphological alterations of bronchial epithelia and thickening of the alveolar wall at 0.5 ppm.

Terada et al. (*31*) exposed rats to 0.3 to 8 ppm NO_2

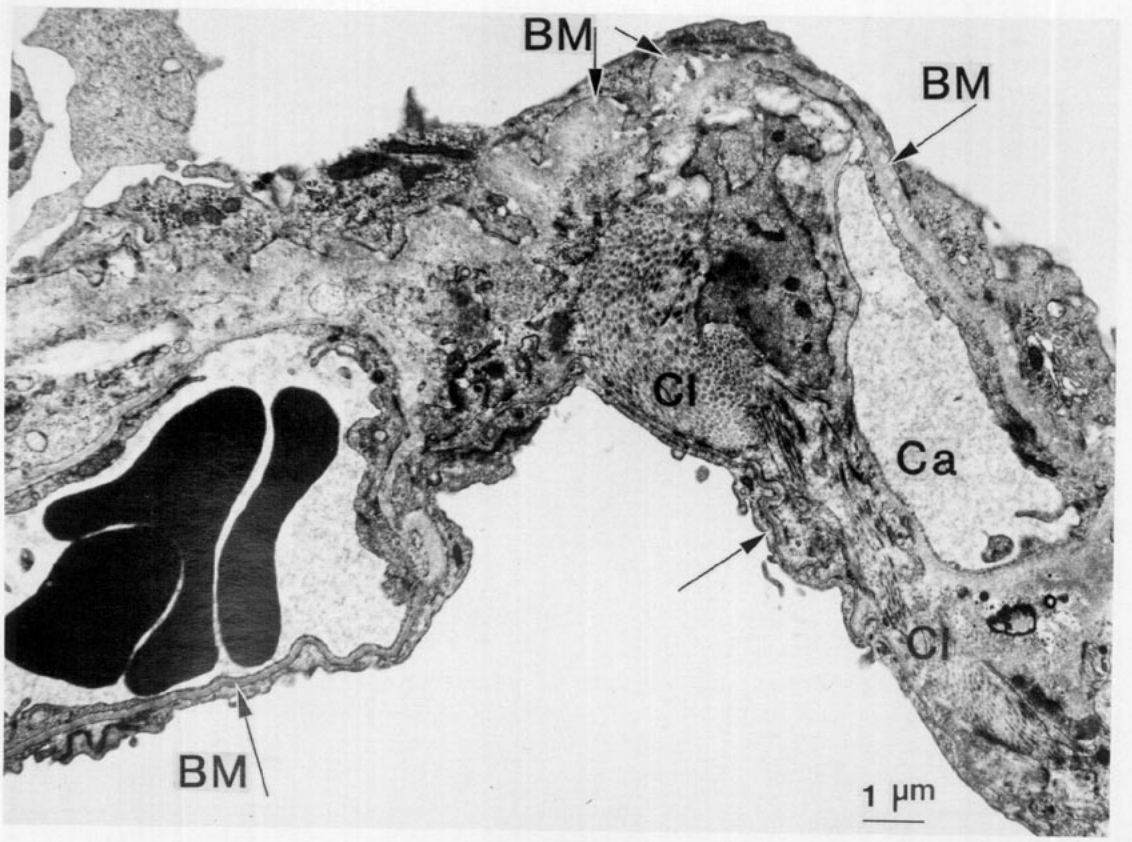

A

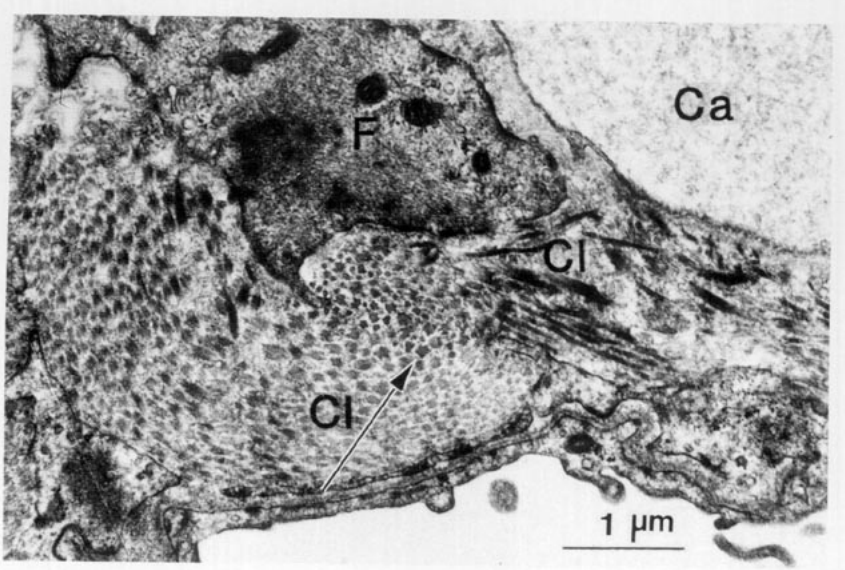

B

FIGURE 12. Alveolar wall from the peripheral alveolar region of a rat that received 4 ppm NO_2 for 27 months. (*A*) An area of interstitial lesion with extraordinary varied thickness of basement membrane (BM) and deposition of very large collagen fibrils (Cl). Greatly thickened air-blood barrier and reduced size of capillary lumen (Ca) are remarkable. (*B*) Note stellate appearance of some of the collagen fibrils (→) in cross section. Collagen fibrils about two to three times the diameter of normal size fibrils (300 Å) can be seen. (F) fibroblast; (Ca) capillary lumen.

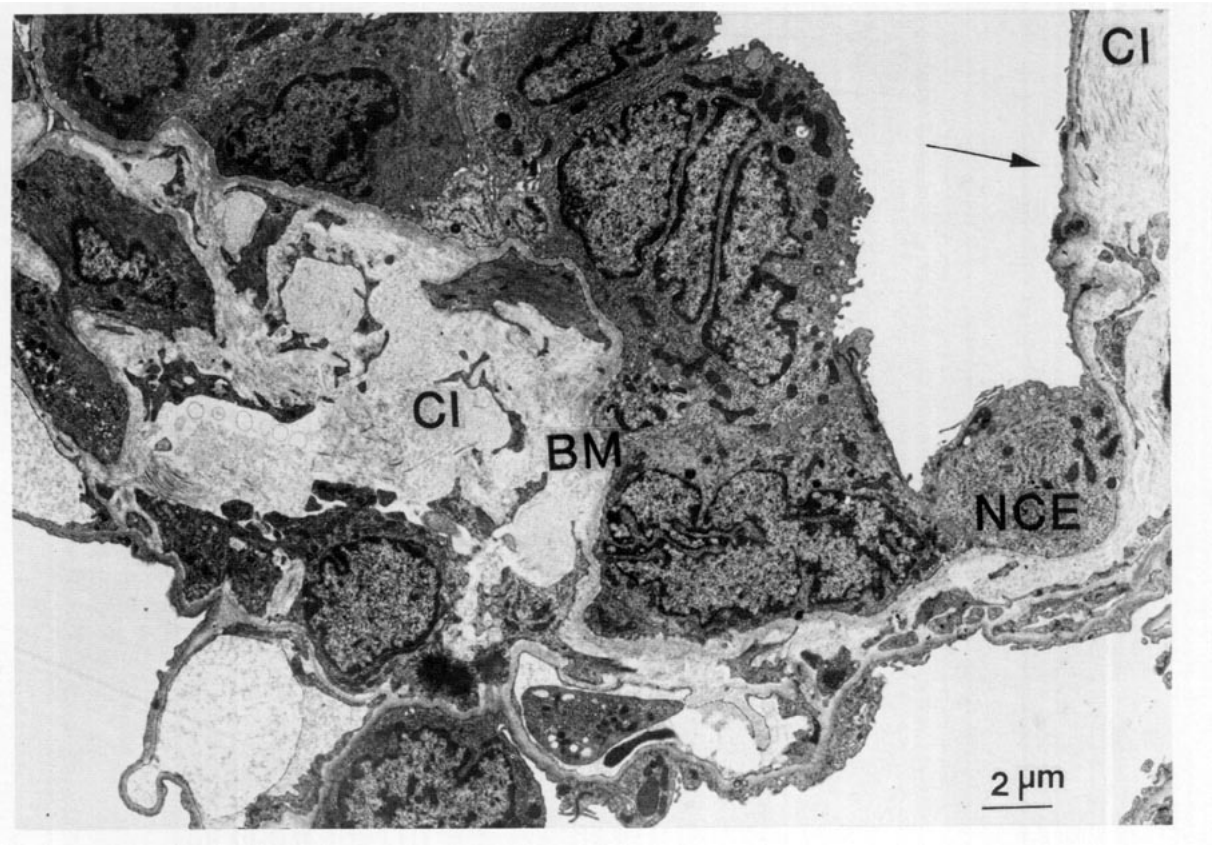

FIGURE 13. Electron micrograph of the terminal airway after exposure of a rat to 0.4 ppm NO_2 for 27 months. Enlarged and abnormally segmented nuclei of bronchiolar epithelia. Note extended submucosal connective tissue and greatly increased collagen fibers (Cl) at alveolar duct (→), which followed the last nonciliated epithelial cell of respiratory bronchiole (NCE). (BM) basement membrane.

Table 1. Arithmetic mean alveolar wall thickness in rats exposed long term to NO_2.[a]

NO_2 concentration	Duration of exposure		
	9 months	18 months	27 months
Control	1.41 ± 0.15 (100)	1.29 ± 0.13 (100)	1.33 ± 0.16 (100)
0.04 ppm	1.43 ± 0.14 (100.9)	1.33 ± 0.15 (103.6)	1.55 ± 0.18 (116.5)
0.4 ppm	1.39 ± 0.14 (98.2)	1.44 ± 0.16 (111.9)	1.82 ± 0.19* (136.7)
4.0 ppm	1.50 ± 0.18 (105.8)	1.71 ± 0.16* (133.1)	1.57 ± 0.20 (118.0)

[a]Values for mean alveolar wall thickness are expressed as μm ± SE. Numbers in the parentheses are percent of the corresponding control values.

*Statistically significant to the corresponding control values ($p < 0.001$).

for 1 week to 18 months. They reported that the lesions in the middle-sized bronchi appeared at 1 week at the 4 or 8 ppm level, at 3 weeks at 2 ppm, and at 4 weeks at 0.5 ppm NO_2. The locus of the lesion extended toward the distal airways as exposure time was prolonged.

These positive results from low-level exposure for a short term suggest that the response of the lung tissue at even the 0.5 ppm level should appear at a relatively early time after exposure.

Recovery of Lesions

In our second experiment (*32*), rats were exposed to 0.04 to 0.4 ppm for 3 to 18 months. The very weak responses, i.e., reduction of the number of extruded cell and mild hypertrophy of the terminal bronchiolar lining, continued throughout the exposure periods. The responses that appeared in the lung at 3 or 18 months were stronger than those at 6 or 9 months. The responses after 6 or 9 months seemed to be weaker than those at 3 months; therefore, the degree of respiratory lesions in these periods did not correlate with the total cumulative dose of concentration and time. Lesions caused directly by NO_2 concentration were observed, as well as lesions due to the aging of animals. Animals maintained adequate level of responses, which were affected by acquired tolerance under continuous low doses of exposure.

Terada et al. (*31*) reported the typical mild alterations of the epithelium in the middle to terminal region of the bronchial tree of rats at 0.5 ppm level after 18 months in a chronic inhalation experiment of NO_2 ranging from 0.3 to 1.0 ppm. Their results show a weak positive response, but not a definite NO_2-caused lesions at 0.3 ppm at 3 or 18 months, although the alterations became weaker after 6 to 12 months. Our findings are fundamentally in accord with these results.

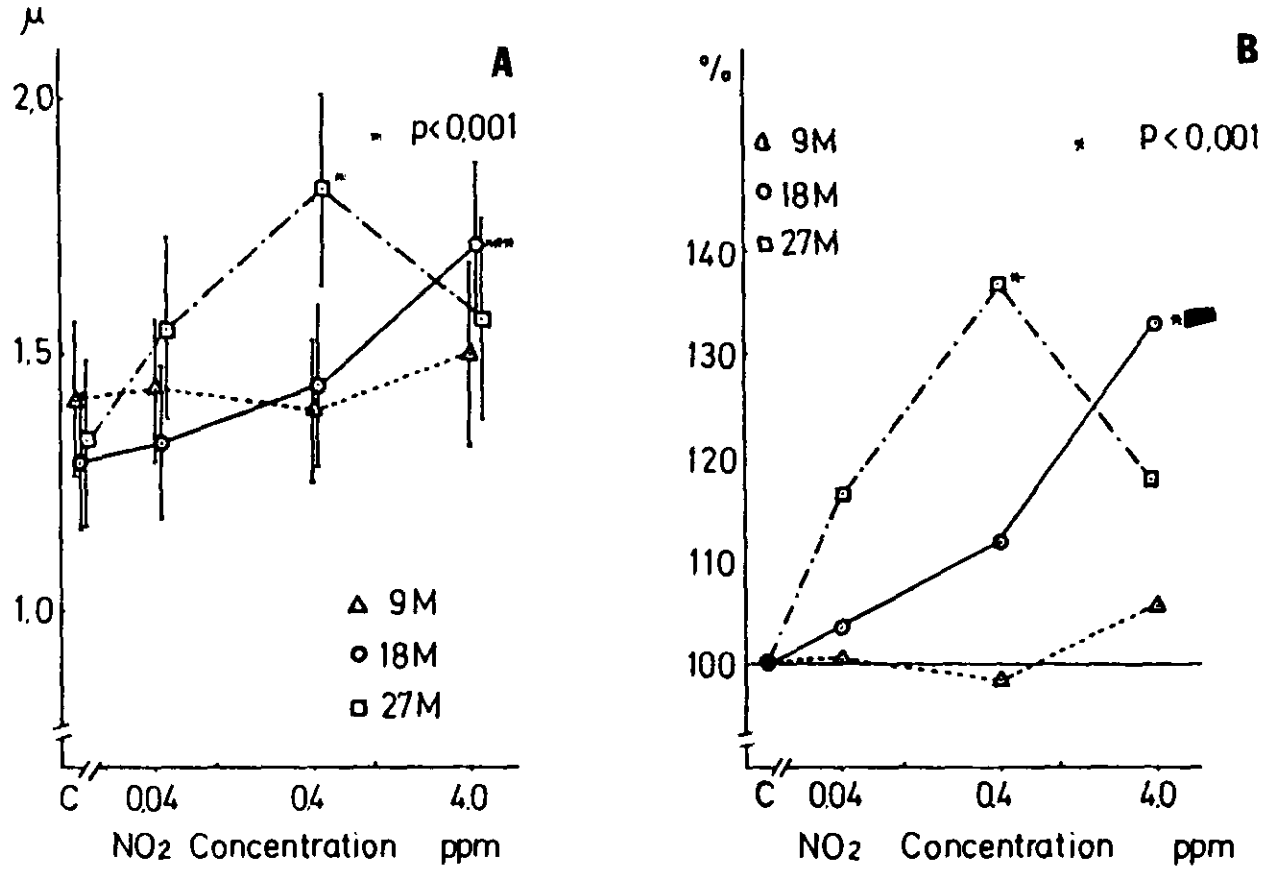

FIGURE 14. The values of AMT were measured by Weibel's method (Table 1), and the increase of AMT is presented as percentage of control. (*A*) Arithmetic mean thickness of alveolar wall. (*B*) Relative changes in alveolar thickness as compared with corresponding control values.

The response process of alveolar epithelium under the continuous long-term exposure to NO_2 is a good example for analyzing the passage of lesions induced by NO_2. Impaired type I alveolar epithelial cells were necrotized, desquamated, and replaced by the regenerated type II cells shortly after the onset of NO_2 exposure (*9,10,33–36*). In long-term exposure at 2 ppm and 0.5 ppm (*37*), the same phenomena in the alveoli were reported (*8*). It is accepted that once these mechanisms have started, the newly repaired epithelium shows tolerance to NO_2 (*10*).

In our present long-term study, the same phenomena seemed to occur, and transformation of proliferated type II cells into type I cells continued very gradually during 27 months. On the other hand, the lesions of the bronchopulmonary junction and of alveolar interstitium were progressive, and thus accumulated gradually with prolonged exposure.

The results of chronic exposure clearly indicate that the degrees of respiratory lesions induced by NO_2 were parallel to the concentration of NO_2 and progressed according to prolongation of exposure.

Recovery at NO_2 Exposure of 0.4 ppm or Less. Information was rarely available concerning the effects of NO_2 on animals exposed continuously for a long time at a concentration under 0.4 ppm. Hasegawa et al. (*38*) found changes of some biochemical indices such as the increase of blood glutathione level in rats exposed to 0.12 ppm for 1 month. Using part of the same specimens, Kyono and Kawai (*19*) observed a trend of increase in morphometric indices such as AMT. As the same result was obtained when the experiment was repeated, a completely negative effect of NO_2 at 0.12 ppm was not excluded. If the values of these morphometric indices increased as exposure time increased, definite lesions would be expected.

The tendency of gradual increase of morphometric indices found at 0.04 ppm level in the present experiment was insignificant; however, it should be noted that the trend was also observed in 0.4 or 0.12 ppm level. This trend should be considered and investigated much more intensively.

Aging and Lesions. One of the important results in the present study was the relationship between the progress of lesions and the aging of animals. Between 18 and 27 months, the lesions at the 0.4 ppm level became distinct, and some of the morphometric indices at 0.04 ppm increased similarly.

Cabral-Anderson et al. (*42*) and Evans et al. (*35*) studied the relationship between aging and the progression of lung injuries induced by NO_2 exposure. Aged rats were more damaged than younger rats because of the delayed onset of repair function to the initial injury; however, older rats acquired similar tolerance to NO_2

FIGURE 15. Alveolar septa from the peripheral alveolar region after exposure of a rat to 0.04 ppm NO_2 for 27 months. An increased incidence of slightly thickened air-blood barrier (→) supports accumulation of minute changes in the alveolar wall. Electron lucent edematous space and collagen fibers appear in the interstitium.

after the repair system was activated. The lung response of 25-month-old rats was as high as that of 1-month-old rats.

Age-related differences in sensitivity to NO_2 have been noted recently (*39,40*). It has been reported that lung impairment in neonatal mice and rats is slight, while sensitivity increases in young adult animals (*41*). Also, the onset of cell repair is slower in older rats (*35,42*). However, little is known about the relationship between the age of animals and effects on the lung of lower concentrations of NO_2 (< 1 ppm) and NO_2 at ambient air pollution levels.

Kyono and Kawai (*19*) performed electron microscopic morphometry on the alveolar wall (excluding the alveolar ducts) on the lungs of 1, 3, 12, and 21-month-old rats exposed to 0.1 to 10 ppm NO_2 continuously for 1 month. The response of lung tissue to NO_2 exposure showed age-related differences at exposure onset. Based on the morphometric index, the reactivity was highest in the 1-month-old and decreased in order in the 3- and 12-month-old, but increased again in the 21-month-old rats. They reported that volume density of alveolar wall tissue and surface area of alveoli and capillary lumen of the groups (except for 12-month-old rats exposed to 0.1 and 0.5 ppm for 1 month) differed significantly from control groups, which meant the increase of AMT.

Judging from these findings, aging probably has a close relationship to susceptibility to NO_2 in rats. Middle-aged rats generally responded weakly to NO_2, but older rats responded strongly. It is fully expected that the lesions induced by low concentrations of NO_2 become stronger and that qualitative alterations may occur after 18 months due to the modified susceptibility with aging.

Some changes in connective tissue in lung and slight enlargement of alveoli were noted in rats after chronic exposure to NO_2 (*23,43*). How and to what extent does the continuous exposure to low level of NO_2 accelerate the age-dependent thickening or fibrogenesis of alveolar wall? These problems as a causative factor of emphysema (*44*) in animals with a far longer life-span than rats remains to be determined.

The authors thank Fujio Shimizu, Yasuko K. Yamada, Junzo Saegusa, and Takahiko Harada for their valuable help and discussion during the experiments. Also, thanks are due to Ryoko Kawamura, Yoshiko Sawada, Satoko Shimizu, Yoshiko Shinbo, and Kazumi Kano for their technical assistance.

REFERENCES

1. Coffin, D. L., and Stokinger, H. E. Biological effects of air pollutants. In: Air Pollution, Vol. II (A. C. Stern, Ed.), Academic Press, New York, 1977, pp. 231–360.
2. World Health Organization. Environmental Health Criteria 4:

Oxides of Nitrogen. United Nations Environment Programme and the World Health Organization, Geneva, Switzerland, 1977.
3. Freeman, G., and Haydon, G. B. Emphysema after low-level exposure to NO_2. Arch. Environ. Health 8: 133–136 (1964).
4. Freeman, G., Furiosi, N. J., and Haydon, G. B. Effects of continuous exposure of 0.8 ppm NO_2 on respiration of rats. Arch. Environ. Health 13: 454–456 (1966).
5. Freeman, G., Stephens, R. J., Crane, S. C., and Furiosi, N. J. Lesion of the lung in rats continuously exposed to two parts per million of nitrogen dioxide. Arch. Environ. Health 17: 181–192 (1968).
6. Haydon, G. B., Freeman, G., and Furiosi, N. Covert pathogenesis of NO_2 induced emphysema in the rat. Arch. Environ. Health 11: 776–783 (1965).
7. Stephens, R. J., Freeman, G., Crane, S. C., and Furiosi, N. J. Ultrastructural changes in the terminal bronchioles of the rat during continuous, low-level exposure to NO_2 (ciliogenesis). Exp. Mol. Pathol. 14: 1–19 (1971).
8. Stephen, R. J., Freeman, G., and Evans, M. T. Early response of lungs to low levels of nitrogen dioxide. Arch. Environ. Health 24: 160–179 (1972).
9. Evans, M. J., Stephens, R. J., Cabral, L. J., and Freeman, G. Cell renewal in the lung of rats exposed to low levels of NO_2. Arch. Environ. Health 24: 180–188 (1972).
10. Evans, M. J., and Freeman, G. Morphological and pathological effects of NO_2 on the rat lung. In: Nitrogen Oxides and Their Effects on Health (S. D. Lee, Ed.), Ann Arbor Science, Ann Arbor, MI, 1980, pp. 243–265.
11. Juhos, L. T., Green, D. P., Furiosi, N. J., and Freeman, G. A quantitative study of stenosis in the respiratory bronchiole of the rat in NO_2-induced emphysema. Am. Rev. Respir. Dis. 121: 541–549 (1980).
12. Sherwin, R. P., Margolick, J. B., and Azen, S. P. Hypertrophy of alveolar wall cells secondary to an air pollutant. Arch. Environ. Health. 26: 297–299 (1973).
13. Haydon, G. B., Davidson, J. T., Lillington, G. A., and Wasserman, K. Nitrogen dioxide-induced emphysema in rabbits. Am. Rev. Respir. Dis. 95: 797–805 (1967).
14. Kleinerman, J. Some effects of nitrogen dioxide on the lung. Fed. Proc. 36(5): 1714–1718 (1977).
15. Weibel, E. R., Kistler, G. S., and Scherle, W. F. Practical stereological methods for morphometric cytology. J. Cell Biol. 30: 23–38 (1966).
16. Weibel, E. R. Stereological techniques for electron microscopic morphometry. In: Principles and Techniques of Electron Microscopy (M. A. Hayat, Ed.), Van Nostrand Reinhold Co., New York, 1973, pp. 237–291.
17. Kyono, H., Koshi, S., and Kawai, K. Electron microscopic morphometry of minute reaction of the lung. Conf. Jpn. Soc. Air Pollut. :432 (1973).
18. Kyono, H., and Kawai, K. Electron microscopic morphometry of the lung. (2) NO_2-inhaled rat lung. Conf. Jpn. Soc. Air Pollut. 220 (1977).
19. Kyono, H., and Kawai, K. Morphometric study on age-dependent pulmonary lesions in rats exposed to nitrogen dioxide. Ind. Health 20: 73–99 (1982).
20. Kawai, K., and Kyono, H. Morphological studies. In: Inhalation Experiments. Its Application to Atmospheric Pollution Research (K. Kawai and E. Yokoyama, Eds.), Soft Science, Inc., Tokyo, 1979, pp. 407–436.
21. Takenaka, S., Shimizu, F., Yamada, Y., Horiuchi, H., Imai, T., Harada, T., Kyono, H., and Kawai, K. Effects of long-term nitrogen dioxide exposure on rats—morphological observation. Res. Rep. Natl. Inst. Environ. Stud. 15: 171–227 (1980).
22. Sagai, M., Ichinose, T., and Kubota, K. Studies on the biochemical effects of nitrogen dioxide, IV. Relation between the change of lipid peroxidation and antioxidative protective system in rat lungs upon life span exposure to low levels of NO_2. Toxicol. Appl. Pharmacol. 73: 444–456 (1984).
23. Stephens, R. J., Freeman, G., and Evans, M. J. Ultrastructural changes in connective tissue in lungs of rats exposed to NO_2. Arch. Intern. Med. 127: 873–883 (1971).
24. Furiosi, N. J., Crane, S. C., and Freeman, G. Mixed sodium chloride aerosol and nitrogen dioxide in air. Arch. Environ. Health 27(12): 405–408 (1973).
25. Wagner, W. D., Duncan, B. R., Wright, P. G., and Stokinger, H. E. Experimental study of threshold limit of NO_2. Arch. Environ. Health 10(3): 455–466 (1965).
26. Blair, W. H., Henry, M. C., and Ehrlich, R. Chronic toxicity of nitrogen dioxide. 2. Effect on histopathology of lung tissue. Arch. Environ. Health 18: 186–192 (1969).
27. Port, C. D., Ketels, K. V., Coffin, D. L., and Kane, P. A comparative study of experimental and spontaneous emphysema. J. Toxicol. Environ. Health 2: 589–604 (1977).
28. Yamamoto, I., and Takahashi, M. Ultrastructual observations of rat lung exposed to nitrogen dioxide for 7 months. Kitasato Arch. Exp. Med. 57(1): 57–65 (1984).
29. Nakajima, T., Oda, H., Kusumoto, S., and Nogami, H. Biological effects of nitrogen dioxide and nitric oxide. In: Nitrogen Oxides and Their Effects on Health (S. D. Lee, Ed.), Ann Arbor Science, Ann Arbor, MI, 1980, pp. 121–141.
30. Crapo, J. D., Barry, B. E., Chang, L. Y., and Mercer, R. R. Alterations in lung structure caused by inhalation of oxidants. J. Toxicol. Environ. Health 13(213): 301–321 (1984).
31. Terada, N., Suzuki, T., Ohsawa, M., Fukuda, M., Mizoguchi, I., and Kawai, K. Pathological changes in the lungs of rats exposed to nitrogen dioxide. Ann. Rep. Tokyo Metr. Res. Lab. P.H. 32(1): 250–256 (1981).
32. Kyono, H., Saegusa, J., Kawai, K., Yamada, Y., and Kubota, K. Effects of long-term nitrogen dioxide exposure on rats, morphological observations. Res. Rep. Natl. Inst. Environ. Stud. 40: 195–219 (1983).
33. Langloss, J. M., Hoover, E. A., and Kahn, D. E. Diffuse alveolar damage in cats induced by nitrogen dioxide or feline calicivirus. Am. J. Pathol. 89(3): 637–648 (1977).
34. Hackett, N. A. Cell renewal of chinese hamster lung and trachea following NO_2 exposure. Am. Rev. Respir. Dis. 117(4), part 2: 237 (1978).
35. Evans, M. J., Cabral-Anderson, L. J., and Freeman, G. Effects of NO_2 on the lungs of aging rats. II. Cell proliferation. Exp. Mol. Pathol. 27: 366–376 (1977).
36. Evans, M. J., Cabral-Anderson, L. J., and Freeman, G. Role of the Clara cells in renewal of the bronchiolar epithelium. Lab. Invest. 38: 648–655 (1978).
37. Kohno, T., and Hayashi, Y. A histopathological study of the effects of nitrogen dioxide on the pulmonary alveoli in rats. Jpn. J. Soc. Air Pollut. 16: 313–327 (1981).
38. Hasegawa, H., Sato, M., Homma, T., Sudo, A., Miyagawa, M. Kawai, K., and Okonogi, K. Effect of NO_2 in each process of aging. (1) Results of biochemical examination. Conf. Jpn. Soc. Air Pollut. 473 (1980).
39. Freeman, G., Juhos, L. T., Furiosi, N. J., Mussenden, R., and Weiss, T. A. Delayed maturation of rat lung in an environment containing nitrogen dioxide. Am. Rev. Respir. Dis. 110: 754–759 (1974).
40. Nogami, H., Kusumoto, S., Higashi, E., Kimura, T., Nakajima, T., and Oda, H. Biological effects of NO_2 on suckling and infant mice. J. Conf. Soc. Air Pollut. 352 (1979).
41. Stephens, R. J., Sloan, M. F., Groth, D. G., Negl, D. S., and Lunan, K. D. Cytologic response of postnatal rat lungs to O_3 or NO_2 exposure. Am. J. Pathol. 93: 183–199 (1978).
42. Cabral-Anderson, L. J., Evans, M. J., and Freeman, G. Effects of NO_2 on the lungs of aging rats. Exp. Mol. Pathol. 27: 353–365 (1977).
43. Drozdz, M., Kucharz, E., and Szyja, J. Effect of chronic exposure to nitrogen dioxide on collagen content in lung and skin of guinea pigs. Environ. Res. 13: 369–377 (1977).
44. Hyde, D., Orthoefer, J., Dungworth, D., Tyler, E., Carter, R., and Lum, H. Morphometric and morphologic evaluation of pulmonary lesions in beagle dogs chronically exposed to high ambient levels of air pollutants. Lab. Invest. 38: 455–469 (1978).