Environmental Health Perspectives
Vol. 74, pp. 153-168, 1987

Morphological and Behavioral Markers of Environmentally Induced Retardation of Brain Development: An Animal Model

by Joseph Altman*

In most neurotoxicological studies morphological assessment focuses on pathological effects, like degenerative changes in neuronal perikarya, axonopathy, demyelination, and glial and endothelial cell reactions. Similarly, the assessment of physiological and behavioral effects center on evident neurological symptoms, like EEG and EMG abnormalities, resting and intention tremor, abnormal gait, and abnormal reflexes. This paper reviews briefly another central nervous system target of harmful environmental agents, which results in behavioral abnormalities without any qualitatively evident neuropathology. This is called microneuronal hypoplasia, a retardation of brain development characterized by a quantitative reduction in the normal population of late-generated, short-axoned neurons in specific brain regions.

Correlated descriptive and experimental neurogenetic studies in the rat have established that all the cerebellar granule cells and a very high proportion of hippocampal granule cells are produced postnatally, and that focal, low-dose X-irradiation either of the cerebellum or of the hippocampus after birth selectively interferes with the acquisition of the full complement of granule cells (microneuronal hypoplasia). Subsequent behavioral investigations showed that cerebellar microneuronal hypoplasia results in profound hyperactivity without motor abnormalities, while hippocampal microneuronal hypoplasia results in hyperactivity, as well as attentional and learning deficits.

There is much indirect clinical evidence that various harmful environmental agents affecting the pregnant mother and/or the infant lead to such childhood disorders as hyperactivity and attentional and learning disorders. As the developing human brain is more mature at birth than the rat brain, the risk for microneuronal hypoplasia and consequent behavioral disorders may be highest at late stages of fetal development, in prematurely born and small-for-weight infants, and during the early stages of infant development. Recent technological advances in brain imaging techniques make it possible to test this hypothesis and to assess the possible relationship between the degree of retarded brain development and ensuing behavioral disorders.

Introduction

Most current neurotoxicological investigations are concerned with the demonstration and analysis of frank pathological changes produced by toxicants and other harmful environmental agents and with the assessment of associated neurological and behavioral abnormalities. Examples of neuropathological changes that are usually examined are brain lesions, edema, sclerosis of the white matter, proximal and distal axonopathy, myelin loss, gliosis, and perikaryal pathology demonstrable at the light microscopic and electron microscopic levels. Among the neurological assessment techniques are EEG and EMG abnormalities, changes in nerve conduction and synaptic transmission, and altered levels of neurotransmitters and other humoral agents. Behavioral tests include measurement of sensory losses, reflex abnormalities, resting and intention tremor, gait abnormalities, and severe cognitive and memory deficits. This paper deals with a class of morphological and behavioral abnormalities of a more elusive nature induced by harmful environmental agents which, because of their nature, call for a different kind of morphological and functional assessment. The morphological change is not pathology, as usually defined, but a quantitative reduction of the full complement of short-axoned neurons of certain brain regions, and the behavioral disturbance may be limited to hyperactivity and some attentional, and possibly, learning, deficits. This paper has two objectives. First, it will review a series of experimental studies in rats in which a technique was used to interrupt the completion of neurogenesis, either in the cerebellum or the hippocampus, at selected stages of postnatal development and which was then followed by an assessment of the behavioral effects produced. Second, the paper will examine to what extent this experimental treatment and its consequences in the rat might be construed as a valid model of minimal brain dysfunction in man.

*Laboratory of Developmental Neurobiology, Department of Biological Sciences, Purdue University, West Lafayette, IN 47907.

The starting point of the experimental project was a series of developmental studies using ^{3}H-thymidine autoradiography in which we specified the precise chronological order of neurogenesis throughout the rat nervous system from its inception early during embryonic development until its virtual cessation late in infancy. This work established that, in the rat, the large population of short-axoned neurons (microneurons) of many brain structures are produced late in development and, in some brain regions (like the olfactory bulb, hippocampus and cerebellum), predominantly or exclusively after birth. This normative work was coupled with an experimental approach in which the cerebellum or the hippocampus was focally irradiated with low-level X-ray to selectively eliminate the highly radiosensitive precursor cells of microneurons without visibly harming the earlier differentiating long-axoned neurons (macroneurons). Depending on when the postnatal X-irradiation was begun, this resulted in a specifiable reduction of the microneuronal population of the selected brain region without any evident pathological effects either at the light or electron microscopic levels. Subsequent behavioral studies established that cerebellar microneuronal hypoplasia produced profound hyperactivity during infancy and adolescence, and hippocampal microneuronal hypoplasia led to hyperactivity, as well as attentional and learning disorders, mimicking the syndrome of minimal brain dysfunction in man.

The Neuroanatomical Background: Sequential Production of Microneurons and Macroneurons

The technique of ^{3}H-thymidine autoradiography makes it possible to determine the birth dates of neurons in experimental animals. When radioactively labeled thymidine (a specific precursor of DNA) is administered to the fetus or neonate, the radiochemical is taken up by the duplicating chromosomes of the proliferating precursor cells of neurons but not by the nuclei of differentiating (that is, postmitotic) nerve cells. In one of the early applications of this procedure, it was established that the sequence of production of neurons in the cerebral cortex is from its depth toward its surface (*1*). This suggested that the larger neurons of the cerebral cortex (such as the deep pyramidal cells) are generated before its smaller neurons (such as the superficial granule cells). A later study using this technique demonstrated that in the olfactory bulb, the hippocampus, and the cerebellum, the granule cells are among the latest produced cells of the brain (*2*), indeed, that in the rat these neurons are produced mostly postnatally. This was the first indication that the granule cells (microneurons) are distinguished from other neurons of a given brain structure by their late genesis.

Subsequent studies have established that within several brain structures, the production of macroneurons (large neurons with long axons) and microneurons is sequential. Thus, in the cerebellum (*3,4*), the cells first produced are the neurons of the deep nuclei; the Purkinje cells are generated next, and the last produced elements are the Golgi, basket, stellate, and granule cells, the axons of which terminate within the cerebellar cortex and thus complete its local circuitry. Similarly, in the spinal cord (*5*), the motor neurons that project to the skeletal muscles and autonomic ganglia are produced before the relay neurons that interconnect the spinal cord with supraspinal structures, and the small interneurons of the substantia gelatinosa are produced last. Moreover, embryological studies have revealed that the microneurons originate from a different proliferative source, or germinal matrix, than do the macroneurons. For instance, in the spinal cord (*5*), the motor neurons of the ventral horn (macroneurons) originate from the cells in the basal plate of the neuroepithelium surrounding the central canal, and the interneurons of the dorsal horn from the alar plate. In the cerebellum (*6,7*), the neurons of the deep nuclei and the Purkinje cells originate sequentially from the neuroepithelium surrounding the fourth ventricle, whereas the granule cells arise from the superficially located external germinal layer.

Macroneurons and microneurons can be distinguished

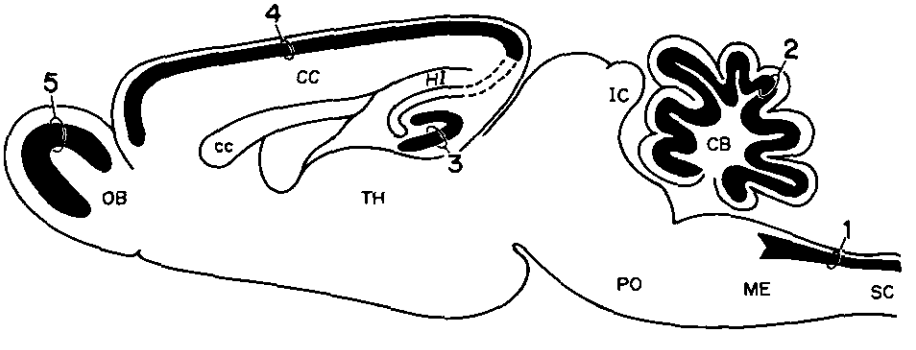

FIGURE 1. Location of extensive microneuronal systems in the rat brain in midsagittal section: (1) substantia gelatinosa of the spinal cord (SC); (2) granular layer of the cerebellum (CE); (3) granular layer of the dentate gyrus of the hippocampus (HI); (4) supragranular layers of the cerebral cortex (CC); (5) granular layer of the olfactory bulb (OB). Other abbreviations: cc, corpus callosum; IC, inferior colliculus; ME, medulla; PO, pons; TH, thalamus.

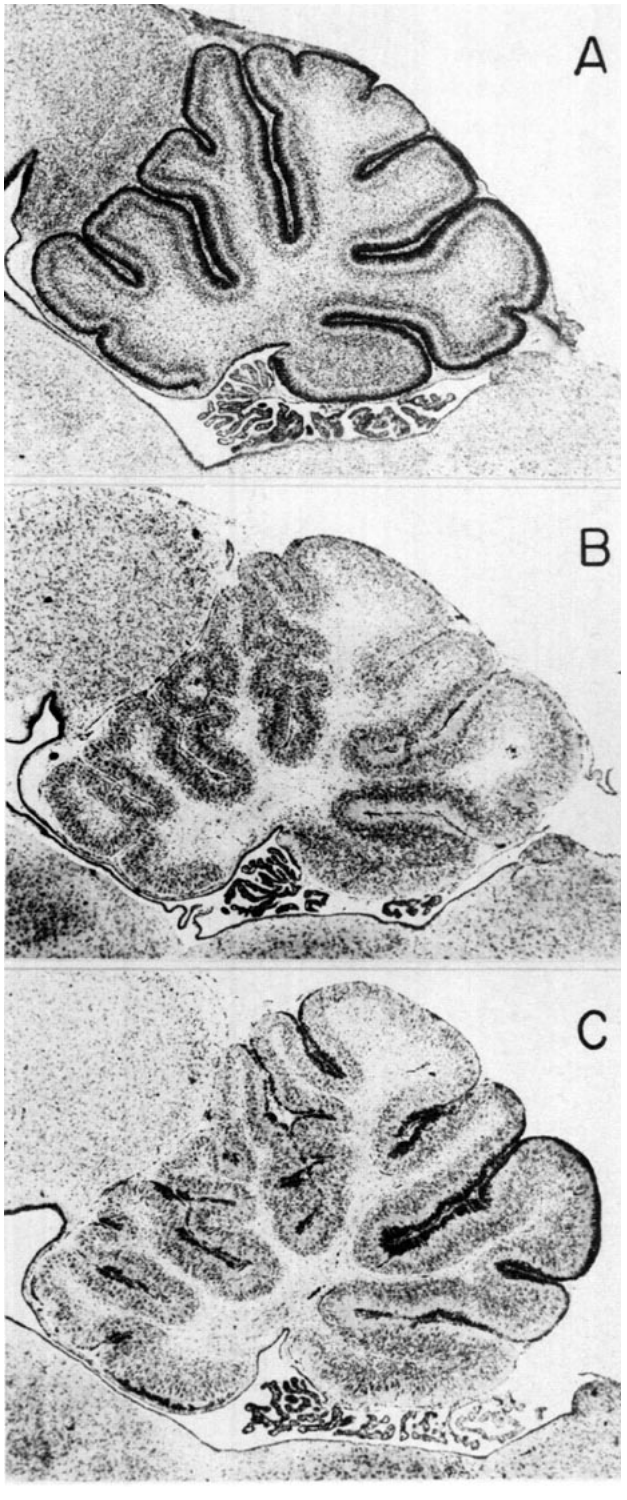

FIGURE 2. (*A*) Sagittal section through the cerebellum of an 8-day-old control rat. (*B*) In this 8-day-old rat the cerebellum was irradiated with 200R X-ray between the 4th and 7th day. Note the absence of the external germinal layer (dark band) over the surface of the cerebellar cortex. (*C*) In this 11-day-old rat, the external germinal layer begins to reappear after irradiation restricted to days 4 through 7.

not only by developmental criteria but also by their form and function in the mature nervous system. The principal characteristics of macroneurons are large cell bodies and long axons that either maintain connections between the central nervous system and peripheral structures (receptors, muscles, and autonomic ganglia) or interconnect distant components of the central nervous system. The sensory ganglion cells of the spinal and cranial nerve ganglia are examples of macroneurons linking the central nervous system with the periphery; the large neurons that project from the forebrain to the hindbrain and the spinal cord (like the cortical pyramidal cells) are examples of macroneurons within the brain. The macroneurons constitute the projection neurons of the nervous system that convey at a high speed either sensory messages or motor commands. In contrast, microneurons are typically cells with short axons and appear to be local processing elements that interconnect subcomponents of a single brain structure. In some brain regions microneurons form discrete zones, known as granular layers (Fig. 1).

X-Irradiation of the Cerebellum: The Production of Cerebellar Microneuronal Hypoplasia

Differentiating and mature neurons are not visibly affected when exposed to 150–200 X-ray, but their proliferating precursor cells are killed by such a dose (*8*). In an attempt to determine the developmental consequences of decimation of the germinal cells of the nervous system, Hicks and D'Amato (*9*) exposed pregnant rats to X-ray at different gestational ages and studied the developmental effects of irradiation in their fetuses. Our finding that, in the rat, the microneurons of the cerebellar cortex are produced postnatally prompted us to modify Hicks' procedure. We have irradiated the cerebellum selectively in neonates by shielding the rest of the brain and the entire body. The purpose was to destroy selectively the external germinal layer, which is the source of cerebellar microneurons, and later study the behavioral consequences of agenesis of cerebellar microneurons. Histological studies (*10*) showed that, as expected, the external germinal layer (Fig. 2*A*) was eliminated with a single dose of 150–200R X-ray (Fig. 2*B*), while the prenatally formed Purkinje cells were spared. However, within a few days after irradiation, the external germinal layer began to regenerate (Fig. 2*C*). Therefore, it became necessary to deliver supplementary doses of X-ray at certain daily intervals to prevent regeneration of the external germinal layer and the consequent acquisition of cerebellar microneurons (Fig. 3).

Behavioral studies showed that if the irradiation of the cerebellum was begun at birth (*11–13*), or even when it was delayed until postnatal day 4 (*14*), the severe agenesis of cerebellar microneurons had profound neurological consequences. These rats displayed such postural and motor abnormalities as intention tremor and

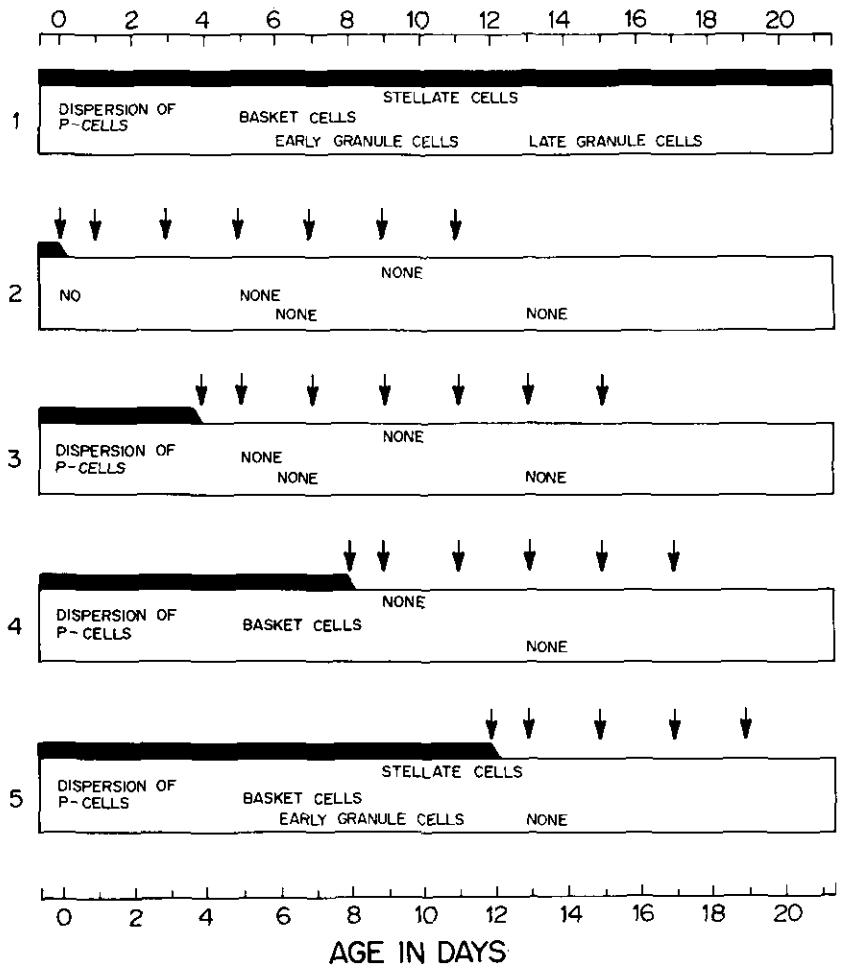

FIGURE 3. Diagram illustrating the expected consequences of irradiation of the cerebellum after birth for cell acquisition in the cerebellar cortex with different exposure schedules. Row 1 shows schematically the sequential production of different cell types in normal animals and approximate postnatal ages. Row 2 shows that with repeated doses of X-rays (arrows), which destroy the cells of the EGL and prevent their regeneration, the acquisition of the postnatally forming microneurons can be prevented. Row 3 shows that similar effects can be obtained by delaying irradiation until day P4. However, if the exposure to X-rays is begun on day P8 (row 4), the basket cells are spared, and if it is delayed until P12 (row 5), the stellate cells are also spared and only the acquisition of the late granule cells is prevented.

ataxia, and they fell when attempting to rear. Subsequent light microscopic and electron microscopic investigations (*15,16*) revealed that severe agenesis of cerebellar microneurons, though without effect on the number and size of Purkinje cells, interfered with the normal dendritic development of Purkinje cells (Fig. 4*D*). Therefore, our next attempt was to design an irradiation procedure that did not lead to such a severe microneuronal agenesis, but rather to a graded reduction of these cells, that is, microneuronal hypoplasia.

Cerebellar microneuronal hypoplasia can be experimentally produced by starting cerebellar irradiation after a certain proportion of the microneurons have already formed. Investigations dealing with the time course of the neurogenesis of cerebellar microneurons in the rat (*17,18*) have established that the basket cells are produced mostly on days 6 and 7, the stellate cells on days 8 to 11, and the granule cells beginning shortly after birth until day 21. Experimental studies with X-irradiation begun at different times and using different exposure schedules (*15,16,19,20*) have indicated that the presence of basket cells is essential for the guidance of the normal outgrowth of the Purkinje cell main dendrite.

Accordingly, in one group of rats irradiation was begun on day 8 to spare the basket cells (Fig. 3, row 4). This group will be referred to as 8–15X rats (radiation begun on day 8 and terminated on day 15). In routine histological preparations, the cerebellum of 8–15X rats appeared normal except for its greatly reduced size (Fig. 5*C*). This miniaturization was attributable primarily to the substantial reduction in the population of granule cells (Fig. 6*B*); the Purkinje cells were spared (Fig. 6*A*). In material prepared with the Golgi technique (*19*), the Purkinje cells showed an anomaly: their stem dendrites were erect and the fine branchlets were directed downward resembling weeping willows (Fig. 4*C*). In another group, referred to as the 12–15X rats,

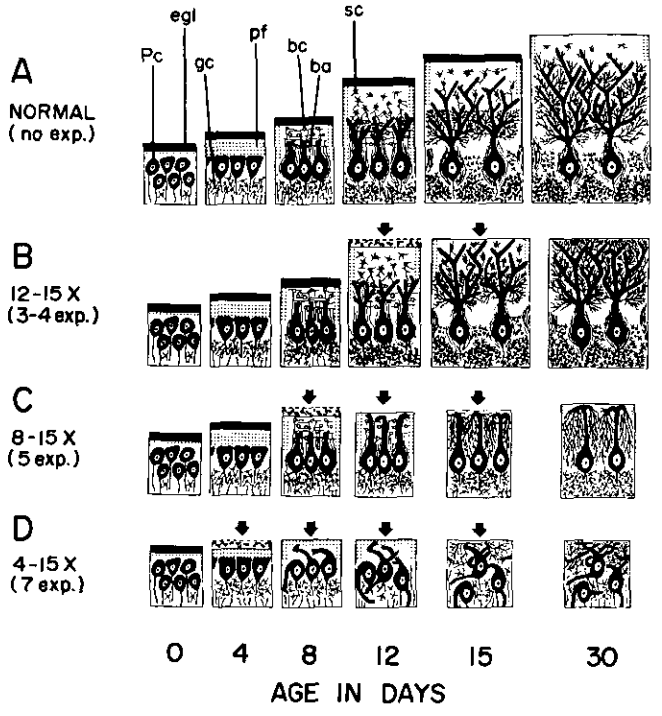

FIGURE 4. (*A*) Schematic illustration of stages in the development of the cerebellar cortex from birth to 30 days. (*B*) X-irradiation (arrows) of the cerebellum between days 12 and 15 results in destruction of the superficial external germinal layer (egl). The already differentiated Purkinje cells (Pc), basket cells (bc), and stellate cells (sc) are spared; however, there is a reduction in the total population of granule cells (gc), coupled with a truncation of the expanse of Purkinje cell dendrites. (*C*) X-irradiation of the cerebellum between days 8 and 15 prevents the generation of stellate cells and affects the arborization pattern of Purkinje cell dendrites which assume the shape of weeping willows. (*D*) X-irradiation begun on day 4 prevents the production of basket and stellate cells and most of the granule cells. The effect on the development of Purkinje cells is drastic: the cell bodies of Purkinje cells become scrambled, and instead of one upright main dendrite, many such dendrites are formed and grow haphazardly.

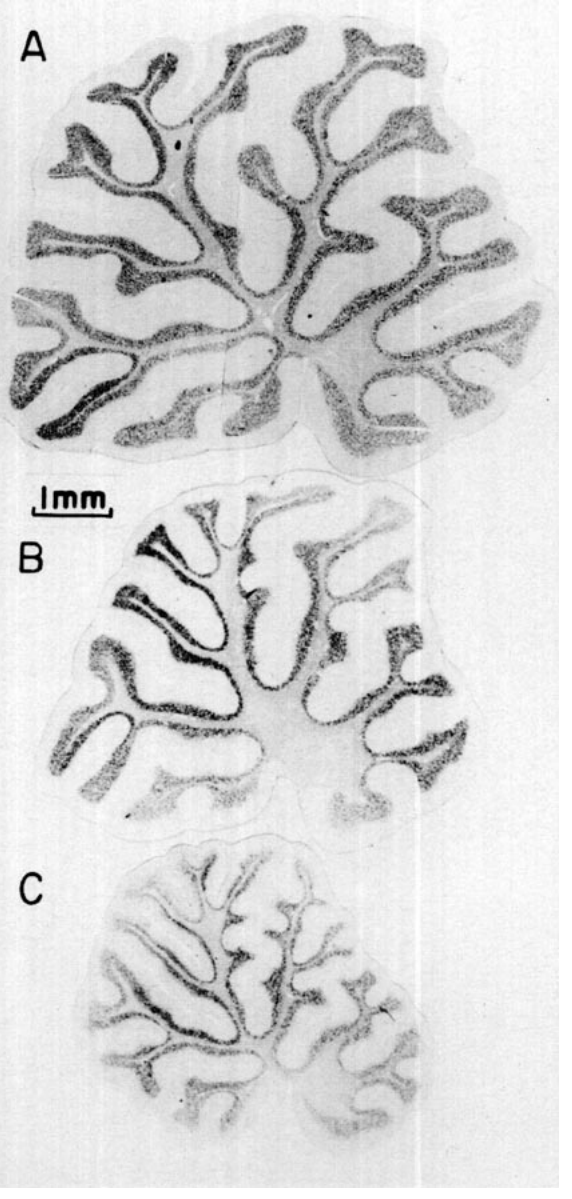

FIGURE 5. Photomicrographs of the cerebellum in midsagittal section from a normal rat (*A*), a rat irradiated between days 12 and 15 (*B*), and a rat irradiated between days 8 and 15 (*C*).

cerebellar irradiation was begun on day 12 (Fig. 3, row 5). This procedure spared both basket and stellate cells (*20*) and, on the average, spared over 50% of the granule cells (Fig. 6*B*). The cerebellum of this group appeared qualitatively normal, except that the reduction in size of the cerebellar cortex (Fig. 5*B*) was associated with a slight truncation of the dendritic expanse of Purkinje cells (Fig. 4*B*).

Behavioral Effects of Cerebellar Microneuronal Hypoplasia

Initial observations failed to show any postural or motor deficits in the 8–15X and 12–15X rats. There was no indication of tremor, ataxia, or any difficulty with ambulation. We reasoned that if we could only challenge the 8–15X rats with a sufficiently difficult postural-locomotor task, we might be able to demonstrate some deficits in this more severely affected group. Accordingly, a motor-driven rotating rod apparatus was designed (*21*) in which motor performance could be made progressively more difficult by placing hurdles of different heights and different spacing in the path of the animal as it voluntarily crossed the rod for a food reward. The criterion was the rotation speed that the animals could master. With this procedure we could not distinguish the experimental and control groups; in fact, in most of the tests, the 8–15X rats were slightly superior to the controls, apparently because of their greater willingness to run after they fell off the rod. It was concluded that cerebellar hypoplasia, with a reduction of over 80% of the granule cells (Fig. 6*B*), does

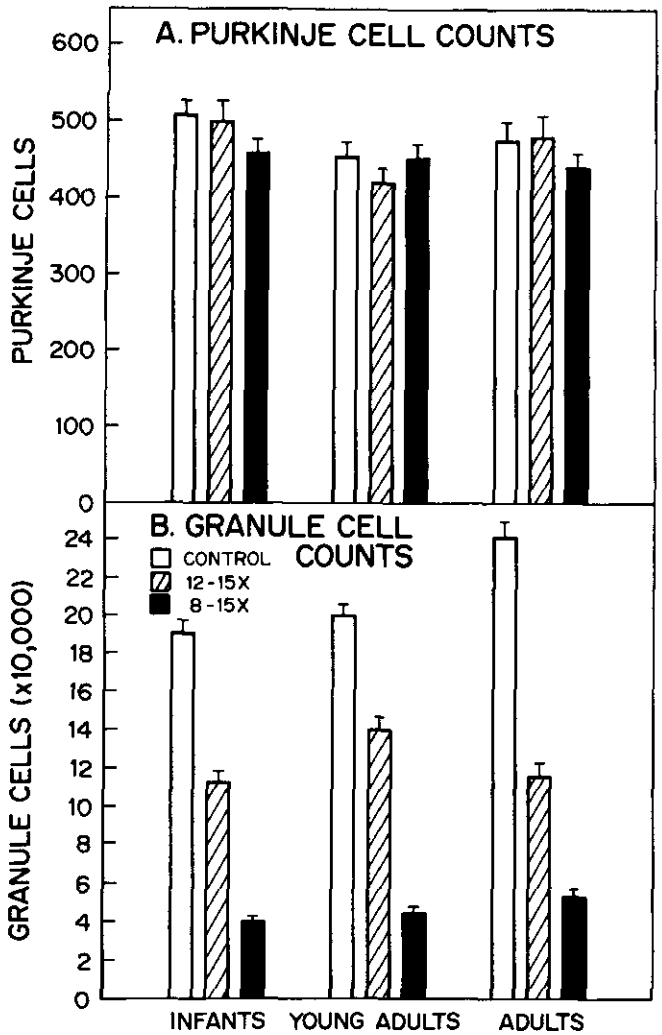

FIGURE 6. Counts of Purkinje cells (*A*) and granule cells (*B*) at three ages in control, 12–15X, and 8–15X rats in a matched region of the cerebellar cortex. Modified from (*21*).

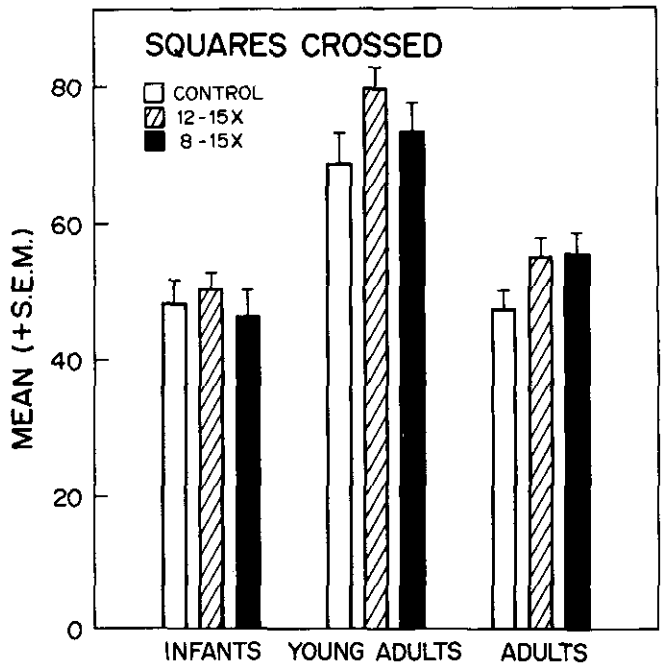

FIGURE 7. Ambulatory scores over a 3-min period in the open-field test of three groups of rats at three ages. Modified from (*21*).

not produce any demonstrable locomotor deficits. However, in another experiment, 8–15X and 12–15X rats of three ages (infants, young adults, adults) were compared with controls in an open field. Each rat was observed for 3 min on 5 successive days and the number of squares crossed was tabulated. This measure indicated (Fig. 7) that the two irradiated groups were more active than the controls if tested at the age of 2 months (young adults) or 6 months (adults).

Since ambulation in an open field is affected by emotionality, we more directly tested the possible hyperactivity of the 8–15X and 12–15X groups in individual activity wheels attached to the home cages. The spontaneous running of the young adult irradiated animals far surpassed that of the controls (Fig. 8). It was concluded from these results (*21*) that microneuronal hypoplasia of a level of severity that does not produce demonstrable locomotor deficits leads to hyperactivity at an age when the animals tend to be most active.

Behavioral Effects of Hippocampal Microneuronal Hypoplasia

The two major components of the hippocampus are Ammon's horn and the dentate gyrus (Fig. 9). The dominant cell type of Ammon's horn is the larger pyramidal cells, and the dominant cell of the dentate gyrus is the smaller granule cells. In the rat, the pyramidal cells are produced on embryonic days 17 to 19 (*22*), while the bulk of the granule cells is generated postnatally (*23,24*). The granule cells have relatively short axons that project to a component of Ammon's horn, thus they represent the microneurons of the hippocampus. Experimental studies using focal X-irradiation of the hippocampal region (*25,26*) showed that there is a substantial reduction in the granule cell population if irradiation is begun immediately after birth (Fig. 9*B*). This granule cell hypoplasia (representing about 85% of the cells generated postnatally) (Fig. 10*B*) does not affect the morphology of the hippocampus, except for a slight reduction in its length (Fig. 10*A*), and it is not accompanied by a significant reduction in pyramidal cells (Fig. 10*C*).

Behavioral studies showed that rats with hippocampal microneuronal hypoplasia are extremely hyperactive when tested in an open field (*25*) and in running wheels (*27*). In addition, the irradiated rats display other behavioral changes usually associated with hippocampal damage, including abolition of spontaneous alternation in a T maze and deficits in passive avoidance learning (*25*). In a subsequent investigation of the effects of hippocampal microneuronal hypoplasia on dis-

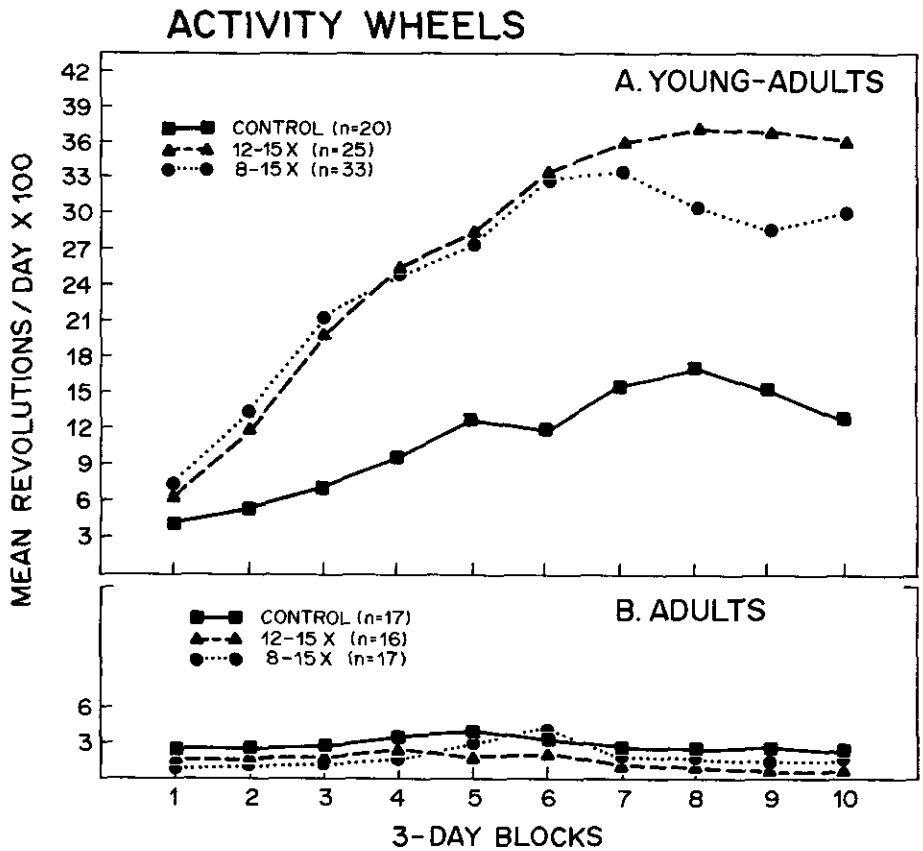

FIGURE 8. Running performance of three groups of rats over a period of 30 days in activity wheels. (*A*) juveniles; (*B*) adults. Modified from (*21*).

crimination learning, Bulut (*28*) used a T-shaped water maze with access to an escape ramp as the reward. Four age groups were compared on the speed of acquisition of a spatial task (selecting the right or left arm) and its subsequent reversal (Fig. 11), and on the acquisition and reversal of a brightness discrimination task (selecting the lighted or dark arm) (Fig. 12). The irradiated animals were deficient at all ages. The deficit was less severe at most ages on the acquisition of the spatial task (Fig. 11) than on the more difficult brightness discrimination (Fig. 12), and in both sense modalities reversal learning was more affected than the original acquisition. The handicap of the rats with hippocampal hypoplasia was partly the result of making many incorrect responses before a task was mastered. Examples of these incorrect responses were the adoption of a spatial strategy when the solution required that the animals attend to the visual cues, or persevering with the initially learned solution when its reversal became necessary in order to escape from the water.

This study raised a question about the nature of the learning disability produced. Does hippocampal microneuronal hypoplasia produce memory deficits, an attentional disorder, or some abnormal response tendency? In the next investigation (*29*), the learning speed of irradiated and control rats was determined in a T-maze motivated by food reward (Fig. 13). Tactile and visual cues in the two maze arms were graded in difficulty by decreasing their discriminability. In the tactile series (Fig. 13*A*), the task of different groups of rats was to heed at the choice point the texture of the metal floor plates of the two arms, which ranged in difficulty from the very easy (polished versus coarse textured aluminum plates; smooth/coarse) to the very difficult (two grades of machined plates referred to as rough/coarse). Task difficulty was operationally defined in terms of the number of trials required by control rats to reach criterion level of performance. After mastering the original discrimination, each animal was required to reverse its response. In the visual series (Fig. 13*B*), the cue at the choice point was the overhead illumination of the two arms, which ranged in discriminability from the very easy (bright/dark) to the very difficult (two grades of brightness; here referred to as bright/dull).

The results showed that as long as task difficulty was in the very easy to moderate range (maximum of about 150 trials needed by control rats to reach criterion level of performance) the irradiated rats were not handicapped, irrespective of whether the cues were tactile or visual. Moreover, in spite of the fact that reversal learning required more trials in every task than acquisition learning, the irradiated animals were not handicapped in reversing their response as long as the task fell in the very easy to moderate range. In contrast, in

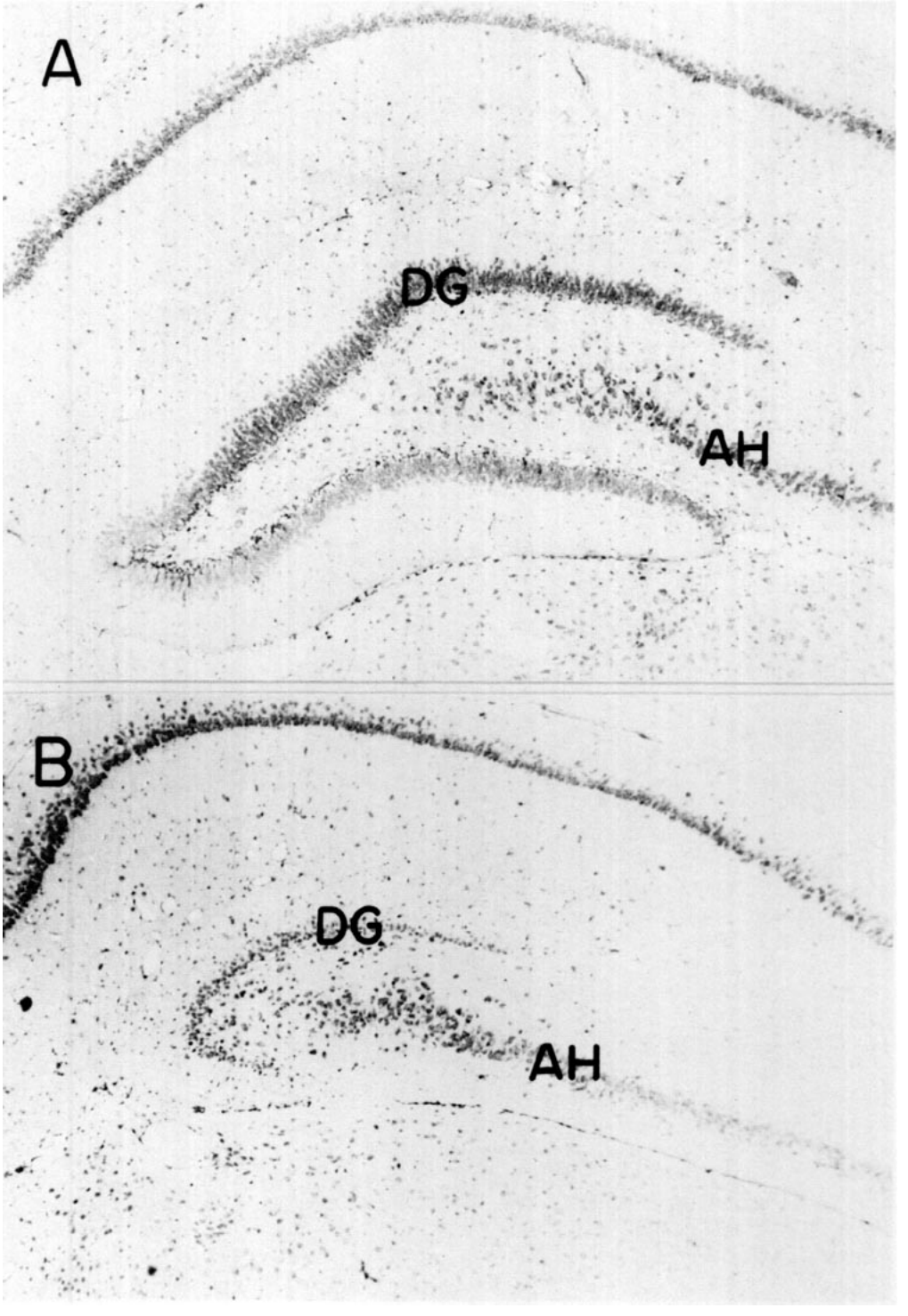

FIGURE 9. Ammon's horn (AH) and dentate gyrus (DG) of the hippocampus in a normal rat (*A*) and a rat focally irradiated on days 2 through 15 (*B*).

tasks that were difficult or very difficult (200–300 trials to criterion), the rats with hippocampal microneuronal hypoplasia were significantly impaired, both in tactile and visual discrimination, and in acquisition as well as reversal.

The tactile and visual cues used in the first two series of experiments (Figs. 13*A*,*B*) were interpreted as global or diffuse stimuli. An animal running down an alley necessarily receives sensory input about the texture of the floor and about ambient illumination. If so, all cues

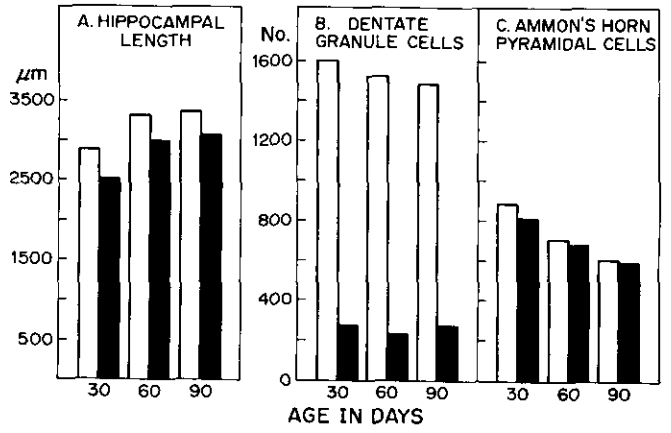

FIGURE 10. Effects of X-irradiation of the hippocampus (solid bars) on its length (*A*); the number of granule cells (*B*); and the number of pyramidal cells (*C*) in comparison to controls (open bars). The apparent decrease in the number of pyramidal cells (*C*) as a function of age results from the expansion of the volume of the hippocampus during this period (*A*).

in these tasks were highly noticeable and differed only in their discriminability from very easy to very difficult. How would the performance of the experimental animals be affected if the cues were made less noticeable? In a third incomplete series of experiments (Fig. 13*C*), two localized, or focal visual cues were introduced that were easily discriminable. In this experiment black and white sheets, the cues to the location of the food reward, were limited to the side of the goal arms. Although the acquisition of this discrimination proved easy for the control rats, requiring about 100 trials, the rats with hippocampal microneuronal hypoplasia were handicapped both in the aquisition and reversal of this task (Fig. 13*C*).

In summary, these experiments indicate that hippocampal microneuronal hypoplasia, not unlike cerebellar microneuronal hypoplasia, leads to hyperactivity. In addition, retardation of hippocampal development also results in learning disabilities under certain circumstances. One of these situations appears to be when either the discriminability of the sensory cues or their noticeability is reduced. The other situation is where the subject has to inhibit an established response tendency (reversal task). These observations suggest that attentional disorders, possibly caused by hyperactivity, rather than a fundamental memory disorder, underlie the poor discrimination-learning performance of animals with experimentally produced hippocampal microneuronal hypoplasia.

Do Toxic Agents Produce Microneuronal Hypoplasia and Behavioral Disorders in Animals and Man?

With the technique of focal X-irradiation it is possible to prevent in the rat the acquisition of the full complement of postnatally forming granule cells of the cerebellum or a large proportion of the granule cells of the hippocampus. As we noted, the behavioral effect of moderate cerebellar microneuronal hypoplasia is hyperactivity, and the effect of hippocampal microneuronal hypoplasia is both hyperactivity and learning disabilities. Since this is an experimental manipulation, the question arises: do other harmful environmental agents affecting the developing nervous system during the perinatal and early postnatal periods produce microneuronal hypoplasia and correlated behavioral disorders? Since this question has yet to be subjected to direct experimental test, all we can do at present is cite indirect evidence that supports this possibility. As much of this material has been reviewed elsewhere (*30*), we shall present here a brief summary of the concept of minimal brain dysfunction and mention a few illustrative cases, one concerning the effects of lead poisoning in animals and man, another of drug addiction in humans, and still another, based on a new study by Courchesne and his collaborators (*31*), linking autism in man to cerebellar microneuronal hypoplasia.

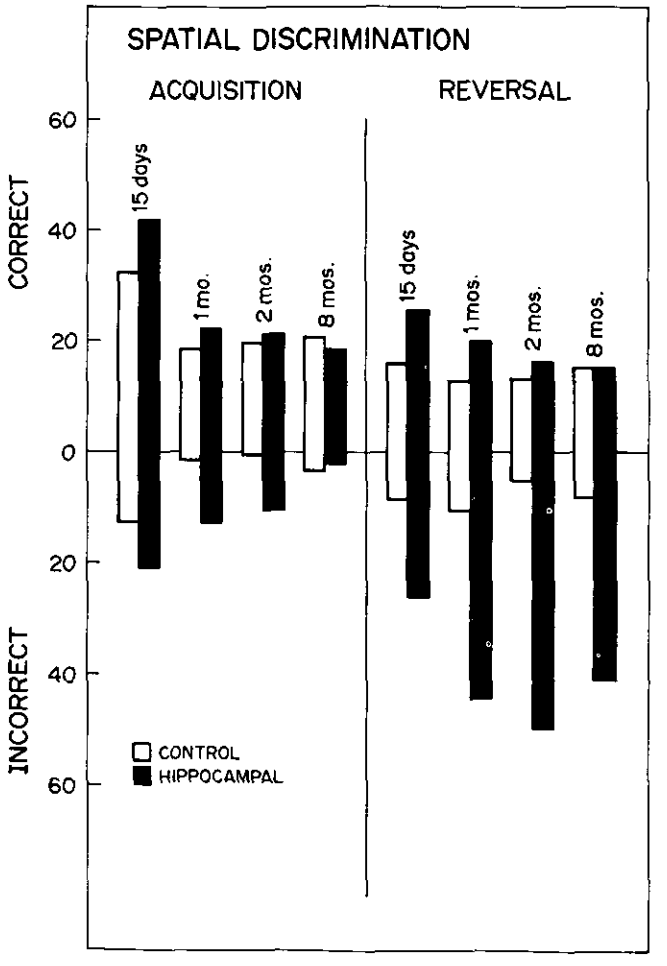

FIGURE 11. Number of trials required to master a spatial discrimination learning task in a water T-maze and its reversal, in four age groups of normal rats (open bars) and rats with hippocampal microplasia (solid bars). Modified from (*28*).

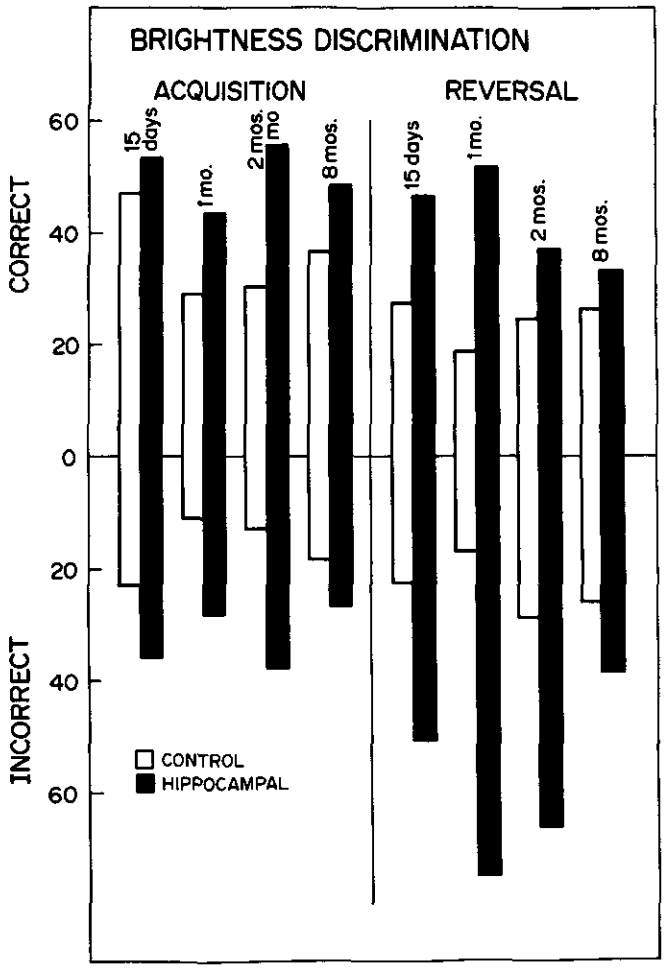

FIGURE 12. Number of trials required to master a brightness discrimination task, and its reversal, in four age groups of normal rats (open bars) and rats with hippocampal microplasia (solid bars). Modified from (*28*).

Strauss and his collaborators proposed some time ago (*32,33*) that the familiar hyperactivity, emotionality, and attentional difficulties of children who were not mentally retarded and showed few or no signs of neurological disorders, was due to some unspecified brain insult suffered during the perinatal period. This idea of putative brain damage in children with learning disabilities became widely accepted for a while (*34,35*). However, by the late 1950s, signs of uneasiness appeared about this unwarranted neurologizing. Since brain damage had not been demonstrated in these children, and neurological symptoms, including soft signs such as minor EEG abnormalities were absent in many, it was suggested that the adjective "minimal" be added to the term "brain damage" (*36*) or that "damage" be replaced by "dysfunction" (*37*). Others (*38,39*) have pointed out that since many brain-damaged children show no signs of this behavioral disorder, qualifying words like "minimal" or "dysfunction" do not salvage the syndrome as conceptualized. Nevertheless, the concept of minimal brain dysfunction has not been abandoned.

Faith in the neurological foundation of the hyperactivity and learning disability syndrome may have survived in spite of all the criticisms leveled against it because of strong indications of its organic etiology. As early as 1939, Shirley (*40*) made a follow-up study of prematurely born children and found that they were, as a group, hyperactive, distractible, and stubborn, and had difficulties with fine motor control. In a retrospective study, Pasamanick and Knobloch (*36*) found that a higher proportion of children with school problems than matched control children had perinatal medical complications, and that their major symptom was hyperactivity. Several large-scale recent studies have established that prematurely born babies and small-for-date babies are at a high risk for developing hyperactivity and/or learning disabilities (*41–46*).

Low birth weight and preterm delivery may have a variety of causes. Among the suspected antecedent conditions are various toxicants, including tobacco smoke, narcotics, and alcohol. Several studies have shown (*47,48*) that the mother's smoking during pregnancy creates the risk of low birth weight, retarded early growth, and subsequent hyperactivity and learning disabilities. In a retrospective study, Denson and colleagues (*49*) found that mothers of hyperactive children smoked on the average much more than the mothers of control children. The association between smoking and the development of hyperactivity in the child has also been established in a large-scale prospective study (*50*). Similarly, heroin addiction in the mother presents a great risk of premature delivery or the delivery of small-for-gestational-age infants (*51–54*), even when the mother's malnutrition and inadequate prenatal care are ruled out (*55,56*). The progeny of addicted mothers are reported to be irritable and hyperactive as infants (*57–59*) and distractable and inattentive during early childhood (*60–62*).

Impulsivity, hyperactivity, perceptual disorders, and learning disabilities are frequent symptoms in children who in early infancy and childhood have been exposed to lead (*63–71*). In severe cases of lead poisoning, mental retardation and other hard neurological symptoms may also be present (*63,65,72*). As lead poisoning tends to result from oral intake of substances containing some traces of lead (for instance, wall paint), the postulated brain pathology must be incurred during infancy and early childhood.

The effects of lead poisoning in children led to experimental studies in animals. Silbergeld and Goldberg (*73*) reported that neonate mice administered lead in various concentrations displayed motor deficits and hyperactivity. The pronounced hyperactivity was attenuated by stimulants such as amphetamines (*74*). Hyperactivity in animals as a consequence of lead poisoning was reported by other investigators (*75–78*) as were learning deficits (*79–81*). Alfano and Petit (*82*) found that neonatal lead exposure in rats reproduced the complex of symptoms associated with hippocampal dysfunction, including deficits in spontaneous alternation, passive avoidance learning, acquisition of visual discrimina-

SENSORY CUE	LEARNING TASK	TASK DIFFICULTY: Very Easy (<75 T)	Easy (<105 T)	Moderate (~150 T)	Difficult (~200 T)	Very Difficult (~300 T)
A. TACTILE (global)	Acquisition	smooth/coarse NO	smooth/rough NO			rough/coarse YES
	Reversal		smooth/coarse NO	smooth/rough NO		
B. VISUAL (global)	Acquistion	bright/dark NO	bright/faint NO		bright/dull YES	
	Reversal			bright/dark NO	bright/faint YES	bright/dull YES
C. VISUAL (focal)	Acquistion		black/white YES			
	Reversal				black/white YES	

FIGURE 13. Summary diagram of the absence (NO) or presence (YES) of deficits in rats with hippocampal microplasia in the acquisition and reversal learning of three tasks using different cues (tactile, global; visual, global; visual, focal) with five levels of difficulty, as defined by the number of trials (T) required by control rats to master the task. Modified from (*29*).

tions, and their reversal. However, at present, direct evidence of lead-induced hippocampal microneuronal hypoplasia is not available. Most of the pathological studies have concentrated on lead-induced vascular abnormalities and hemorrhages, which are particularly pronounced in the cerebellum (*83,84*). Lead is taken up preferentially by immature capillaries, and it interferes with their development (*85–87*); the mature capillaries are protected (*88*). These observations suggest that if lead poisoning in neonate mice and rats does lead to microneuronal hypoplasia, this effect is mediated indirectly by way of interference with the development of the vascular system of late-maturing brain regions.

No matter how strong the available evidence for the organic etiology of the hyperactivity and learning disability syndrome, that, by itself, is no justification to attribute it to minimal brain damage. Evidence for brain damage has to come from an examination of the nervous system itself. Adequate postmortem anatomical descriptions of the brains of individuals diagnosed as having suffered from minimal brian dysfunction are not available. Descriptions are available of the brains of fetuses and premature or full-term neonates in whom hypoxia and consequent hemorrhage were thought to be the major cause of brain insult (*89–94*). The most common pathology in premature neonates is hemorrhagic destruction of the germinal matrix surrounding the anterior cerebral (lateral) ventricles; in the full-term newborn, the hypoxic damage may also affect the tissue of the cerebral cortex. But the argument that these acute hypoxic brain pathologies are representative of damages associated with minimal cerebral dysfunction (*95*) is difficult to accept. Even if many of these fetuses and neonates died of causes other than the neurological complications, it is unlikely that the focal lesions described would have remained unaccompanied by hard neurological symptoms in the surviving child. As Towbin (*96*) suggested, these acute hemorrhagic damages seen in hypoxic fetuses and neonates are antecedents of the cerebral lesions, cavitations, and scarring seen in the brains of the mentally retarded and cerebral palsied children.

Recent technological developments in the visualization of features of the brain with computer-aided imaging techniques have raised the possibility of an *in vivo* investigation of the proposition that microneuronal hypoplasia in man is associated with behavioral disorders. In a recent study, Courchesne et al. (*31*) used the magnetic resonance imaging technique to examine the brain of a patient with Kanner's syndrome, the classic form of autism without mental retardation. The principal morphological abnormality found (Fig. 14) was a cerebellar hypoplasia of lobules VI and VII in the posterior vermis. Courchesne and his collaborators have since scanned the brains of 17 autistic individuals and found macroscopic signs of selective hypoplasia in vermal lobules VI and VII in 13 of these individuals (personal communication).

Although the resolution provided by this imaging technique does not reveal the microscopic features of the morphological abnormalities, our past findings regarding the exact chronology of rat cerebellar neurogenesis suggests that these cases may represent a selective form of cerebellar microneuronal hypoplasia. Figure 15 is reproduced from a study (*17*) in which rats were injected with multiple doses of ^{3}H-thymidine beginning on postnatal day 11 in order to label all the cerebellar granule cells that are produced between days

A
Normal

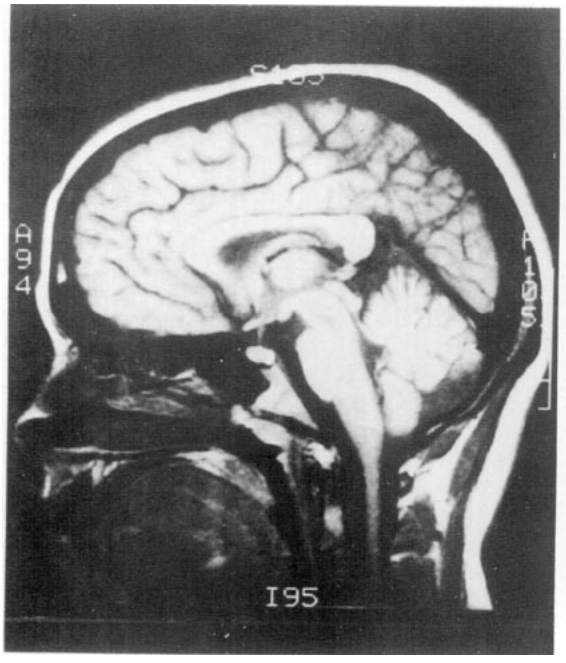

Midline Sagittal

B
Patient with Autism

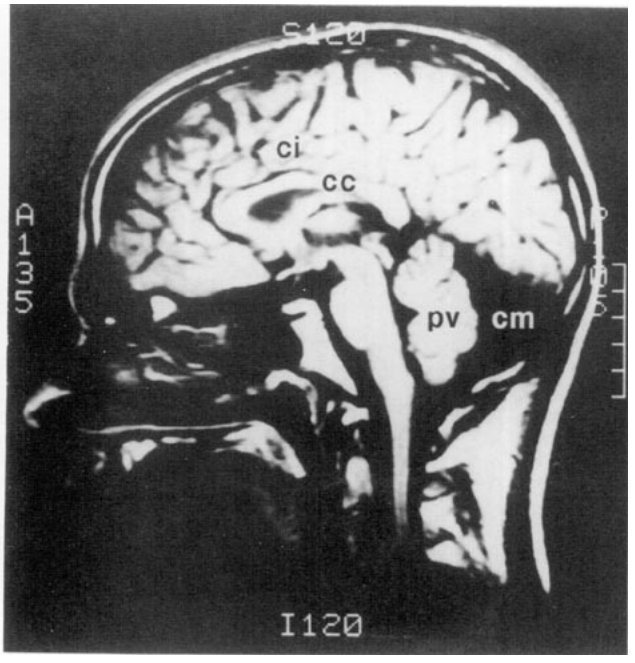

Midline Sagittal

C
Patient with Autism

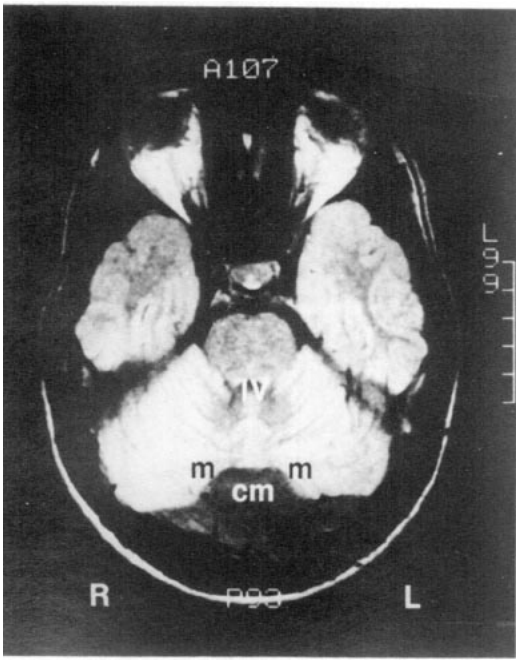

7.5 mm Above
Fourth Ventricle
Axial

FIGURE 14. Sagittal (*B*) and axial (*C*) MRIs show hypoplasia of posterior vermis (pv) and of medial aspect of cerebellar hemispheres (m) in nonretarded patient with infantile autism. Folia of the posterior vermis are incompletely formed. Cisterna magna (cm) is enlarged. Other midline structures, including fourth ventricle (IV), brainstem, diencephalon, corpus collosum (cc), and medial cortical areas (e.g., cingulate gyrus, ci), appear normal. The midline sagittal section of a normal subject is shown in (*A*). Courtesy of Eric Courchesne.

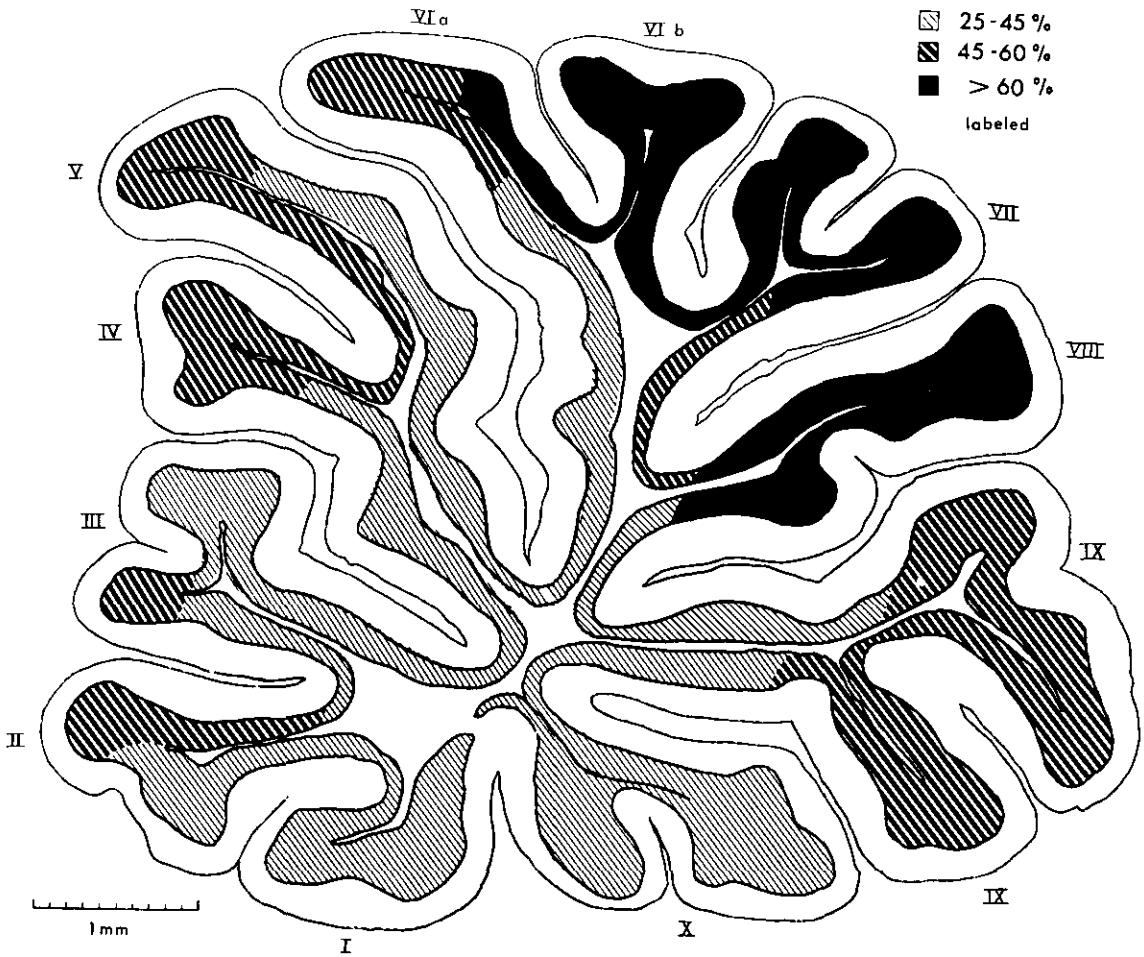

FIGURE 15. Schematic presentation of the percentage of granule cells labeled in the different lobules of the vermis (I-X) in rats that were injected with multiple doses of ^{3}H-thymidine between days P11 and P16. Regions where less than 45% of the cells could be tagged are considered early forming, while those where more than 60% of the cells were labeled are considered late forming. From (*17*).

11 and 21 (the day when cerebellar neurogenesis comes to an end in the rat). There were considerable regional differences: in some regions only 25% of the cells could be labeled (which indicates that 75% of the granule cells in that region are generated before day 11), while in other regions up to 78% of the cells were labeled. The shadings in Figure 15 are based on an arbitrary tripartite division into an early generated region (25–45% labeled), an intermediate region (45–60% labeled), and a late generated region (60–78% labeled). The latest developing region of the cerebellar cortex includes lobules VI, VII, and VIII. Lobule VIII (the pyramis) had the lowest labeling among the three lobules (63–64%) (*17*) (Fig. 11*A*), and is therefore an earlier generated region than lobules VI and VII found affected in the studies of Courchesne and his collaborators. Thus the question arises whether interference with the acquisition of the latest generated microneurons of the cerebellar cortex is the structural cause of autism.

Autism has been related to auditory and visual perceptual disorders. It is of significance, therefore, that vermal lobules VI and VII are unique regions of the cerebellum where evoked responses can be recorded to auditory and visual stimuli (*97*). The auditory projection is direct from the cochlear nucleus (*98,99*). Vermal lobules VI and VII have also been implicated in the voluntary control of eye movements (*100–103*). Thus, selective hypoplasia of the large (and presumably latest developing) vermal lobules VI and VII in man could interfere with auditory and visual attentional mechanisms.

Morphological and Behavioral Markers of Retarded Brain Development in Man

When we consider the applicability of the syndrome of microneuronal hypoplasia in rats to minimal brain dysfunction in man, we must take into account some important differences in the time course of neurogenesis in the two species. Apart from the obvious difference in the speed of development (the prenatal period of nervous system development in the rat is only about 12

days, from embryonic day 10–21), the human brain is much more mature at the time of birth than the rat brain. While direct evidence is not available, the proliferation of the precursors of microneurons must be largely a prenatal phenomenon in man. This is indicated by the relatively small size of the germinal matrix of the cerebral cortex at birth and by the reduced width of the cerebellar external germinal layer, which persists in man well into the second year of life (*104*).

Due to this chronological difference in brain development, it may be expected that the greatest risk of microneuronal hypoplasia in man is not in the infantile period but at some late stage of fetal development and, in particular, upon the exposure of the prematurely born and the small-for-date infant to toxicants. In fact, many studies are available to show that babies "born too soon or born too small" (*46*) are at a high risk for developing behavioral disorders, particularly hyperactivity and learning disabilities (*41–45, 105–109*), with boys displaying this syndrome more often than girls (*46*). Since only a small proportion of the high-risk children are diagnosed as suffering from behavioral abnormalities, and some of the potential disorders may be prevented by special care, it may be advisable to screen those at risk for the presence of retarded brain development and its extent by using the magnetic resonance imaging technique.

This research project was supported by the National Science Foundation and the National Institutes of Health. The original investigations from our laboratory reviewed here were carried out in collaboration with William J. Anderson, Shirley A. Bayer, Robert L. Brunner, Fatma Bulut-de Eskenazy, Russell A. Gazzara, and Louis J. Pellegrino. An earlier, detailed version of this article appeared in M. Lewis (Ed.), Learning Disabilities and Prenatal Risk, University of Illinois Press, Urbana, IL, 1986. Extracts are published by permission of the Board of Trustees of the University of Illinois.

REFERENCES

1. Angevine, J. D., and Sidman, R. L. Autoradiographic study of cell migration during histogenesis of cerebral cortex in the mouse. Nature 192: 766–768 (1961).
2. Altman, J., and Das, G. D. Post-natal origin of microneurones in the rat brain. Nature 207: 953–956 (1965).
3. Altman, J., and Bayer, S. A. Prenatal development of the cerebellar system in the rat. I. Cytogenesis and histogenesis of the deep nuclei and the cortex of the cerebellum. J. Comp. Neurol. 179: 23–48 (1978).
4. Altman, J. Morphological development of the rat cerebellum and some of its mechanisms. In: The Cerebellum: New Vistas (S. L. Palay and V. Chan-Palay, Eds.), Springer-Verlag, Berlin, 1982, pp. 8–49.
5. Altman, J., and Bayer, S. A. The Development of the Rat Spinal Cord. In: Advances in Anatomy, Embryology and Cell Biology, Volume 85. Springer-Verlag, Berlin, 1984, pp. 1–166.
6. Altman, J., and Bayer, S. A. Embryonic development of the rat cerebellum. I. Delineation of the cerebellar primordium and early cell movements. J. Comp. Neurol. 231: 1–26 (1985).
7. Altman, J., and Bayer, S. A. Embryonic development of the rat cerebellum. II. Translocation and regional distribution of the deep neurons. J. Comp. Neurol. 231: 27–41 (1985).
8. Hicks, S. P. Radiation as an experimental tool in mammalian developmental neurology. Physiol. Rev. 38: 337–356 (1958).
9. Hicks, S. P., and D'Amato, C. J. Effects of ionizing radiations on mammalian development. In: Advances in Teratology (D. H. M. Woollam, Ed.), Logos Press, London, 1966, pp. 195–250.
10. Altman, J., Anderson, W. J., and Wright, K. A. Early effects of x-irradiation of the cerebellum in infant rats: decimation and reconstitution of the external granular layer. Exp. Neurol. 24: 196–216 (1969).
11. Wallace, R. B., and Altman, J. Behavioral effects of neonatal irradiation of the cerebellum. I. Qualitative observations in infant and adolescent rats. Dev. Psychobiol. 2: 257–265 (1969).
12. Wallace, R. B., and Altman, J. Behavioral effects of neonatal irradiation of the cerebellum. II. Quantitative studies in young-adult and adult rats. Dev. Psychobiol. 2: 266–272 (1969).
13. Altman, J., Anderson, W. J., and Strop, M. Retardation of cerebellar and motor development by focal x-irradiation during infancy. Physiol. Behav. 7: 143–150 (1971).
14. Anderson, W. J., and Altman, J. Retardation of cerebellar and motor development in rats by focal x-irradiation beginning at four days. Physiol. Behav. 8: 57–67 (1972).
15. Altman, J., and Anderson, W. J. Experimental reorganization of the cerebellar cortex. I. Morphological effects of elimination of all microneurons with prolonged x-irradiation started at birth. J. Comp. Neurol. 145: 355–406 (1972).
16. Altman, J., and Anderson, W. J. Experimental reorganization of the cerebellar cortex. II. Effects of elimination of most microneurons with prolonged x-irradiation started at four days. J. Comp. Neurol. 149: 123–152 (1973).
17. Altman, J. Autoradiographic and histological studies of postnatal neurogenesis. III. Dating the time of production and onset of differentiation of cerebellar microneurons in rats. J. Comp. Neurol. 136: 269–294 (1969).
18. Altman, J. Postnatal development of the cerebellar cortex in the rat. I. The external germinal layer and the transitional molecular layer. J. Comp. Neurol. 145: 353–398 (1972).
19. Altman, J. Experimental reorganization of the cerebellar cortex. V. Effects of early x-irradiation schedules that allow or prevent the acquisition of basket cells. J. Comp. Neurol. 165: 31–48 (1976).
20. Altman, J. Experimental reorganization of the cerebellar cortex. VII. Effects of x-irradiation schedules that interfere with cell acquisition after stellate cells are formed. J. Comp. Neurol. 165: 65–76 (1976).
21. Pellegrino, L. J., and Altman, J. Effects of differential interference with postnatal cerebellar neurogenesis on motor performance, activity level, and maze learning of rats. A developmental study. J. Comp. Physiol. Psychol. 93: 1–33 (1979).
22. Bayer, S. A. Development of the hippocampal region in the rat. I. Neurogenesis examined with ^{3}H-thymidine autoradiography. J. Comp. Neurol. 190: 87–114 (1980).
23. Bayer, S. A., and Altman, J. Hippocampal development in the rat: cytogenesis and morphogenesis examined with autoradiography and low-level x-irradiation. J. Comp. Neurol. 158: 55–80 (1974).
24. Bayer, S. A., Yackel, J. W., and Puri, P. S. Neurons in the rat dentate gyrus granular layer substantially increase during juvenile and adult life. Science 216: 890–892 (1981).
25. Bayer, S. A., Brunner, R. L., Hine, R., and Altman, J. Behavioral effects of interference with the postnatal acquisition of hippocampal granule cells. Nat. New Biol. 242: 222–224 (1973).
26. Bayer, S. A., and Altman, J. Radiation-induced interference with postnatal hippocampal cytogenesis in rats and its long-term effects on the acquisition of neurons and glia. J. Comp. Neurol. 163: 1–20 (1975).
27. Peters, P. J., and Brunner, R. L. Increased running wheel activity and dyadic behavior of rats with hippocampal granule cell deficits. Behav. Biol. 16: 91–97 (1976).
28. Bulut, F. G. The effects of postnatal interference with cerebellar or hippocampal development on spatial and brightness discrimination learning in infant, juvenile, young-adult and adult rats. Unpublished Doctoral Dissertation, Purdue University, West Lafayette, IN, 1976.
29. Gazzara, R. A., and Altman, J. Early postnatal x-irradiation of the hippocampus and discrimination learning in adult rats. J. Comp. Physiol. Psychol. 95: 484–495 (1981).
30. Altman, J. An animal model of minimal brain dysfunction. In:

Learning Disabilities and Prenatal Risk (M. Lewis, Ed.), University of Illinois Press, Urbana, IL, 1986, pp. 241–304.
31. Courchesne, E., Hesselink, J. R., Jernigan, T. L., and Yeung-Courchesne, R. Abnormal neuroanatomy in a non-retarded person with autism: unusual findings with magnetic resonance imaging. Arch. Neurol., in press.
32. Strauss, A. A., and Lehtinen, L. E. Psychopathology and Education of the Brain-Injured Child. Grune and Stratton, New York, 1947.
33. Strauss, A. A., and Kephart, N. C. Psychopathology and Education of the Brain-Injured Child, Volume II. Progress in Theory and Clinic. Grune and Stratton, New York, 1955.
34. Gesell, A., and Amatruda, C. S. Developmental Diagnosis, Second Edition. Hoeber, New York, 1947.
35. Laufer, M. W., and Denhoff, E. Hyperkinetic behavior syndrome in children. J. Pediatr. 50: 463–474 (1957).
36. Pasamanick, B., and Knobloch, H. Syndrome of minimal cerebral damage in infancy. JAMA 170: 1384–1387 (1959).
37. Bax, M., and MacKeith, R., Eds. Minimal Cerebral Dysfunction. Heinemann, London, 1963.
38. Pond, D. Is there a syndrome of "brain damage" in children? Cerebral Palsy Bulletin 2: 296–297 (1960).
39. Birch, H. G. The problem of "brain damage" in children. In: Brain Damage in Children: The Biological and Social Aspects (H. G. Birch, Ed.), Williams and Wilkins, Baltimore, MD, 1964.
40. Shirley, M. A behavior syndrome characterizing prematurely born children. Child Dev. 10: 115–128 (1939).
41. Lubchenco, L. O., Horner, F. A., Reed, L. H., His, I. E., Metcalf, D., Cohig, B., Elliott, H. C., and Bourg, M. Sequelae of premature birth. Am. J. Dis. Child. 106: 101–115 (1963).
42. Dann, M., Levine, S. Z., and New, E. V. A long-term follow-up study of small premature infants. Pediatrics 33: 945–955 (1964).
43. Drillien, C. M. The Growth and Development of the Prematurely Born Infant. Williams and Wilkins, Baltimore, MD, 1964.
44. Drillien, C. M. Aetiology and outcome in low birth weight infants. Dev. Med. Child Neurol. 14: 563–573 (1972).
45. Wiener, G., Rider, R. V., Oppel, W. C., and Harper, P. A. Correlates of low birth weight. Psychological status at eight to ten years of age. Pediatr. Res. 2: 110–118 (1968).
46. Neligan, G., Scott, D. M., Kolvin, I., and Garside, R. C. Born too soon or born too small. Clinics in Developmental Medicine, No. 61 (1976).
47. Davie, R., Butler, N. R., and Goldstein, H. From Birth to Seven. Longmans, London, 1972.
48. Butler, N. R., and Goldstein, H. Smoking in pregnancy and subsequent child development. Br. Med. J. 4: 573 (1973).
49. Denson, R., Nanson, J. L., and McWatters, M. A. Hyperkinesis and maternal smoking. Can. Psych. Assoc. J. 20: 183–187 (1975).
50. Nichols, P. L., and Chen, T.-C. Minimal Brain Dysfunction: A Prospective Study. Erlbaum, Hillsdale, NJ, 1981.
51. Stone, M. L., Salerno, L. J., Green, M., and Zelson, C. Narcotic addiction in pregnancy. Am. J. Obstet. Gynecol. 109: 716–723 (1971).
52. Zelson, C. Infant of the addicted mother. N. Engl. J. Med. 288: 1393–1395 (1973).
53. Kandall, S. R., Album, S., Dreyer, E., Comstock, M., and Lowinson, J. Differential effects of heroin and methadone on birth weights. Addict. Dis. 2: 347–355 (1975).
54. Fricker, H. S., and Segal, S. Narcotic addiction, pregnancy, and the newborn. Am. J. Dis. Child. 132: 360–366 (1978).
55. Naeye, K. L., Blanc, W., Leblanc, W., and Khatamee, M. A. Fetal complications of maternal heroin addiction: abnormal growth, infections and episodes of stress. J. Pediatr. 83: 1055–1061 (1973).
56. Connaughton, J. F., Finnegan, L. P., Schur, J., and Emrich, J. P. Current concepts in the management of the pregnant opiate addict. Addict. Dis. 2: 21–36 (1975).
57. Zelson, C., Rubio, E., and Wasserman, E. Neonatal narcotic addiction: ten-year observation. Pediatrics 48: 178–189 (1971).
58. Davis, M. M., and Shanks, B. Neurological aspects of perinatal narcotic addiction and methadone treatment. Addict. Dis. 2: 213–226 (1975).
59. Desmond, M. M., and Wilson, G. S. Neonatal abstinence syndrome: recognition and diagnosis. Addict. Dis. 2: 113–121 (1975).
60. Wilson, G. S., Desmond, M. M., and Verniaud, N. M. Early development of infants of heroin-addicted mothers. Am. J. Dis. Child. 126: 457 (1973).
61. Ting, R., Keller, A., Berman, P., and Finnegan, L. P. Follow-up studies of infants born to methadone-dependent mothers. Pediatr. Res. 8: 346 (1974).
62. Ramer, C. M., and Lodge, A. Neonatal addiction. A two-year study. Part I. Addict. Dis. 2: 227–234 (1975).
63. Byers, R. K., and Lord, E. E. Late effects of lead poisoning on mental development. Am. J. Dis. Child. 66: 471–494 (1943).
64. Thurston, D. L., Middlekamp, J. N., and Mason, E. The late effects of lead poisoning. J. Pediatr. 47: 413–423 (1955).
65. White, H. H., and Fowler, F. D. Chronic lead encephalopathy: a diagnostic consideration in mental retardation. Pediatrics 25: 309–315 (1960).
66. Wiener, G. The relationship of birth weight and length of gestation to intellectual development at ages 8 to 10 years. J. Pediatr. 76: 694–699 (1970).
67. David, O., Clark, J., and Voeller, K. Lead and hyperactivity. Lancet 2: 900–903 (1972).
68. David, O. J. Association between lower lead concentrations and hyperactivity in children. Environ. Health Perspect. 7: 17–25 (1974).
69. Landrigan, P. J., Whitworth, R. H., Boloh, R. W., Staehling, N. W., Barthel, W. F., and Rosenblum, B. F. Neuropsychological dysfunction in children with chronic low-level lead absorption. Lancet 2: 708–712 (1975).
70. Zarkowsky, H. S. The lead problem in children: dictum and polemic. Curr. Probl. Pediatr. 6: 1–47 (1976).
71. Needleman, H. L., Gunnoe, C., Leviton, A., Reed, R., Peresie, H., Maher, C., and Barret, P. Deficits in psychologic and classroom performance of children with elevated dentine lead levels. N. Engl. J. Med. 300: 689–695 (1979).
72. Pentschew, A. Morphology and morphogenesis of lead encephalopathy. Acta Neuropathol. 5: 133–160 (1965).
73. Silbergeld, E. K., and Goldberg, A. M. A lead-induced behavioral disorder. Life Sci. 13: 1275–1283 (1973).
74. Silbergeld, E. K., and Goldberg, A. M. Lead-induced behavioral dysfunction: an animal model of hyperactivity. Exp. Neurol. 42: 146–157 (1974).
75. Sauerhoff, M. W., and Michaelson, I. A. Hyperactivity and brain catecholamines in lead-exposed developing rats. Science 182: 1022–1024 (1973).
76. Sobotka, T. J., and Cook, M. P. Postnatal lead acetate exposure in rats: possible relationship to minimal brain dysfunction. Am. J. Ment. Defic. 79: 5–9 (1974).
77. Driscoll, J. W., and Stegner, S. E. Lead produced changes in the relative rate of open field activity of laboratory rats. Pharmacol. Biochem. Behav. 8: 743–747 (1976).
78. Petit, T. L., and Alfano, D. P. Differential experience following developmental lead exposure: effects on brain and behavior. Pharmacol. Biochem. Behav. 11: 165–171 (1979).
79. Snowdon, C. T. Learning deficits in lead-injected rats. Pharmacol. Biochem. Behav. 1: 599–603 (1973).
80. Brown, D. R. Neonatal lead exposure in the rat: decreased learning as a function of age and blood lead concentrations. Toxicol. Appl. Pharmacol. 32: 628–637 (1975).
81. Brady, K., Herrera, Y., and Zenick, H. Influences of parental lead exposure on subsequent learning ability of offspring. Pharmacol. Biochem. Behav. 3: 561–565 (1975).
82. Alfano, D. P., and Petit, T. L. Behavioral effects of postnatal lead exposure: possible relationship to hippocampal dysfunction. Behav. Neural Biol. 32: 319–333 (1981).
83. Pentschew, A., and Garro, F. Lead encephalo-myelopathy of the suckling rat and its implications on the porphyrinopathic nervous diseases. Acta Neuropathol. 6: 266–278 (1966).
84. Thomas, J. A., Dallenbach, F. D., and Thomas, M. The distribution of radioactive lead (^{210}Pb) in the cerebellum of developing rats. J. Pathol. 109: 45–50 (1973).
85. Goldstein, G. W., Asbury, A. K., and Diamond, I. Pathogenesis

of lead encephalopathy uptake of lead and reaction of brain capillaries. Arch. Neurol. 31: 382–389 (1974).
86. Krigman, M. R., Mushak, P., and Bouldin, T. W. An appraisal of rodent models of lead encephalopathy. In: Neurotoxicology (L. Roisin, H. Schiraki, and N. Grecivic, Eds.), Raven Press, New York, 1977, pp. 299–302.
87. Press, M. Lead encephalopathy in neonatal Long-Evans rats: morphologic studies. J. Neuropathol. Exp. Neurol. 36: 169–193 (1977).
88. Toews, A. D., Kolber, A., Hayward, J., Krigman, M. R., and Morell, P. Experimental lead encephalopathy in the suckling rat: concentration of lead in cellular fractions enriched in brain capillaries. Brain Res. 147: 131–138 (1978).
89. Collaborative Perinatal Project. Collaborative study of cerebral palsy, mental retardation, and other neurologic and sensory disorders of infancy and childhood. Public Health Service, Bethesda, MD, 1965.
90. Yakovlev, P. I., and Rosales, R. K. Distribution of the terminal hemorrhages in the brain wall in stillborn, premature and nonviable neonates. In: Physical Trauma as an Etiologic Agent in Mental Retardation (R. Angle and E. A. Bering, Eds.), U.S. Government Printing Office, Washington, DC, 1970.
91. Towbin, A. Central nervous system damage in the human fetus and newborn infant. Am. J. Dis. Child. 119: 529–542 (1970).
92. Hambleton, G., and Wigglesworth, J. S. Origin of intraventricular hemorrhage in the preterm infant. Arch. Dis. Child. 51: 651 (1976).
93. Papile, L. A., Burstein, J., Burstein, R., and Koffler, H. Incidence and evolution of subependymal and intraventricular hemorrhage: a study of infants with less than 1,500 gm. J. Pediatr. 92: 529–534 (1978).
94. Volpe, J. J. Neurology of the Newborn. Saunders, Philadelphia, 1981.
95. Towbin, A. Organic causes of minimal brain dysfunction. Perinatal origin of minimal cerebral lesions. JAMA 217: 1207–1214 (1971).
96. Towbin, A. Neuropathologic factors in minimal brain dysfunction. In: Handbook of Minimal Brain Dysfunctions (H. E. Rie and E. D. Rie, Eds.), Wiley, New York, 1980, pp. 185–209.
97. Snider, R. S., and Stowell, A. Receiving areas of the tactile, auditory, and visual systems in the cerebellum. J. Neurophysiol. 7: 331–357 (1944).
98. Aitkin, L. M., and Boyd, J. Responses of single units in cerebellar vermis of the cat to nonaural and binaural stimuli. J. Neurophysiol. 38: 418–429 (1975).
99. Huang, C. M., Liu, G., and Huang, R. Projections from the cochlear nucleus to the cerebellum. Brain Res. 244: 1–8 (1982).
100. Ron, S., and Robinson, A. Eye movements evoked by cerebellar stimulation in the alert monkey. J. Neurophysiol. 36: 1004–1022 (1973).
101. Kase, M., Noda, H., Suzuki, D. A., and Miller, D. C. Target velocity signals of visual tracking in vermal Purkinje cells of the monkey. Science 205: 717–720 (1979).
102. Suzuki, D. A., Noda, H., and Kase, M. Visual and pursuit eye movement-related activity in posterior vermis of monkey cerebellum. J. Neurophysiol. 46: 1120–1139 (1981).
103. Ito, M. The Cerebellum and Neural Control. Raven Press, New York, 1984.
104. Raaf, J., and Kernohan, J. W. A study of the external granular layer in the cerebellum. Am. J. Anat. 75: 151–172 (1944).
105. Douglas, J. W. B. Mental ability and school achievement of premature children at 8 years of age. Br. Med. J. 1: 1210 (1956).
106. Kawi, A. A., and Pasamanick, B. Association of factors of pregnancy with reading disorders in childhood. JAMA 166: 1420–1423 (1958).
107. Fitzhardinge, P. M., and Steven, E. M. The small for dates infant. Neurological and intellectual sequelae. Pediatrics 50: 50 (1972).
108. Drillien, C. M. Fresh approaches to prospective studies of high risk infants. Pediatrics 45: 7–8 (1970).
109. Schain, R. J. Medical and neurological differential diagnosis. In: Handbook of Minimal Brain Dysfunctions (H. E. Rie and E. D. Rie, Eds.), Wiley, New York, 1980, pp. 388–406.