Environmental Health Perspectives
Vol. 77, pp. 5-9, 1988

The Use of Rabbits in Male Reproductive Toxicology

by Daniel Morton*

The rabbit is the smallest and least expensive laboratory animal in which serial semen samples can be obtained for morphologic, biochemical, and fertility evaluation. The female rabbit has a predictable reproductive cycle and can be artificially inseminated with a known amount of sperm during fertility testing. These advantages make the rabbit an extremely valuable model for studying the effects of chemicals or other stimuli on the male reproductive system. Quantitative evaluation of the testis, semen, and accessory reproductive organs is important in order to detect subtle effects of a chemical on reproductive capacity. Evaluation of testis size, serum hormone concentrations, and the number, morphology, motility, and fertility of sperm in the ejaculate can be performed serially in the live rabbit. Weights of testes and accessory reproductive organs, estimates of daily sperm production, and histomorphometric data on the seminiferous epithelium can be obtained after sacrifice. Multinucleated spermatids, focal tubular hypospermatogenesis, swelling of spermatocytes, and cytoplasmic vacuoles in Sertoli's cells occur commonly in testes of control rabbits. These changes may be confused with toxic lesions. The incidence of multinucleated spermatids may be increased by stress associated with handling or the environment. Histomorphometric evaluation may be required to prove that a test compound has an adverse effect on the male reproductive system.

Introduction

Rabbits are excellent models for many aspects of research in reproductive toxicology. Advantages of using the rabbit in reproductive toxicologic studies include: (a) The male rabbit is the smallest, least expensive animal that can be ejaculated with an artificial vagina, permitting longitudinal evaluation of semen. (b) Normal reproductive processes, including normal morphology, the cycle of the spermatogenic epithelium, and testicular maturation, are documented in the literature (*1–4*). (c) The female can be artificially inseminated and has a predictable reproductive cycle. (d) Rabbits are easy to handle. These advantages permit longitudinal evaluation of sperm production, semen morphology and biochemistry, and longitudinal fertility testing with known numbers of diluted spermatozoa.

Rabbits are often introduced into studies before they reach sexual maturity. This may be an advantage if the maximum susceptibility to a test compound is desired. The spermatogonia start to divide at 7 to 8 weeks of age, the blood-testis barrier forms by 10 weeks of age (*4*), the testes descend and the tubules develop lumina at 12 weeks of age, and spermatids and spermatocytes are first seen at 14 to 15 weeks of age (*3*). Tubules appear histologically mature by 18 weeks of age (*5*). The testes continue to grow and increase sperm production until 6 months of age. Strain-related variation in the time required for maturation of the testis has been reported (*6*).

In the rabbit, eight cellular associations of developing male gametes are recognized in histologic sections of seminiferous tubules (*2*). These eight associations make up the spermatogenic cycle, diagrammed in Figure 1. The length of the cycle of the seminiferous epithelium lasts 10.7 days in the rabbit. Approximately 48 days, or 4.5 cycles, are required for a committed Type A spermatogonium to differentiate into mature spermatozoa that are released into the lumen of the seminiferous tubule (*1*). An additional 10 to 14 days (1 to 1.5 cycles) are required for the spermatozoa to pass through the epididymis into the ejaculate.

The cycle of the seminiferous epithelium has implications in the design of testing protocols for studying the effects of an agent on the male reproductive system. Amann recommends that in subchronic toxicity studies, exposure to a test compound should continue for at least 6 cycles of the epithelium before animals are sacrificed or fertility tested (*1*). In the rabbit, this would require 64 days. In the rat, this would require 77 days. Six cycles allow sufficient time for the agent to accumulate in tissues, exert its effect, and produce changes in the sperm in the ejaculate. The maximum effect would be produced at this time, and the histologic lesions would be maximally visible. If recovery of fertility is to be assessed, an additional 12 cycles (128 days in the rabbit) without treatment should allow sufficient time for recovery.

*Department of Veterinary Pathobiology, University of Illinois, Urbana, IL 61801.

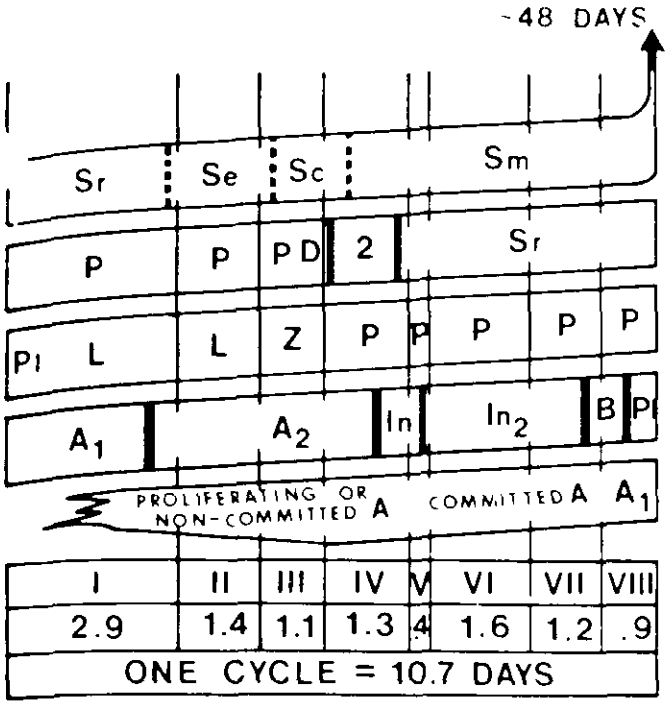

FIGURE 1. The cycle of the seminiferous epithelium in the rabbit. In this chart, the basement membrane is at the bottom and the lumen of the seminiferous tubules at the top. Each of the five upper rows represents one generation of germ cells that are increasingly (from bottom to top) more mature. The columns represent the eight cellular associations that have been described for the rabbit (*2*). The germ cells present in each cellular association can be discerned by reading up in each column. The complete series of cellular associations is termed the cycle of the seminiferous epithelium. In the rabbit, the duration of one cycle of seminiferous epithelium is 10.7 days. The duration of each cellular association also is shown. Since approximately 4.5 cycles of the seminiferous epithelium pass between commitment of an A-spermatogonium to differentiate and produce more advanced types of spermatogonia and the release of the resulting spermatozoa from the germinal epithelium, the duration of the spermatogenesis is 48 days in the rabbit. Reprinted with permission (*1*).

Methods

Quantitative evaluation of the male reproductive organs permits the detection of some lesions that may be overlooked using only qualitative evaluation. Sensitive comparisons of sequential stages of a lesion or comparisons between lesions caused by different agents can be made using quantitative techniques. Amann reviewed various quantitative methods for evaluating the male reproductive system (*1*). In living animals, testis size can be measured, and sequential semen samples can be collected for quantitative assessment of the number and motility of the sperm, the percentage of various morphologic defects, and biochemical parameters.

Testis size is closely correlated to daily sperm production. Fertility testing can be performed by artificially inseminating female rabbits with diluted semen containing known numbers of spermatozoa. Serum hormone concentrations can be assayed. In sacrificed animals, decreased weights of testes indicate widespread or diffuse loss of seminiferous epithelial cells. Reduced weights of accessory sex organs usually indicate reduced androgen stimulation. Homogenization of a known weight of fresh testis ruptures all nuclei except the condensed, elongated spermatid nuclei. The number of homogenization-resistant spermatid nuclei per gram of testis can be used to estimate daily sperm production.

Daily sperm production can also be determined by histomorphometric methods (*7*). Histologically, approximately 8% of the tubules in a normal rabbit should contain mature spermatids lining the tubular lumen, and a reduction in the number of tubules with mature spermatids suggests degeneration and loss of cells. A decrease in the average minimum tubular diameter of 30 to 50 nearly round cross-sections of seminiferous tubules may be used to quantitate the loss of the seminiferous epithelium in some degenerative and toxic lesions. Loss of spermatogenic epithelial cells prior to the leptotene stage can be quantitated by comparing the numbers of leptotene spermatocytes per Sertoli cell nucleus in treated and control testes.

Proper fixation is critical for detailed histologic evaluation of the seminiferous epithelium. Embedding of formalin-fixed tissue in paraffin creates shrinkage artifacts and distorts nuclear and acrosomal morphology, precluding meaningful histologic evaluation (*1,8*). Bouin's or Helly's fixatives are preferred for testicular tissue to be embedded in paraffin (*9*); however, neutral-buffered formalin is an excellent fixative for testes to be embedded in glycol methacrylate (*9*). Glutaraldehyde or Karnovsky's fixative can be used for tissue to be embedded in epoxy. Epoxy-embedded tissue can be cut to 1-μm sections or used for electron microscopy. For testis embedded in paraffin or glycol methacrylate, hematoxylin and Periodic acid-Schiff (PAS) stains are used to stain the nuclei and acrosomes, respectively, to determine specific stages of the spermatogenic cycle. Eosin staining does not permit visualization of the acrosome, and therefore the stages of spermatogenesis cannot be identified and stage-specific lesions may be missed. Toluidine blue permits the recognition of different cell types in epoxy sections.

Common Histologic Changes

Multinucleated spermatids, focal tubular hypospermatogenesis, swelling of spermatocytes, and clear cytoplasmic vacuoles within Sertoli's cells are commonly seen in histologic sections of testes of control rabbits used in percutaneous toxicity studies and in rabbits not used in any previous studies (*5,10*). These changes often are considered to be evidence of degeneration and may be confused with toxic lesions. The incidences of these changes in control rabbits are summarized in Table 1.

Multinucleated spermatids, also called spermatid giant cells, are observed in 94% of the testes from rabbits in the 91-day studies (Fig. 2) (*10*). Multinucleated spermatids are round, swollen, eosinophilic cells formed by widening of the narrow intracytoplasmic bridges that normally connect clonal spermatogenic epithelial cells

Table 1. Incidence of histologic alterations in the testes of control rabbits.[a]

Alteration	Incidence, %
Multinucleated spermatids	94
Hypospermatogenesis	22
Spermatocyte swelling	86
Cytoplasmic vacuoles	61

[a]Formalin-fixed, routinely processed, paraffin-embedded testes of rabbits from 91-day percutaneous toxicity studies from five different laboratories and several breeders were examined semiquantitatively. Rabbits were killed at approximately 26 weeks of age (*10*).

from the spermatogonial stages through the maturation of the spermatids (*3,5,11,12*). These cells usually are found free in the tubular lumen, but occasionally can be seen embedded in the seminiferous epithelium. Most multinucleated spermatids have several round, condensed or pyknotic nuclei, but larger cells occasionally have as many as 40 nuclei. When large numbers of nuclei are present, they usually line the periphery of the cytoplasm.

Rabbits serving as controls in percutaneous toxicity studies had more multinucleated spermatids in their seminiferous tubules than did rabbits that were sacrificed without manipulation (*5,10*). While multinucleated spermatids are generally considered a degenerative or dystrophic change (*12*), they have been reported in the testes of clinically normal mice, rabbits, and men (*12–14*). Normal attrition of spermatogenic epithelial cells in the rabbit has been estimated to result in a loss of about 24% of the potential spermatids during the meiotic divisions (*2*). The presence of some degenerating spermatids is not surprising. The number of multinucleated spermatids and the number of tubules containing these cells vary tremendously within control rabbits. Starvation, thermal stress, surgical procedures, local injury, and experimental cryptorchidism have been reported to increase the number of multinucleated spermatids in rabbits (*12,13*). It is possible that nonspecific stressors may increase the formation of multinucleated spermatids, possibly by increasing cortisol concentrations in the serum, which subsequently decrease testosterone production (*15*). Administration of a test compound may indirectly cause increased formation of multinucleated spermatids through nonspecific stress, or it may directly affect the testis. Because these changes are so variable in control rabbits, quantitative evaluation of numerous testes may be necessary to detect mild degenerative changes caused by toxic agents.

Multifocal tubular hypospermatogenesis occurs in 22% of the rabbits in 91-day studies (*10*). Hypospermatogenesis is defined as thinning of the spermatogenic epithelium to two or fewer layers. Often one or a few small triangular clusters of hypospermic tubules are found just beneath the capsule, but these clusters can occur anywhere (Fig. 3). Occasionally, single tubules are affected, and these tubules are difficult to distinguish from tubules with artifactual loss of the epithe-

FIGURE 2. Multinucleated spermatids in a seminiferous tubule. Bar = 10 μm.

FIGURE 3. Hypospermatogenesis in a cluster of tubular cross-sections. Bar = 200 μm.

lium. The diameters of these tubules do not differ from the diameters of adjacent normal tubules, demonstrating that loss of seminiferous epithelium is not always accompanied by decreased tubular diameters.

Spermatocyte swelling and intracytoplasmic vacuolation of Sertoli's cells are seen in most rabbits. Affected spermatocytes have clear cytoplasm and eccentric, often pyknotic, nuclei (Fig. 4). Ultrastructurally, the cytoplasm is electron lucent, the nuclear chromatin is coarsely clumped, and the cytoplasmic membrane often is disrupted. Similar changes are observed in testes perfused with glutaraldehyde (*5*). These changes indicate degeneration of spermatocytes. In most affected tubules, the majority of the deep spermatocytes in the basal layer of nuclei are affected. Adjacent tubules often are not affected.

Vacuoles within Sertoli's cell cytoplasm occasionally are large and coalescing (Fig. 5). Ultrastructurally, these vacuoles are distended endoplasmic reticulum.

In one study, rabbit testes fixed by immersion in neutral-buffered formalin were compared to contralateral testes that were perfused with cold 2% glutaraldehyde (*5*). The formalin-fixed testes contained severe shrinkage artifact and nuclear clumping of chromatin, which made many cell types impossible to identify, but there were no significant differences in the frequencies of multinucleated spermatids, focal tubular hypospermatogenesis, swelling of spermatocytes, and cytoplasmic vacuoles in testes fixed with formalin or glutaraldehyde. Therefore, formalin fixation does not result in artifactual formation of multinucleated spermatids, hypospermatogenesis, spermatocyte swelling, and vacuoles within Sertoli's cells. However, the stages of the cycle of the seminiferous epithelium cannot be accurately identified in formalin-fixed, paraffin-embedded sections stained with hematoxylin and eosin, whereas they can be easily recognized in testes perfused with glutaraldehyde. Formalin-fixed, paraffin-embedded sections stained with hematoxylin and eosin are not adequate to detect subtle lesions or characterize the cell types involved in more severe lesions of the testis in routine toxicologic studies.

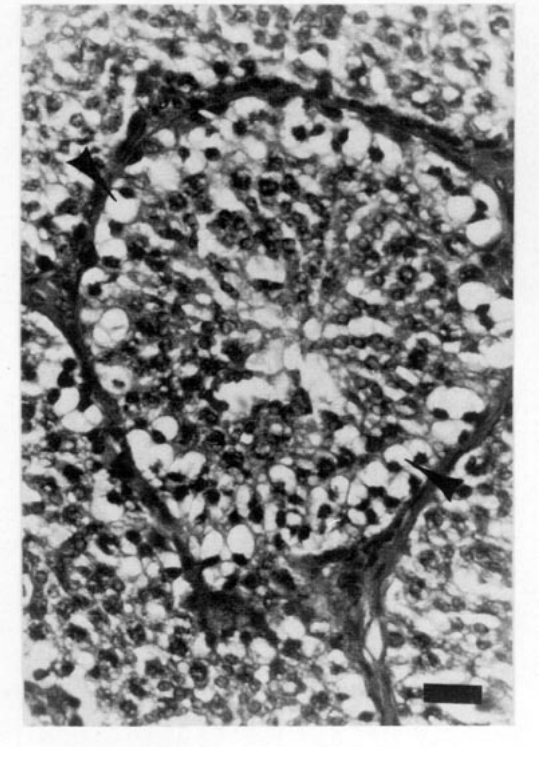

FIGURE 4. Cytoplasmic swelling of degenerating spermatocytes (arrowheads). Bar = 10 μm.

FIGURE 5. Intracytoplasmic vacuoles in Sertoli's cells (arrowheads). Bar = 10 μm.

Conclusions

In summary, rabbits are valuable animal models for the study of male reproductive toxicology and pathology. Advantages include the ability to serially ejaculate male rabbits, permitting longitudinal studies of fertility and semen characteristics, the ability to artificially inseminate females, the reasonable expense and availability of rabbits, and documentation of reproductive processes in the literature. Histologic evaluation of testes in routine toxicologic studies is complicated by the common and variable occurrence of multinucleated spermatids, focal tubular hypospermatogenesis, spermatogonial swelling, and vacuolation of Sertoli's cells. These changes are nonspecific degenerative changes that occur in the testes of normal rabbits and may be increased during stress. These changes may be difficult to distinguish from lesions induced by a test compound. Quan-

titative evaluation of the semen, testes, and accessory reproductive organs may be required to prove that a test compound has an adverse effect on the reproductive system.

This work was funded in part by the Procter and Gamble Company. The author acknowledges the expert technical assistance of William E. Wyder.

REFERENCES

1. Amann, R. P. Use of animal models for detecting specific alterations in reproduction. Fundam. Appl. Toxicol. 2: 13–26 (1982).
2. Swierstra, E. E., and Foote, R. H. Cytology and kinetics of spermatogenesis in the rabbit. J. Reprod. Fertil. 5: 309–322 (1963).
3. Gondos, B., Renston, R. H., and Conner, L. A. Ultrastructure of germ cells and Sertoli cells in the postnatal rabbit testis. Am. J. Anat. 136: 427–440 (1978).
4. Sun, E. L., and Gondos, B. Formation of the blood-testis barrier in the rabbit. Cell Tissue Res. 243: 575–578 (1986).
5. Morton, D., Weisbrode, S. E., Wyder, W. E., Maurer, J. K., and Capen, C. C. Spermatid giant cells, tubular hypospermatogenesis, spermatogonial swelling, cytoplasmic vacuoles, and tubular dilatation in the testes of normal rabbits. Vet. Pathol. 23: 176–183 (1986).
6. Ford, L. Comparison of testicular maturation in two inbred rabbit lines. Am. J. Vet. Res. 31: 941–945 (1970).
7. Amann, R. P. The male rabbit. IV. Quantitative testicular histology and comparisons between daily sperm production as determined histologically and daily sperm output. Fertil. Steril. 21: 662–672 (1970).
8. Amann, R. P. Detection of alterations in testicular and epididymal function in laboratory animals. Environ. Health Perspect. 70: 149–158 (1986).
9. Chapin, R. E., Ross, M. D., and Lamb, J. C. Immersion fixation methods for glycol methacrylate-embedded testes. Toxicol. Pathol. 12: 221–227 (1984).
10. Morton, D., Weisbrode, S. E., Wyder, W. E., Maurer, J. K., and Capen, C. C. Histologic alterations in the testes of laboratory rabbits. Vet. Pathol. 23: 214–217 (1986b).
11. Dym, M., and Fawcett, D. W. Further observations on the numbers of spermatogonia, spermatocytes, and spermatids connected by intercellular bridges in the mammalian testis. Biol. Reprod. 4: 195–215 (1971).
12. Benitz, K. F., and Dambach, G. The toxicologic significance of multinucleated giant cells in dystrophic testes of laboratory animals and man. Arzneim. Forsch. 15: 391–404 (1965).
13. Ploen, L. An electron microscope study of the delayed effects on rabbit spermateleosis following experimental cryptorchidism for twenty-four hours. Virchows Arch. Abt. B Zellpathol. 14: 159–184 (1973).
14. Holstein, A. F., and Eckmann, C. Multinucleated spermatocytes and spermatids in human seminiferous tubules. Andrologia 18: 5–16 (1986).
15. McGrady, A. V. Effects of psychologic stress on male reproduction, a review. Arch. Androl. 13: 1–7 (1984).