Environmental Health Perspectives
Vol. 77, pp. 23-28, 1988

Prostatic Carcinogenesis Evoked by Cellular Interaction

by Leland W. K. Chung,* Shi-Ming Chang,* Carol Bell,‡ Haiyen Zhau,* Jae Y. Ro,† and Andrew C. von Eschenbach*

Inoculation of tumorigenic prostatic stroma and nontumorigenic prostatic epithelia into the subcutaneous space of syngeneic rats induced the development of carcinosarcoma. The induced tumors, which were composed of a mixture of adenocarcinoma and fibrosarcoma, were androgen responsive. This model offers a novel mechanism for prostatic carcinogenesis in which prostatic fibroblasts determine epithelial growth, androgen responsiveness, and tumorigenicity. Our results emphasize the potential importance of an epigenetic pathway in prostatic carcinogenesis.

Introduction

Cellular interaction between stroma and epithelium are the key determinants during normal development for morphogenesis, cytodifferentiation, and hormonal responsiveness in most glandular tissues in vertebrate species (*1–5*). Classical approaches to deciphering the underlying mechanisms of cellular interactions often rely on successfully dissecting and dissociating embryonic tissues and recombining them either homotypically or heterotypically. This laboratory and others have employed this technology for the study of the regulation and growth of the prostate gland (*6,7*) or regression of the mammary gland (*8*) induced by androgenic steroids. These earlier studies have led to the general conclusion that androgen receptors in the stroma, rather than in the epithelium, are essential to androgen action during normal development.

To understand the cellular and biochemical basis of stromal-epithelial interactions and the possible involvement of chemical signals between these tissues, we have taken the approach of establishing cell lines from rat ventral prostate gland. We have studied the androgen responsiveness of prostatic cells in culture and *in vivo*. We report here our observation that an androgen-responsive tumorigenic fibroblast cell line induced a nontumorigenic epithelial cell line to form an adenocarcinoma. The tumors that resulted from the SC injections of mixtures of fibroblasts and epithelia were histologically characterized as carcinosarcoma and were composed of mixtures of adenocarcinoma and fibrosarcoma. These tumors were found to be androgen responsive *in vivo*. This observation emphasized the role of the stromal component in determining androgen responsiveness and its involvement in initiating epithelial cancer development.

Establishment of Rat Prostatic Epithelial and Fibroblast Cell Lines

Rat prostatic cell lines were established by a slight modification of a procedure described by Phillips and Rice (*9*). In brief, ventral prostate glands obtained from intact adult male rats (inbred Nb-strain) were cut into 1-mm cubes with scissors. The tissue fragments were placed on Falcon plastic dishes (Becton Dickinson Labware, Lincoln Park, NJ) and submerged in tissue culture T-medium [Dulbecco's modified Eagle medium: F-12K (4:1), fetal bovine serum (5%), biotin (0.244 μg/mL), adenine (25 μg/mL), insulin (5 μg/mL), transferrin (5 μg/mL), choleratoxin (10 ng/mL), epidermal growth factor (10 ng/mL), and hydrocortisone (0.4 μg/mL)]. Prostatic epithelia were separated from their adjacent fibroblasts by removing differentially the loosely attached fibroblasts with phosphate-buffered saline containing ethylene diamine tetracetic acid disodium salt (EDTA). The epithelial cells attached to the plastic dishes were removed by digestion with trypsin (2 mg/mL, Gibco, Grand Island, NY) and replated in T-me-

*Department of Urology, The University of Texas M. D. Anderson Hospital and Tumor Institute at Houston, 1515 Holcombe, Houston, TX 77030.
†Department of Pathology, The University of Texas M. D. Anderson Hospital and Tumor Institute at Houston, 1515 Holcombe, Houston, TX 77030.
‡Present address: Department of Molecular, Cellular and Developmental Biology, University of Colorado, Boulder, CO 80309.

dium. Morphologically distinct epithelial colonies, uncontaminated by fibroblast, were obtained after the fifth passage. Pure fibroblast culture without epithelial contamination was obtained by a procedure described previously (*10*). This procedure relied on the differential enzymatic digestion of fibroblast from minced prostatic tissues with 0.1% each of collagenase and hyaluronidase. In the present study, the morphology of fibroblasts was further confirmed by electron microscopic observation. The tumor-inducing spindle-shaped fibroblasts were stained blue by Masson's trichrome stain, indicating the lack of smooth muscle cells in the fibroblast preparation. Because the initial growth rate of the fibroblasts far exceeded that of the epithelia, a fibroblast cell line devoid of epithelial contamination was obtained before the third passage in 5% calf serum in DMEM (F-medium). Unless otherwise specified, the established fibroblast cell line, maintained for 11 to 36 passages, and the epithelial cell line, maintained for 30 to 34 passages, were used for this study.

Figure 1 represents the morphologic structure of the established rat prostatic epithelium and fibroblast. Only the cultured epithelium stained positively with antikeratin antibody. These cell lines were also characterized biochemically for the presence of testosterone 5α-reductase [NADPH: $^{4}\Delta$-3-ketosteriod 5α-oxido reductase (*11*)] and acid phosphatase activity (*12*). Both of these enzyme activities were found to be associated primarily with the epithelium. Activity in the cultured epithelial and fibroblast cells, respectively, was: testosterone 5α-reductase, 8.87 and 0.43 pmole/μg DNA; acid phosphatase, 17.8 and 1.06 unit/10^7 cells.

Androgen Responsiveness of Rat Prostatic Cell Lines

To determine if these cell lines were androgen responsive, we exposed the cultured epithelial or fibroblast cells to various concentrations of dihydrotestosterone (DHT) (0, 0.1, 1.0, 10, 100, 1000, and 10,000 ng/mL) in a downshift medium for 24 hr. The cells were then pulse-labeled for 2 hr with [methyl-^{3}H]-thymidine (4 Ci/mmole), and the rate of DNA synthesis activities was determined by collecting and counting the perchloric acid precipitates on Millipore filters. Figure 2 shows that DHT at a concentration of <1000 ng/mL stimulated DNA synthesis and increased cellular proliferation only in cultured prostatic fibroblasts. In contrast, DHT slightly inhibited [^{3}H]-thymidine incorporation and cellular proliferation in cultured epithelium. DHT at 10 μg/mL markedly inhibited the growth of both prostatic epithelial and fibroblast cells. The stimulatory action of DHT on cultured prostatic fibroblasts is androgen-receptor mediated because it can be inhibited by the antiandrogens cyproterone acetate and 4-hydroxy-flutamide (unpublished results).

Role of Tumorigenic Prostatic Fibroblasts on Prostatic Epithelial Cancer Development

Because the cultured prostatic epithelial and fibroblast cells proliferated quite well *in vitro*—their generation times were 13.4 and 17.3 hr, respectively—we

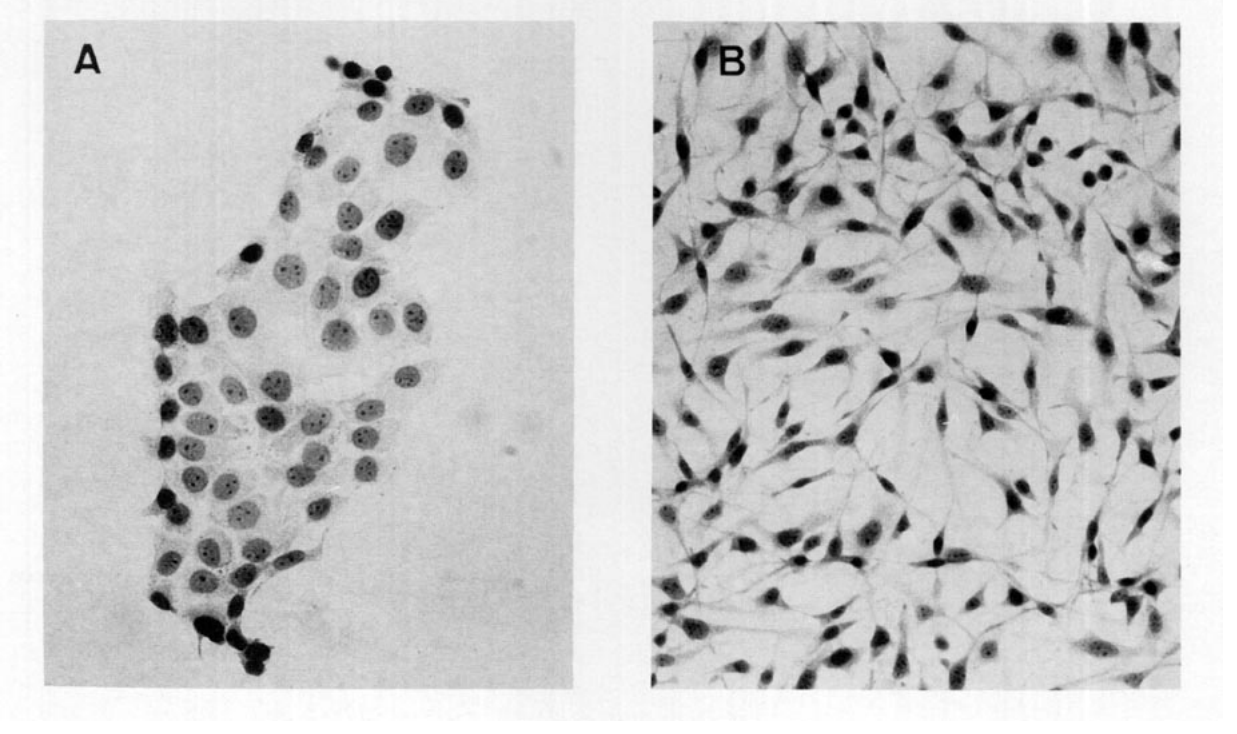

FIGURE 1. Typical morphologic characteristics of cultured prostatic epithelia (*A*) and fibroblasts (*B*) (× 1100). Only the cultured epithelia stained positively with antikeratin antibody.

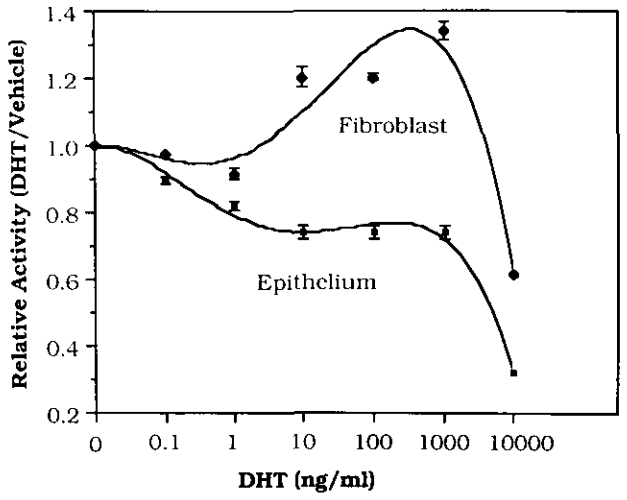

FIGURE 2. Effect of dihydrotestosterone (DHT) on cultured prostatic epithelia and fibroblasts. Prostatic cells (2×10^4 cells/well), seeded in 24-well plates, were downshifted to 0.4% bovine serum for 24 hr. DHT was then added to the culture medium, and the cells were incubated for an additional 24 hr. Each data point represents the rate of [^{3}H]-thymidine incorporation into cellular DNA (cpm/well) from four experiments (average ± SEM), except for DHT at 10^4 ng/mL, which represents the average of two determinations. Relative activity is expressed as the rate of [^{3}H]-thymidine incorporation into DHT-treated wells versus vehicle-treated controls.

decided to investigate whether these cells were tumorigenic *in vivo*. Figure 3 demonstrates that prostatic fibroblasts at later passages (e.g., the 24th to 36th passages) were tumorigenic; however, prostatic epithelial lines and/or early passages of prostatic fibroblasts (e.g., the 11th through 14th passages) were nontumorigenic (Fig. 3*A*). To determine if the tumorigenic fibroblasts could induce the nontumorigenic epithelia to become tumorigenic through cellular interaction, we injected cultured fibroblasts and epithelia together into the syngeneic male hosts. Figure 3*B* shows that the nontumorigenic epithelia could be induced to form adenocarcinoma only by the tumorigenic fibroblasts; nontumorigenic prostatic fibroblasts were completely ineffective. If the total number of cells inoculated into adult male hosts was kept constant (2×10^6 cells), the optimal ratios of fibroblasts/epithelia to form the largest size of tumor was 1:10. As few as 0.1% of the fibroblasts (2000 fibroblasts) among epithelia was sufficient to induce tumor formation (Fig. 3*C*). In these studies, no linear relationship was apparent between the size of the tumor formed and either the absolute number or the percent of either cell type present at the time of tumor inoculation (DNA content per milligram of tumor tissue was equivalent among all tumors examined). These results suggest that bidirectional cell-cell interaction may be the most likely mechanism to account for the increase in tumor volume.

We have examined the histologic composition of the tumors at the end of a 9-day growth period. Figure 4*A* shows that tumorigenic fibroblasts alone developed in to pure fibrosarcoma, whereas Figure 4*B* shows that the mixtures of fibroblasts and epithelia developed into carcinosarcoma. In the latter case, nontumorigenic epithelia, which were stained positively by the anticytokeratin antibody, were induced by the tumorigenic fibroblasts to divide and to form typical acini composed of adenocarcinoma mixed with sarcoma (Fig. 4*C*). In all of the tumors formed, we noted that the adenocarcinoma component is only a small fraction (2–5%) of the total

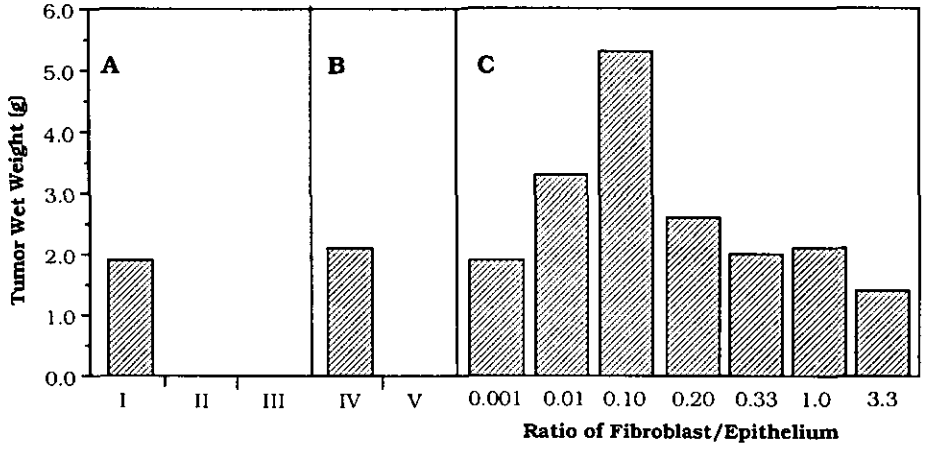

FIGURE 3. Induction of tumorigenesis in epithelia by their adjacent fibroblasts. Fibroblast and epithelial cells were inoculated either alone or in combination into the subcutaneous space of either the hind or the front legs of the animals. No preferential growth of the tumor was found in either of these areas. Unless otherwise stated, the tumors were harvested and weighed at the end of day 9 of growth. Data represent the average of 2 to 19 determinations. (*A*) Fibroblasts of the 24th to 36th passages were tumorigenic (column I, $n = 19$), but those of the 11th to 14th passages (column II, $n = 9$) and the epithelia of the 33rd passage (column III, $n = 6$) were nontumorigenic over an extended period (4 months) of observation. (*B*) Fifty percent mixtures of tumorigenic (column IV, $n = 2$), but not nontumorigenic (column V, $n = 4$), fibroblasts with the nontumorigenic epithelia induced the latter to form carcinosarcoma. (*C*) When the total number of cells inoculated was kept as a constant (2×10^6 cells/inoculation), 10% fibroblasts exhibited the greatest tumor growth-promoting effect.

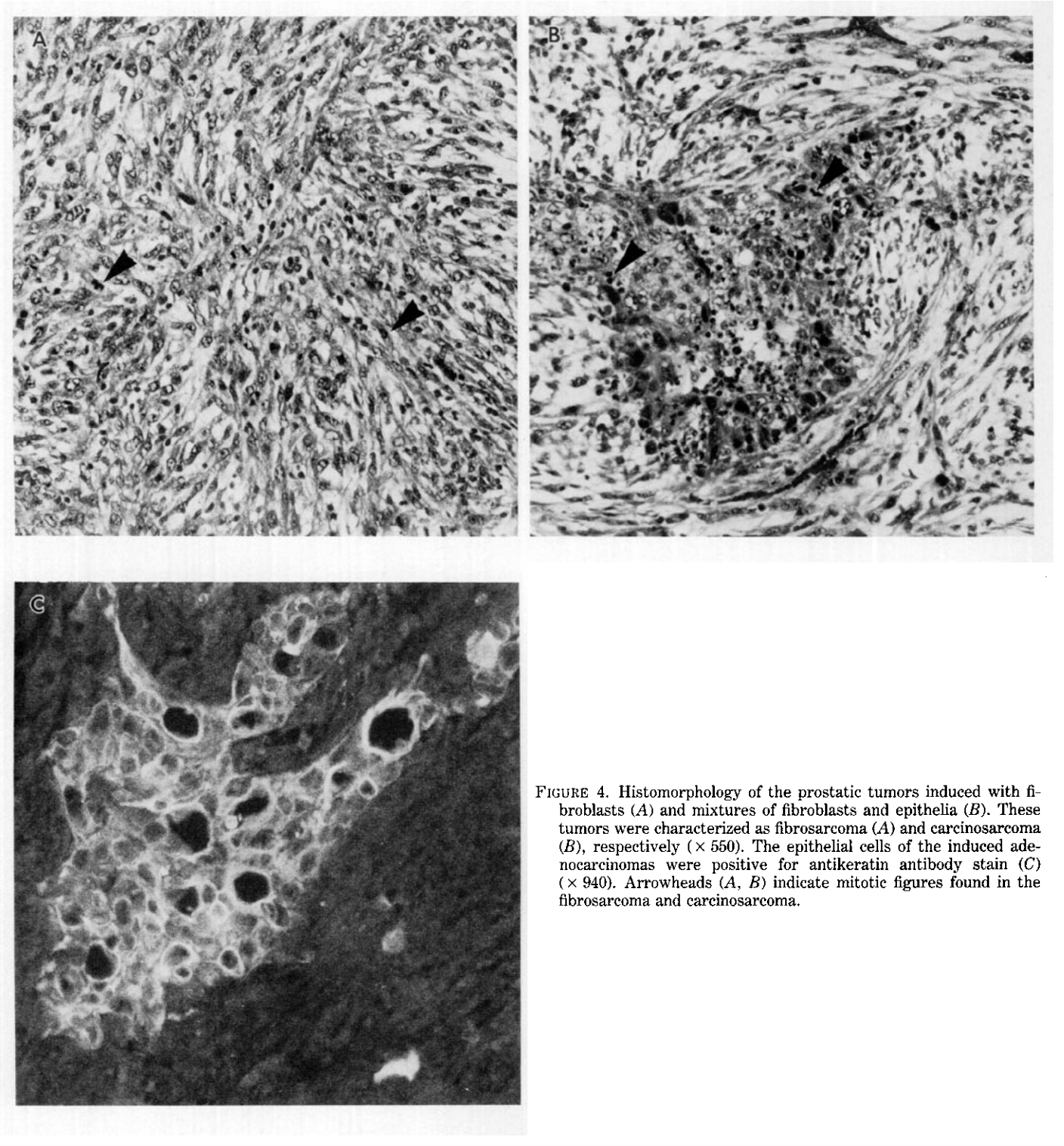

FIGURE 4. Histomorphology of the prostatic tumors induced with fibroblasts (*A*) and mixtures of fibroblasts and epithelia (*B*). These tumors were characterized as fibrosarcoma (*A*) and carcinosarcoma (*B*), respectively (× 550). The epithelial cells of the induced adenocarcinomas were positive for antikeratin antibody stain (*C*) (× 940). Arrowheads (*A*, *B*) indicate mitotic figures found in the fibrosarcoma and carcinosarcoma.

tumor. The precise volume of the epithelial component in the tumor is difficult to assess because of the extensive intermixing between fibroblasts and epithelia. Nests of epithelial colonies, which were demonstrated by antikeratin immunofluorescence, were found to be randomly scattered among the sarcomatoid component. Numerous mitotic activities (Fig. 4*B*) were detected in the epithelia of the induced glandular structures, suggesting that the underlying tumorigenic fibroblasts have induced epithelial proliferation and organization to form adenocarcinoma through cell-cell interaction. We have subsequently recovered epithelial cells from the carcinosarcoma through cell culture method and found that the epithelial component remained nontumorigenic when inoculated into adult male hosts (data not shown). These results emphasize the role of fibroblast in epi-

thelial tumorigenesis. The tumorigenic fibroblasts effectively promoted the nontumorigenic epithelia to undergo adenocarcinoma development.

Corroborating the *in vitro* DHT stimulation of cultured prostatic fibroblast growth, we found that both the fibrosarcoma induced by tumorigenic fibroblasts alone and the carcinosarcoma induced by the mixture of fibroblasts and epithelia were androgen responsive. Figure 5 shows that the fibrosarcoma grew somewhat faster in intact than in castrated adult male hosts and that castration greatly reduced the growth rate of the experimentally induced carcinosarcoma. No palpable growth of the transplantable prostatic tumors was detected in females during a 9-day observation period (data not shown).

General Comments and Conclusion

Results of this study demonstrate that both androgen responsiveness and tumorigenicity of the experimentally induced prostatic tumors are determined by the fibroblasts. Our data also suggest that androgen responsiveness alone is not sufficient to activate tumor development in the fibroblasts (e.g., after the 11th passage, fibroblasts are responsive to DHT-induced DNA synthesis but are completely nontumorigenic). The roles of fibroblasts in prostatic cancer development and androgen sensitivity are consistent with our previous finding that fetal urogenital sinus mesenchyme (fibroblast) is the target for DHT that determines the normal growth and development of fetal urogenital sinus epithelia *in vivo* in tissue recombinants (*13*).

As a result of this study, we can offer a new epigenetic mechanism for prostatic carcinogenesis. The tumorigenic fibroblasts were found to induce the nontumorigenic epithelia to form a tumor that contained a mixture of sarcoma and adenocarcinoma. Although the condition of carcinosarcoma in the prostate is a rare disease in man (*14*), the concept that a directive influence from the stromal component induces patterns of adenocarcinoma formation deserves greater attention. In this regard, it is interesting to note that the epithelial cells in culture, isolated from normal or neoplastic human prostate glands, exhibited no difference in their growth responses to various hormones and growth factors (*15*).

This novel mechanism of inducing prostatic tumor development via cell-cell interaction does not preclude the influence of genetic factor(s) that may predispose the epithelia to proliferate and to develop tumors in response to neighboring tumorigenic fibroblasts. Furthermore, it has not been determined if the changes introduced into the responding epithelium are genetically stable. However, electron microscopy provided no evidence for the presence of viral particles in the experimentally induced prostatic tumors. Finally, it is unlikely that the induced epithelial cancers were the result of cell fusion between tumorigenic fibroblast and nontumorigenic epithelium, because tumorigenicity, in general, was found to be a recessive trait (*16*). Work is currently in progress to determine DNA content profiles in cells through flow cytometry and karotyping of epithelial cells harvested before and after cellular interaction.

This study provides, for the first time, strong evidence that tumorigenic events can be activated across the cellular membranous barrier through cell-cell inter-

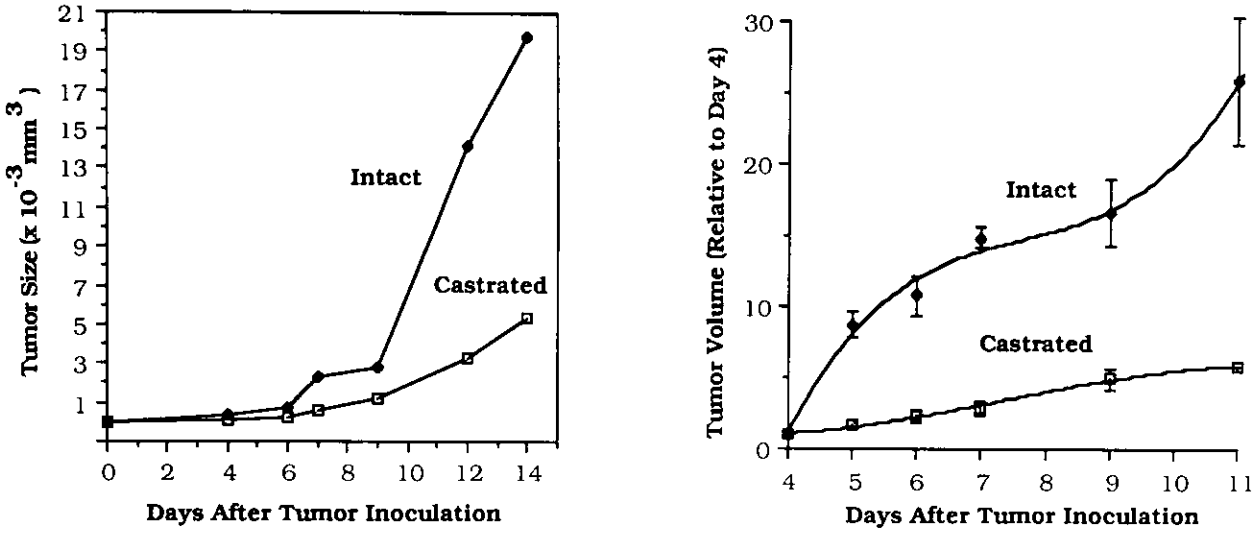

FIGURE 5. Androgen-responsiveness of the fibrosarcoma (left panel) and carcinosarcoma (right panel) in rats. Adult male rats were either sham-operated or castrated 1 week prior to inoculation with tumorigenic prostatic fibroblasts (6.7×10^6 cells). Tumor volumes were measured by a microcaliper and calculated according to a standard procedure (*24*). Data represent the average sizes of tumors from three specimens each. In another experiment, two rats were inoculated with a total of 2×10^6 cells (10% fibroblasts), and the tumors were allowed to grow for 4 days. At this time, one animal was castrated and the other was sham-operated. Individual tumor volumes were measured daily or every other day for an additional 7 days. Data were expressed as average ± SEM of four determinations. In some cases, the SEs were not shown because they were small and fell within the average bars. Tumor volumes are expressed relative to day 4, which is designated as 1.0.

action. It is possible that certain chemical signaling, in the form of soluble growth factors (*17*), angiogenesis factors (*18*), or an extracellular matrix (*19–21*), is involved in maintaining cell-cell communication and phenotypic expression. Certain protein growth factors have been isolated from both whole normal rat (*22*) and hyperplastic human prostate glands (*23*). The functional significance of these chemical signaling systems between epithelium and stroma and their role in normal and abnormal prostate growth and development remain obscure.

In this model system, we have observed that prostatic fibroblasts determine epithelial growth, androgen responsiveness, and tumorigenicity. The concept of the role of cell-cell interaction in prostatic carcinogenesis may, in the future, yield alternate therapeutic approaches to the regulation of cancer growth.

This study was supported in part by PHS-AM-25266 from the National Institutes of Health and the New Development Fund from the University of Texas M. D. Anderson Hospital and Tumor Institute. The helpful suggestions provided by Dr. P. Frost during the preparation of this manuscript and the secretarial assistance provided by S. Mendez are gratefully appreciated.

REFERENCES

1. Grobstein, C. Mechanism of organogenetic tissue interaction. Natl. Cancer Inst. Monograph 26: 279–299 (1967).
2. Hay, E. D., and Meier, S. Glycosaminoglycan synthesis by embryonic inductors: Neural tube, notochord, and lens. J. Cell Biol. 62: 889–898 (1974).
3. Smith, B. T., and Sabry, K. Glucocorticoid-thyroid synergism in lung maturation: A mechanism involving epithelial-mesenchymal interaction. Proc. Natl. Acad. Sci. (U.S.) 80: 1951–1954 (1983).
4. Dürnberger, H., and Kratochwil, K. Specificity of tissue interaction and origin of mesenchymal cells in the androgen response of the embryonic mammary gland. Cell 19: 465–471 (1980).
5. Cunha, G. R., Chung, L. W. K., Shannon, J. M., and Reese, B. A. Stromal-epithelial interactions in sex differentiation. Biol. Reprod. 22: 19–42 (1980).
6. Cunha, G. R., Chung, L. W. K., Shannon, J. M., Taguchi, O., and Fujii, H. Hormone-induced morphogenesis and growth: Role of mesenchymal-epithelial interactions. Recent Prog. Horm. Res. 39: 559–598 (1983).
7. Thompson, T. C., Cunha, G. R., Shannon, J. M., and Chung, L. W. K. Androgen-induced biochemical responses in epithelium lacking androgen receptors: Characterization of androgen receptors in the mesenchymal derivative of urogenital sinus. J. Steroid Biochem. 25: 627–634 (1986).
8. Kratochwil, K., and Schwartz, P. Tissue interaction in androgen response of embryonic mammary rudiment of mouse: Identification of target tissue for testosterone. Proc. Natl. Acad. Sci. (U.S.) 73: 4041–4044 (1976).
9. Phillips, M. A., and Rice, R. H. Convergent differentiation in culture rat cells from non-keratinized epithelia: Keratinocyte character and intrinsic differences. J. Cell Biol. 97: 686–691 (1983).
10. Chung, L. W. K., Anderson, N. G., Neubauer, B. L., Cunha, G. R., Thompson, T. C., and Rocco, A. K. Tissue interaction in prostate development: Role of sex steroids. In: The Prostate Cell: Structure and Function, Part A (G. P. Murphy, A. A. Sandberg, and J. P. Karr, Eds.), Alan R. Liss, New York, 1981, pp. 177–203.
11. Neubauer, B. L., Anderson, N. G., Cunha, G. R., Towell, J. F., and Chung, L. W. K. Androgen metabolism in tissue recombinants composed of adult urinary bladder epithelium and urogenital sinus mesenchyme. J. Steroid Biochem. 23: 95–101 (1985).
12. Roy, A. V., Brower, M. E., and Hayden, J. E. Sodium thymolphthalein monophosphate: A new acid phosphatase substrate with greater specificity for prostatic enzyme in serum. Clin. Chem. 17: 1093–1102 (1971).
13. Chung, L. W. K., and Cunha, G. R. Stromal-epithelial interactions. II. Regulation of prostatic growth by embryonic urogenital sinus mesenchyme. Prostate 4: 503–511 (1983).
14. Haddad, J. R., and Reyes, E. C. Carcinosarcoma of the prostate with metastasis of both elements—case report. J. Urol. 103: 80–83 (1970).
15. Peehl, D. M., and Stamey, T. A. Growth responses of normal, benign hyperplastic, and malignant human prostatic epithelial cells in vitro to cholera toxin, pituitary extract, and hydrocortisone. Prostate 8: 51–61 (1986).
16. Harris, H., Miller, O. J., Klein, G., Worst, P., and Tachibana, T. Supression of malignancy by cell fusion. Nature 223: 363–368 (1969).
17. Dickson, R. B., and Lippman, M. E. Estrogenic regulation of growth and polypeptide growth factor secretion in human breast carcinoma. Endocr. Rev. 8: 29–43 (1987).
18. Folkman, J., Haudenschild, C. C., and Zetter, B. R. Long-term culture of capillary endothelial cells. Proc. Natl. Acad. Sci. (U.S.) 76: 5217–5221 (1979).
19. Gospodarowicz, D., and Ill, C. Extracellular matrix and control of proliferation of vascular endothelial cells. J. Clin. Invest. 65: 1351–1354 (1980).
20. Banerjee, S. D., Cohn, R. H., and Bernfield, M. R. Basal lamina of embryonic salivary epithelia. J. Cell Biol. 73: 445–463 (1977).
21. Steinmann, B. V., and Reddi, A. H. Changes in synthesis of type-I and -III collagen during matrix-induced endochondral bone differentiation in rat. Biochem. J. 186: 919–924 (1980).
22. Maehama, S., Li, D., Nanri, H., Leykam, J. F., and Deuel, T. F. Purification and partial characterization of prostate-derived growth factor. Proc. Natl. Acad. Sci. (U.S.) 83: 8162–8166 (1986).
23. Story, M. T., Esch, F., Shimasaki, S., Sasse, J., Jacobs, S. C., and Lawson, R. K. Amino-terminal sequence of a large form of basic fibroblast growth factor isolated from human benign prostatic hyperplastic tissue. Biochem. Biophys. Res. Comm. 142: 702–709 (1987).
24. Humphries, J. E., and Isaacs, J. T. Unusual androgen sensitivity of the androgen-independent Dunning R.3327-G rat prostatic adenocarcinoma: Androgen effect on tumor cell loss. Cancer Res. 42: 3148–3156 (1982).