Vol. 85, pp. 231-238, 1990

Comparative Pathology of the Nasal Mucosa in Laboratory Animals Exposed to Inhaled Irritants

by Jack R. Harkema*

The nasal cavity is susceptible to chemically induced injury as a result of exposure to inhaled irritants. Some responses of the nasal mucosa to inhaled toxicants are species specific. These species-related differences in response may be due to variations in structural, physiologic, and biochemical factors, such as gross nasal cavity structure, distribution of luminal epithelial cell populations along the nasal airway, intranasal airflow patterns, nasal mucociliary apparatus, and nasal xenobiotic metabolism among animal species. This paper reviews the comparative anatomy and irritant-induced pathology of the nasal cavity in laboratory animals. The toxicologist, pathologist, and environmental risk assessor must have a good working knowledge of the similarities and differences in normal nasal structure and response to injury among species before they can select animal models for nasal toxicity studies, recognize toxicant-induced lesions in the nasal airway, and extrapolate experimental results to estimate the possible effects of an inhaled toxicant on the human nasal airway.

Introduction

As the portal of entry to the respiratory tract, the nasal cavity is a prime site for injury induced by inhaled toxicants. Although the nasal cavity functions to modify inspired air and protect the lower respiratory tract from high concentrations of potentially harmful toxicants, it has been shown, both in humans and in laboratory animals, that this organ is also susceptible to chemical-induced injury as a result of exposure to inhaled toxicants (*1-4*). In order to make reasonable predictions of the potential pathologic effects of inhaled irritants on the human upper airway, there must be an understanding of the differences and similarities in gross, microscopic, and ultrastructural anatomy among humans and laboratory animals. Before adequate extrapolations of observations from animal inhalation studies to human toxicity can be made, it must also be determined if there are significant species differences in the morphologic response of the nasal airway to the toxicant.

The purposes of the present article are to review some basic structural differences and similarities in the nasal airways among common laboratory animal species (primarily differences between the Fischer 344/N rat and the macaque monkey), and to emphasize some important morphologic similarities and differences between the nasal cavity of the human and that of the laboratory animal. Examples from the literature illustrating the acute and subchronic histopathologic responses of the nasal mucosa of various animal species to inhaled irritants will also be presented to demonstrate species similarities and differences in nasal response to injury.

Gross Anatomy

Major structural differences among animal species in the gross anatomy of the nasal cavity have been emphasized in previous reviews of comparative nasal anatomy (*5-9*). Species differences in the architecture of the nasal cavity probably result in variations in intranasal airflow patterns that may affect regional deposition of inhaled toxicants, and they partially determine the species-specific cell populations at risk. Nasal cavity volume has been determined using silicone rubber casts of the airways of rat (0.4 cm^3), beagle dog (20 cm^3), and rhesus monkey (8 cm^3). The volume of the human nasal cavity was estimated to be 25 cm^3 by using computer tomograms of the nasal airways from human cadavers (*10*). Using data from airway cross-sectional measurements obtained from magnetic resonance images, the nasal cavity volume of one human subject was 16 cm^3 (R. A. Guilmette, personal communication).

In addition to the obvious size differences of the nasal cavity among species, there are also striking variations in the complexity of turbinate structures projecting into the nasal lumen. This results in tremendous differences

*Inhalation Toxicology Research Institute, Lovelace Biomedical and Environmental Research Institute, P. O. Box 5890, Albuquerque, NM 87185.

in the luminal surface area and in the surface area-to-volume ratio. The total surface area of a 16-week-old F344 rat has been reported to be approximately 1340 mm^2 (*11*), while that of the rhesus monkey is approximately 6200 mm^2 (*12*). The human nasal cavity surface area has been determined to be approximately 18,100 mm^2 (*12*). The calculated surface area-to-volume ratio of the macaque monkey (775 mm^2/cm^3) is much slower to that of the human (820 mm^2/cm^3), than it is to that of the rat (3350 mm^2/cm^3). The architectural differences in the nasal passage of humans, macaque monkeys, and rats are illustrated in Figure 1.

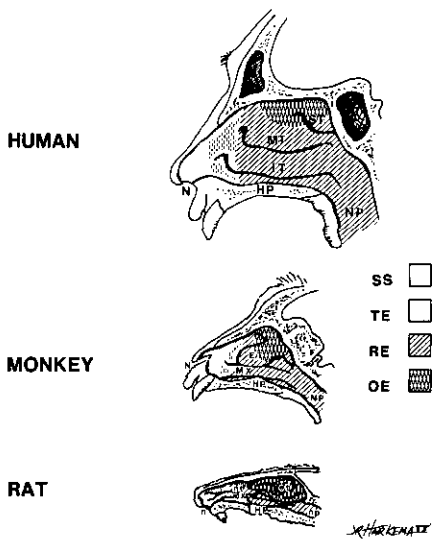

FIGURE 1. Diagrammatic representation of the exposed mucosal surface of the nasal lateral wall and turbinate of the rat, bonnet monkey, and human. Distribution of the four epithelial populations is also shown. SS, squamous epithelium; TE, transitional (nonciliated, cuboidal) epithelium; RE, respiratory epithelium; OE, olfactory epithelium; N, nares; HP, hard palate; NP, nasopharynx; ST, superior turbinate; MT, middle turbinate; IT, inferior turbinate; ET, ethmoid turbinate; NT, nasal turbinate; MX, maxilloturbinate.

Differences in overall nasal lumen size and shape presumably contribute, in various degrees, to species differences in nasal airflow patterns (*7,13,14*), regional intranasal deposition of inhaled particles, and the dose of the toxicant to various epithelial cell populations along the luminal surface. Physiologic factors, such as respiratory rate, minute volume, and the amount of oral breathing are also critical in estimating the dose to various nasal epithelial cell populations.

Nasal Epithelial Populations

Species differences are found not only in the gross architecture of the nasal cavity, but also in the epithelial populations lining the cavity. There are differences among animal species in the distribution of the nasal epithelial populations and the types of cells within these defined populations. Although there are differences, there are also similarities in nasal mucosa. The most important species similarity that must be recognized by the experimental morphologist is that all commonly used laboratory animals have four specifically defined epithelial regions. These regions include: stratified squamous epithelium (SE) in the nasal vestibule; ciliated, pseudostratified respiratory epithelium (RE) in the main cavity of the nasal airway; a narrow region of nonciliated, cuboidal, transitional epithelium (TE) lying between the SE and RE in the proximal or anterior aspect of the main chamber; and olfactory epithelium (OE), located in the dorsal or dorsoposterior aspect of the nasal cavity. Major differences in the regional distribution of these populations and relatively minor variations in the types of cells exist among animal species. A diagrammatic representation of the distribution of these four epithelia in humans, bonnet monkeys (*Macaca radiata*), and Fischer 344/N rats is shown in Figure 1, which also illustrates the differences in relative proportions of the different epithelia between primates and rats. Olfactory epithelium, for example, covers a greater percentage of the rat nasal cavity than of the nasal cavities of monkeys or humans. Approximately 50% of the nasal cavity surface area in 16-week-old F344 rats is lined by OE, 46.5% by RE, and 3.5% by SE (*11*). Similar morphometric determinations have not been made for primates, but the proportion of the surface area covered by OE is considerably less (*9*). In the monkey the relative areas of RE and OE are greater than in humans because of the marked extension of the ethmoid turbinate into the airspace (*15,16*).

Another morphologic difference in nasal epithelial distribution between primates and rats is the restriction of TE in rats to the anterior lateral wall of the nasal cavity. In monkeys and humans, TE is present on both the lateral and septal walls of the anterior nasal cavity (*16–18*). Since it has been shown in previous inhalation studies that TE may be particularly sensitive to irritant exposure (*1,2*), it is important to recognize the location of this epithelium in laboratory animals and to critically examine this tissue for microscopic lesions when animals are exposed to inhaled irritants.

In addition to differences in distribution of specific epithelia in the nasal cavity, there are some differences in the cellular composition and/or structural makeup of the various nasal epithelia. Although the morphologic composition of the SE and OE does not differ significantly among laboratory animal species (most of the differences are in distribution rather than cellular content in these epithelia), there are important histologic differences in TE and RE between some laboratory species. TE in the macaque monkey has been characterized as a stratified (4–5 cells in thickness), nonciliated, cuboidal/columnar, epithelium with luminal cells covered by microvillli (Plate 1A). Five epithelial cell types, including goblet cells, luminal nonciliated cells with few secretory granules, luminal nonciliated cells without secretory granules, small mucous granule cells, and basal cells, are

found in TE of the macaque monkey (*16*). Although the TE of rodents is also nonciliated, it is pseudostratified (1–2 cells in thickness) and normally composed of basal cells and cuboidal cells with no or few secretory granules (*19*). Plate 2 illustrates this epithelium on the ventral margin of the rat nasal turbinate.

Luminal nonciliated cells without secretory granules make up a relatively large proportion of the TE in monkeys. These cells appear ultrastructurally similar to nonciliated epithelial cells described in the rat (*20,21*) and mouse (*22*). Luminal nonciliated cells in rodents, however, have abundant apical accumulations of agranula endoplasmic reticulum (aER), a feature not evident in similar cells in macaque monkeys. Relatively high amounts of cytochrome P-450-dependent monooxygenase (usually associated with aER) have been reported in the rat, rabbit, and dog nasal mucosa, covering the anterior nasal cavity (*23,24*). The anterior aspect of the dorsal concha of the dog nasal cavity, a region covered by TE, has recently been shown to have higher metabolizing activity for certain xenobiotic substrates than other regions of canine nasal mucosa (*25*). It has also been demonstrated that similar nonciliated cuboidal cells lining the maxilloturbinates in the anterior nasal cavity of the rabbit contain certain cytochrome P-450 isozymes not evident in adjacent RE (C. G. Plopper, personal communication). It seems likely that these TE cells in rabbits, dogs, rats, and other rodents may play significant roles in the metabolism of certain inhaled xenobiotics. In contrast, the absence of aER accumulation in the nonciliated cells of the TE in monkeys suggests that this epithelium is not a major site of xenobiotic metabolism in this species.

The small mucous granule cell (SMG) is a prominent cell type in the TE of bonnet monkeys and is located in the midepithelial layers between the apical and basal cells. No such cell type has been described in the nasal TE of rodents.

RE in all laboratory animal species is ciliated, pseudostratified, and contains secretory cells with mucosubstances. There are, however, some subtle differences in cellular components of this nasal epithelium among species. In the rat, the RE is composed of six morphologically distinct cell types: goblet cells, ciliated cells, brush cells, nonciliated columnar cells, cuboidal cells, and basal cells (*20*). Macaque nasal RE contains ciliated, goblet, and basal cells like the rat, but it also contains SMG cells and cells with intracytoplasmic lumina (*16*). These latter epithelial cells contain within their cytoplasm unusual lumina lined by an uninterrupted membrane where cilia and microvilli project into the center of the lumen. It has been demonstrated morphometrically that these unique epithelial cells proliferate in response to long-term exposure to ozone (*2*). Similar cells have not been described in the nasal RE of normal rats but have been reported in rats exposed to formaldehyde (*26*).

Four basic cell types (olfactory sensory cells, sustentacular cells, cells lining Bowman's duct, and basal cells) comprise the OE of laboratory animals and man. Although the OE in laboratory animals and humans are similar in histologic appearance, there are significant differences in the amount of xenobiotic-metabolizing activity among species (*27*). For example, concentrations of certain cytochrome P-450 isozymes in the olfactory mucosa of monkeys have been reported to be approximately twice those in the olfactory mucosa of rats (*28*). Such differences may be important in interpreting how a species metabolically handles a certain inhaled xenobiotic compared to another species.

It is not clear what impact species diversity in nasal airway epithelial cells has, but it strongly suggests the potential for wide variation in nasal function and response to toxicant-induced injury. The following sections summarize some of the known responses of nasal epithelium to inhaled irritants.

Acute Responses of Nasal Transitional Epithelium to Inhaled Irritants

SE and TE epithelia of the nasal cavity are assumed to be exposed to near ambient concentrations of atmospheric pollutants and may be particularly vulnerable to inhaled irritants because of their proximal location in the nasal airway. SE is more resistant to histologic alteration than TE but can be eroded by extremely caustic toxicants (*29*). TE can also be eroded by caustic substances but commonly exhibits hyperplastic and/or metaplastic changes in response to subchronic exposure to less irritating toxicants. These changes are usually preceded and sometimes accompanied by acute inflammation with an influx of neutrophils into the lamina propria, luminal epithelium, and airway lumen.

Ozone is a common oxidant air pollutant that has been experimentally demonstrated to induce epithelial hyperplasia and secretory cell hyperplasia in the TE of both monkeys (*2*) (Plate 2*B*) and rats (*19,30,31*) (Plate 2*B*). After 6 or 90 days of exposure to 0.15 or 0.30 ppm ozone, bonnet monkeys had nasal TE changes that included increases in luminal cells with secretory granules, nonciliated-luminal cell degeneration and necrosis, intraepithelial inflammatory cell influx (6 days), SMG cell hyperplasia, and dilated granular endoplasmic reticulum (90 days). The latter feature (granular endoplasmic reticulum with grossly dilated cisterna) is similar in histologic appearance to what has been referred to as intraepithelial, eosinophilic, or hyaline globules in the TE and RE of rats and mice exposed to gaseous irritants and less frequently in untreated controls (*29*). The hyperplastic and metaplastic responses induced by ozone were present in TE in both the septum and lateral wall.

Ozone induces a similar response in the TE of rats after 7 days (6 hr/day) of exposure to 0.8 ppm (*19,30*). As in the monkeys, the TE of ozone-exposed rats had increased numbers of cells and increased amounts of intraepithelial mucosubstances after 7 days of exposure. Using bromodeoxyuridine combined with immunohisto-

chemistry, it has been demonstrated that after 3 days of exposure to 0.8 ppm ozone (6 hr/day), there is a marked increase (124 times that in air controls) in the number of epithelial cells in the S-phase of the cell cycle, but without concomitant epithelial hyperplasia. Johnson et al. have recently demonstrated, using bromodeoxyuridine, that RE and OE also have increases in the number of cells in S-phase after the same exposure to ozone, but the increases are only 2 to 4% of the increase in TE (*31*). In addition, there was no progression of the ozone-induced response to hyperplasia at 7 days in the RE and OE as there was in the TE of these rodents.

Cigarette smoke is another irritant that can alter the TE in rodents. Unlike ozone, which predominantly induces a secretory cell hyperplasia, cigarette smoke exposure results in squamous metaplasia along with epithelial cell proliferation (*32,33*). Others have shown that irritants differ considerably in their ability to induce squamous metaplasia in laboratory rodents (*29*). Formaldehyde is one irritant that has been demonstrated to induce squamous metaplasia in the nasal cavities of both rodents and nonhuman primates (*34–36*).

It is important to remember that laboratory rodents exposed to highly water-soluble, gaseous irritants most often have lesions on the distal tips and lateral margins of the naso- and maxilloturbinates and on the adjacent lateral wall in the anterior aspect of the nasal cavity, which are covered by TE (*29*). Ozone exposure (0.8 ppm, 6 hr/day for 7 days), for example, induced hyperplastic lesions in TE of rats on the lateral wall and turbinates, but the RE along the adjacent septum had no lesions (*19*). Although only a few nasal irritant studies using nonhuman primates have been reported (*1,2,36*), results from these experiments indicate that irritant lesions are also common in the anterior aspects of the nasal cavity covered by TE, but are usually distributed on both the septal and lateral walls.

Acute Responses of Nasal Respiratory Epithelium to Inhaled Irritants

As in TE, lesions in RE may be superficial or extend to the underlying lamina propria. A common superficial, and often reversible, effect of irritants on RE involves attenuation and/or loss of cilia along the luminal surface in the anterior nasal cavity (Plate 3). This effect was frequently seen in mice and rats exposed to chlorine gas (*37*) and was a common alteration observed in monkeys exposed to 0.15 and 0.30 ppm ozone for 6 or 90 days (8 hr/day) (*2*). Ciliated cell necrosis, secretory cell hyperplasia, inflammatory cell influx (after 6 days of exposure only), goblet cells with dilated, granular endoplasmic reticulum (after 90 days of exposure only), SMG cell hyperplasia, and increased numbers of epithelial cells with intracytoplasmic lumina were additional features of RE in monkeys exposed to ozone (*2*).

In contrast, rats exposed to approximately twice the concentrations of ozone as the nonhuman primates had no evidence of cilia loss in the anterior nasal cavity, but they did have deciliation along the walls of the more distal nasopharynx (*19*). The reasons for these species differences are unknown, but they may be partially explained by differences in nasal airflow patterns, differing amounts of protective mucus overlying the nasal mucosa, and/or varying sensitivities of RE cells to ozone. More elaborate studies must be specifically designed to investigate the mechanisms responsible for these differences in species responses within the RE.

Recent studies have demonstrated that the RE in both rodents and monkeys is susceptible to subchronic exposures to formaldehyde, which result in loss of goblet cells and cilia, epithelial proliferation with or without squamous metaplasia, and an associated inflammatory response (*34,36*). These nonneoplastic lesions in the anterior nasal cavity of rats occurred in the same regions in which formaldehyde-induced nasal tumors were identified after chronic exposures to this irritant (*34,38*).

There is usually a distinct anterioposterior gradient in the severity of lesions induced by inhaled water-soluble irritants in laboratory animals. Although this is generally true for intranasal regions, lesions of different character can be found in the distal airways of the respiratory tract, including the terminal airways within the lung. Harkema et al. (*38*) have demonstrated that ozone-induced lesions of nearly equal severity were evident in both the anterior nasal cavity and the terminal and respiratory bronchioles of bonnet monkeys. Interestingly, Monticello et al. (*36*) have recently demonstrated that the same formaldehyde exposure regime (6 ppm for 5 days/week for 1 or 6 weeks), which induced lesions only in the anterior nasal cavity in rats, caused lesions in the nasal cavity, larynx, trachea and carina of monkeys. Based on these results, they suggested that the monkey is more sensitive than the rat to the acute and subacute effects of formaldehyde.

Acute Responses of Olfactory Epithelium to Inhaled Irritants

A more thorough and in-depth review of common irritant-induced alterations in OE is presented by Gaskell in another article within this publication, and the reader is referred to that report (*39*).

OE can be injured not only by direct-acting gaseous irritants such as chlorine (*37*), but also by indirect-acting inhalants such as ferrocene (N. Gillett, personal communication), 3-methylfuran (*40*), and dimethylnitrosamine (*41*). High concentrations of cytochrome P-450-dependent monooxygenases occur in OE. Ferrocene, 3-methylfuran, and dimethylnitrosamine are all metabolized to toxic metabolites by these enzymes, and it is these metabolites that account for the tissue specificity of the toxic effects. Although the other nasal epithelia may also be injured by xenobiotics activated by the cytochrome-P-450 pathway, the OE usually tends to be the most sensitive epithelium to these toxicants.

It is important for the pathologist to understand that even though the OE may not differ significantly in histo-

logic appearance among animal species, there are marked differences in the amount of xenobiotic metabolizing activity between species. The OE of rats, for example, contains only about one-half the concentration of cytochrome P-450 of that in the OE of monkeys (*28*). Therefore, OE in monkeys and other primates may exhibit more severe lesions in response to certain inhaled xenobiotics than does rodent OE. To this author's knowledge, no study has been reported that is designed specifically to compare toxicant-induced olfactory lesions in monkeys and rodents.

Summary

This comparative overview of morphologic responses of the nasal mucosa to irritant injury emphasizes the complexity and diversity found in different species of laboratory animals. Many of the differences in the responses are the result of species variations in gross architecture and epithelial distributions along this upper airway. More subtle cellular differences within the various nasal epithelial populations also contribute to differences in susceptibility to injury.

Although there are major anatomical differences among laboratory animals, the toxicologist, pathologist, and risk assessor must also recognize the species differences in breathing patterns (i.e., obligate nose breathers versus nose and mouth breathers), mucociliary clearance, and airflow patterns. These differences were not addressed in this paper but undoubtedly contribute to species differences in response.

A main point of this review is that there must be a careful selection of animal models for toxicologic studies of the nasal airway and the selection must be based on a thorough working knowledge of species-specific morphologic characteristics. In addition, care must be exercised when interpreting animal data and extrapolating these results to estimate the possible effects of an inhaled toxicant on the human nasal airway.

Research was partially supported by the United States Department of Energy, Office of Health and Environmental Research, under Contract DE-AC04-76EV01013, and by National Institute of Health grant ES04282.

The author especially thanks J. Hotchkiss and other colleagues F. Hahn, J. Mauderly, R. Henderson, A. Dahl, J. Bond, N. Johnson, R. Jones, and T. Coons at the Lovelace Inhalation Toxicology Research Institute for critically reviewing this manuscript and supplying helpful comments.

The author also gratefully acknowledges the excellent technical assistance of L. Herrera, P. Lawson, R. Jaramillo, and the word processing skills of N. Gilchrist.

REFERENCES

1. Harkema, J. R., Plopper, C. G., Hyde, D. M., St. George, J. A., and Dungworth, D. L. Effects of an ambient level of ozone on primate nasal epithelial mucosubstances: quantitative histochemistry. Am. J. Pathol. 127: 90–96 (1987).
2. Harkema, J. R., Plopper, C. G., Hyde, D. M., St. George, J. A., Wilson, D. W., and Dungworth, D. L. Response of the macaque nasal epithelium to ambient levels of ozone: a morphologic and morphometric study of the transitional and respiratory epithelium. Am. J. Pathol. 128: 29–44 (1987).
3. Buckley, L. A., Jiang, X. Z., James, R. A., Morgan, K. T., and Barrow, C. S. Respiratory tract lesions induced by sensory irritants at the RD_{50} concentration. Toxicol. Appl. Pharmacol. 74: 417–429 (1984).
4. Walker, D. Histopathology of the nasal cavity in laboratory animals exposed to cigarette smoke and other irritants. In: Nasal Tumors in Animals and Man, Vol. III (G. Reznik and S. F. Stinson, Eds.), CRC Press, Boca Raton, FL, 1983, pp. 115–135.
5. Patra, A. L. Comparative anatomy of mammalian respiratory tracts: the nasopharyngeal region and the tracheobronchial region. J. Toxicol. Environ. Health 17: 163–174 (1986).
6. Patra, A. L., Gooya, A., and Menache, M. G. A morphometric comparison of the nasopharyngeal airway of laboratory animals and humans. Anat. Rec. 215: 42–50 (1986).
7. Proctor, D. E., and Chang, J. C. F. Comparative anatomy and physiology of the nasal cavity. In: Nasal Tumors in Animals and Man, Vol. III (G. Reznik and S. F. Stinson, Eds.), CRC Press, Boca Raton, FL. 1983, pp. 1–33.
8. Schreider, J. P., and Raabe, O. G. Anatomy of the nasal-pharyngeal airway of experimental animals. Anat. Rec. 200: 195–205 (1981).
9. Negus, V. E. The Comparative Anatomy and Physiology of the Nose and Paranasal Sinus. Livingstone, Edinburgh, Scotland, 1958.
10. Montgomery, W., Vig, P., Stabb, E., and Matteson, S. Computed tomography: a three-dimensional study of the nasal airway. Am. J. Orthod. 76: 363–375 (1979).
11. Gross, E. A., Swenberg, J. A., Field, S., and Popp, J. A. Comparative morphometry of the nasal cavity in rats and mice. J. Anat. 135: 83–88 (1982).
12. Schreider, J. P. Comparative anatomy and function of the nasal passages. In: Toxicology of the Nasal Passages (C. S. Barrow, Ed.), Hemisphere Publishing Corp., New York, 1986, pp. 1–25.
13. Morgan, K. T., Monticello, T. M., Fleishman, A., and Patra, A. L. Preparation of rat airway casts and their application to studies of nasal airflow. In: Proceedings of a Symposium on Lung Dosimetry, Extrapolation Modeling of Inhaled Particles and Gases. Duke University, Durham, NC, in press.
14. Swift, D. L., and Proctor, D. F. Access of air to the respiratory tract. In: Respiratory Defense Mechanisms (J. D. Brain, D. F. Proctor, and L. M. Reid, Eds.), Marcel Dekker, New York, 1977, pp. 63–93.
15. Lucas, A. M. The nasal cavity and direction of fluid by ciliary movement in macacus rhesus. Am. J. Anat. 50: 131–177 (1932).
16. Harkema, J. R., Plopper, C. G., Hyde, D. M., Willson, D. W. St. George, J. A., and Wong, V. J. Nonolfactory surface epithelium of the nasal cavity of the bonnet monkey : a morphologic and morphometric study of the transitional and respiratory epithelium. Am. J. Anat. 180: 266–279 (1987).
17. Mygrind, N., Pedersen, M., and Nielsen, M. H. Morphology of the upper airway epithelium. In: The Nose: Upper Airway Physiology and the Atmospheric Environment (D. F. Proctor and I. Andersen, Eds.), Elsevier Biomedical Press, Amsterdam, 1982, pp. 71–97.
18. Lenz, H. Three-dimensional surface representation of the cilia-free nasal mucosa of man. Acta. Otolaryngol. 76: 47–57 (1973).
19. Harkema, J. R., Hotchkiss, J. R., and Henderson, R. F. Effects of 0.12 and 0.80 ppm ozone on rat nasal and nasopharyngeal epithelial mucosubstances. Toxicol. Pathol. 17: 525–535 (1989).
20. Monteiro-Riviere, N., and Popp, J. A. Ultrastructural characterization of the nasal respiratory epithelium in the rat. Am. J. Anat. 169: 31–43 (1984).
21. Popp, J. A., and Martin, J. T. Surface topography and distribution of cell types in the rat nasal respiratory epithelium: scanning electron microscopic observations. Am. J. Anat. 169: 31–43 (1984).
22. Matulionis, D. H., and Parks, H. R. Ultrastructural morphology of normal nasal respiratory epithelium of the mouse. Anat. Res. 176: 65–84 (1972).
23. Dahl, A. R. The effect of cytochrome P-450-dependent metabolism and other enzyme activities on olfaction. In: Molecular Neurobiology of the Olfactory System (F. L. Margolis

and T. V. Getchell, Eds.), Plenum Publishing Corporation, New York, 1988, pp. 51–70.
24. Dahl, A. R., Hadley, W. M., Hahn, F. F., Benson, J. M., and McClellan, R. O. Association of cytochrome P-450-dependent monoxygenases with olfactory epithelium of dogs: possible role of tumorigenicity of inhaled materials. Science 216: 57–59 (1982).
25. Bond, J. A., Harkema, J. R., and Russel, V. I. Regional distribution of xenobiotic metabolizing enzymes in the respiratory airways of dogs. Drug Metab. Dispos. 16: 116–124 (1988).
26. Monteiro-Riviere, N. A., and Popp, J. A. Ultrastructural elevation of acute toxicity in the rat respiratory epithelium in response to formaldehyde gas. Fundam. Appl. Toxicol. 6: 251–252 (1986).
27. Hadley, W. M., and Dahl, A. R. Cytochrome P-450-dependent monoxygenases in nasal membranes of six species. Drug Metab. Dispos. 11: 275–276 (1983).
28. Dahl, A. R. Possible consequences of cytochrome P-450-dependent monooxygenases in nasal tissues. In: Toxicology of the Nasal Passages (C. S. Barrow, Ed.), Hemisphere Publishing Corporation, New York, 1986, pp. 263–273.
29. Jiang, X. Z., Morgan, K. T., and Beauchamp, R. O., Jr. Histopathology of acute and subacute nasal toxicity. In: Toxicology of the Nasal Passages (C. S. Barrow, Ed.), Hemisphere Publishing Corporation, New York, 1986, pp. 51–66.
30. Hotchkiss, J. A., Harkema, J. R., Johnson, N. F., and Henderson, R. F. Ozone-induced nasal epithelial proliferation and secretory cell hyperplasia in rats. Submitted.
31. Johnson, N. F., Hotchkiss, J. A., Harkema, J. R., and Henderson, R. F. Regional differences in cell proliferation in rat nasal epithelium following ozone exposure. Submitted.
32. Johnson, N. F., Hotchkiss, J. A., Harkema, J. R., Henderson, R. F., and Mauderly, J. L. Cell proliferation in nasal epithelium following cigarette smoke and ozone exposure (abstract). Toxicologist 9: 36 (1989).
33. Basrur, P. K., and Harada, T. Alterations in the nasal mucosa of Syrian golden hamsters exposed to cigarette smoke. Prog. Exp. Tumor Res. 24: 283–301 (1979).
34. Chang, J. C. F., Gross, E. A., Swenberg, J. A., and Barrow, C. S. Nasal cavity deposition, histopathology and cell proliferation after single or repeated formaldehyde exposure in B6C3F1 mice and F344 rats. Toxicol. Appl. Pharmacol. 68: 161–176 (1983).
35. Swenberg, J. A., Gross, E. A., and Randall, H. W. Localization and quantitation of cell proliferation following exposure to nasal irritants. In: Toxicology of the Nasal Passages (C. S. Barrow, Ed.), Hemisphere Publishing Corporation, New York, 1986, pp. 291–298.
36. Monticello, T. M., Morgan, K. T., Everitt, J. I., and Popp, J. A. Effects of formaldehyde gas on the respiratory tract of rhesus monkeys: pathology and cell proliferation. Am. J. Pathol. 134: 515–527 (1989).
37. Jiang, X. Z., Burkley, L. A., and Morgan, K. T. Pathology of toxic responses to the RD_{50} concentration of chlorine gas in the nasal passages of rats and mice. Toxicol. Appl. Pharmacol. 71: 225–236 (1983).
38. Harkema, J. R., Plopper, C. G., St. George, J. A., Tyles, N. K., and Dungworth, D. L. Comparison of nasal and centriacinar epithelial changes induced by low ambient levels of ozone (abstract). Am. Rev. Respir. Dis. 131(2): A169 (1985).
39. Gaskell, B. A. Nonneoplastic changes in the olfactory epithelium experimental studies. Environ. Health Perspect. 85: 275–289 (1990).
40. Haschek, W. M., Morse, C. C., Boyd, M. R., Hakkinen, P. J., and Witschi, H. P. Pathology of acute inhalation exposure to 3-methylfuran in the rat and hamster. Exp. Mol. Pathol. 39: 342–354 (1983).
41. Druckrey, H. R., Preussman, R., Ivankovic, S., Schmähl, D., Afkham, J., Blum, G., Mennel, H. D., Müller, M., Petropoulos, P., and Schneider, H. Organotrope Carcinogene Wirkungen bei 65 Verschiedenen N-Nitrosoverbindungen and BD-ratten. Zeitschrift für Krebsforschung 69: 103–201 (1967).

PLATE 1. Light photomicrographs of transitional (*A*,*B*) and anterior respiratory epithelium (*A*,*C*) and 0.15 ppm ozone (*B*, *D*) for 6 days. Intraepithelial influx of neutrophils (arrow) is present in short-term ozone-exposed tissues. L, lumen of nasal airway; G, glands within lamina propria; BV, blood vessels; d, duct from subepithelial gland. All tissue sections stained with toluidine blue. Used by permission from Harkema et al. (*2*).

PLATE 2. (*A*) Transitional epithelium covering lateral, medial, and ventral margins of nasal turbinate from a rat. (*B*) Hyperplastic transitional epithelium covering nasal turbinate from a rat after 7 days of exposure (6 hr/day) to 0.80 ppm zone. L, lumen of nasal airway; D, surface epithelium; B, base of turbinates; BV, blood vessel. Tissues are stained with toluidine blue. Used by permission from Harkema et al. (*19*).

PLATE 3. Scanning electron micrographs of luminal surfaces of anterior respiratory epithelium from the nasal septum of monkeys exposed to 0.00 ppm ozone (*A*) and 0.15 ppm ozone for 6 days (*B*), 0.15 ppm for 90 days (*C*), and 0.30 ppm ozone for 90 days (*D*). Surfaces exposed to 0.15 ppm or 0.30 ppm ozone had loss of cilia (arrowheads) and nonciliated cells with domed luminal surfaces (arrows). Used by permission from Harkema et al. (*2*).