Environmental Health Perspectives
Vol. 92, pp. 71–74, 1991

Chromium-Induced Kidney Disease

by Richard P. Wedeen* and Lifen Qian†

Kidney disease is often cited as one of the adverse effects of chromium, yet chronic renal disease due to occupational or environmental exposure to chromium has not been reported. Occasional cases of acute tubular necrosis (ATN) following massive absorption of chromate have been described. Chromate-induced ATN has been extensively studied in experimental animals following parenteral administration of large doses of potassium chromate (hexavalent) (15 mg/kg body weight). The chromate is selectively accumulated in the convoluted proximal tubule where necrosis occurs. An adverse long-term effect of low-dose chromium exposure on the kidneys is suggested by reports of low molecular weight (LMW) proteinuria in chromium workers. Excessive urinary excretion of β_2-microglobulin, a specific proximal tubule brush border protein, and retinol-binding protein has been reported among chrome platers and welders. However, LMW proteinuria occurs after a variety of physiologic stresses, is usually reversible, and cannot by itself be considered evidence of chronic renal disease. Chromate-induced ATN and LMW proteinuria in chromium workers, nevertheless, raise the possibility that low-level, long-term exposure may produce persistent renal injury. The absence of evidence of chromate-induced chronic renal disease cannot be interpreted as evidence of the absence of such injury. Rather, it must be recognized that no prospective cohort or case-control study of the delayed renal effects of low-level, long-term exposure to chromium has been published.

Introduction

Recognition of the massive deposits of chromium used in landfill in Hudson County, New Jersey, has drawn attention to the potential health hazards of this heavy metal. Kidney disease is often cited as an adverse effect of chromium, yet chronic renal disease due to occupational or environmental exposure to this metal has not been reported (*1*). The absence of evidence of chromate-induced chronic renal disease, however, cannot be interpreted to mean that such injury does not occur. Rather, it must be recognized that no prospective cohort or case-control study of the delayed renal effects of low-level, long-term exposure to chromium has been published. As early as 1916, the New Jersey Department of Labor warned that the bichromate in commercial pigments not only produced ulcers of the skin and nasal septum, but "It also acts upon the digestive tract by swallowing the dust, upon the pharynx by inhalation, and upon the kidneys by blood absorption" (*2*). In 1924, the New Jersey legislature included chromium poisoning among the 10 occupational diseases compensable under the State's workmen's (now workers') compensation law. Despite recognition of acute renal failure from chromium over 100 years ago (*3*), no reliable information is yet available on the long-term effects of chromium on the kidney.

Acute Tubular Necrosis

In contrast to the paucity of evidence on chromium-induced chronic renal disease, massive exposure to hexavalent chromium consistently causes acute tubular necrosis (ATN), clinically evident as a marked reduction in urine flow rate, if the patient survives for more than a few hours. ATN is characterized by the rapid onset of renal failure. Following heavy acute absorption, symptomatology is initially dominated by overwhelming pulmonary or gastrointestinal toxicity, depending on the route of exposure. In the syndrome of ATN, early oliguria (urine output less than 200 mL/day in adults) is followed by a polyuric phase (urine output exceeding 3 L/day), and subsequent gradual recovery of renal function over a few weeks. Prior to spontaneous tubular regeneration and restoration of renal function, hemodialysis may prove life-saving by temporarily sustaining the patient. ATN caused by massive absorption of chromic acid and successful treatment by dialysis has been reported (*3–6*). Acute renal failure from accidental exposure to either trivalent or hexavalent chromium in the workplace is, however, distinctly rare.

*VA Medical Center, East Orange, NJ 07019.
†University of Medicine and Dentistry of New Jersey, the New Jersey Medical School, Newark, NJ 07103.
Address reprint requests to R. P. Wedeen, VA Medical Center, East Orange, NJ 07019.

Potassium chromate, 15 mg/kg body weight given parenterally, reproducibly induces ATN in animals (*7,8*). This experimental model of acute renal failure has permitted a detailed analysis of the pathophysiology of nephrotoxic ATN in the rat, using sophisticated micropuncture, microperfusion, and microdissection techniques (Fig. 1). Potassium dichromate produces necrosis in the convoluted portion of the proximal tubule, in contrast to mercuric chloride, which causes necrosis in the more distal straight segments of proximal tubules. Cellular necrosis is preceded by impairment of intracellular enzyme activity and enzymuria (*9,10*). Restoration of renal function may be incomplete, leaving residual, chronic interstitial nephritis in this experimental model (*8*). However, no such cases of incomplete recovery have been reported in humans leaving persisting chronic interstitial nephritis.

Metabolism

Studies using radioactive ^{51}Cr placed intratracheally in animals indicate chromium is selectively accumulated in the renal cortex at a 6- to 20-fold higher concentration than in red blood cells or liver (*11*). *In vitro* studies using rat renal cortical slices support these inferences (*12*). Both trivalent and hexavalent chromium are accumulated up to 80-fold above the incubation medium concentration in the slice preparation by a process that appears to represent active (energy requiring) biologic transport (*12*). Renal cortical accumulation of chromate demonstrated by low resolution autoradiography appears to represent uptake in the convoluted portion of proximal tubules, the site of cellular necrosis (*11*). Although it is generally agreed that the trivalent form of chromium is less nephrotoxic than the hexavalent form, tubular necrosis and acute renal failure have been reported from both species of the metal (*5,6,13,14*). In contrast to the trivalent form, hexavalent chromium is water soluble and readily penetrates cell membranes. Absorption is less than 1% from the intestinal tract for both oxidation states (*15*). While the hexavalent form facilitates entry into the circulation and cell, cellular injury is believed to be initiated by intracellular protein binding of the trivalent form.

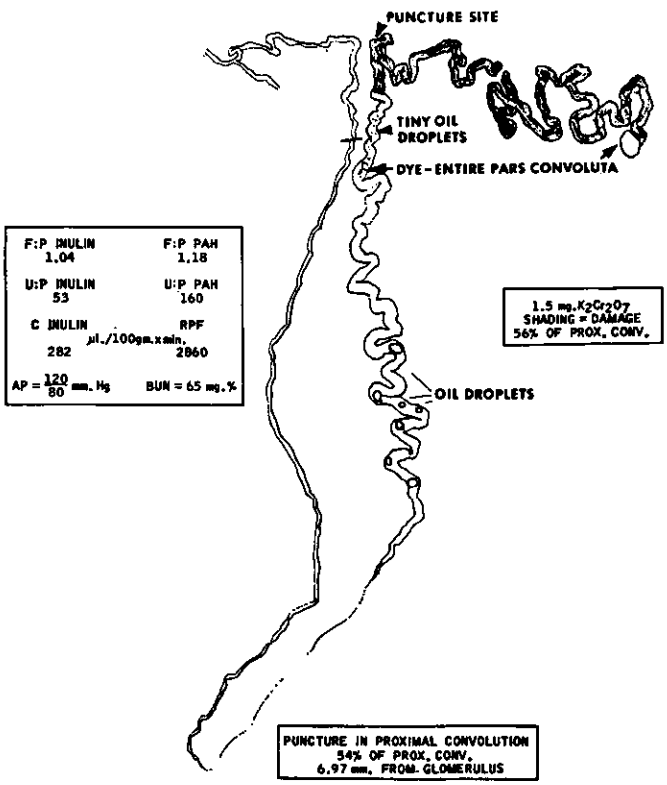

FIGURE 1. Functional changes and site of tubular necrosis induced by potassium chromate in rat. From Biber et al. (*7*) with permission.

Tubular Proteinuria

Suggestive evidence that chronic low-dose exposure to chromium has adverse effects on the kidneys arises from the finding of low molecular weight (LMW) proteinuria in chromium workers. Excessive urinary excretion of β_2-microglobulin, a specific proximal tubule brush border protein (BB-50) and an extra-renal enzyme, retinol-binding protein, have been reported among some chrome platers and welders (Tables 1 and 2), but not in others (*16–18*). The reasons for these contradictory findings are not clear but may relate to the absence of a reliable measure of cumulative past absorption and un-

Table 1. Renal function parameters (*17*).[a]

Group	Geometric mean ± SD/g creatinine		
	BB-50, units	Albumin, mg	RBP, μg
Chromate workers	5.25 ± 2.34	2.69 ± 1.81	84.2 ± 2.2
Controls I	2.63 ± 1.43*	2.29 ± 1.86	39.8 ± 2.1*
Cisplatin-treated patients	104.00 ± 5.62	10.70 ± 8.50	174.0 ± 3.2
Controls II	2.57 ± 2.18‡	4.20 ± 2.11	51.2 ± 1.6†

[a]BB-50, brush border protein; RBP, retinol-binding protein. Student's *t* test for independent samples for difference between controls I and chromate wokers or controls II and cisplatin-treated patients.
*$p < 0.05$.
†$p < 0.01$.
‡$p < 0.001$.

Table 2. Correlation coefficients between urinary excretion of BB-50 and albumin or BB-50 and RBP (*17*).[a]

Group	BB-50 and albumin	BB-50 and RBP
Chromate workers	0.04	0.44*
Cisplatin-treated patients	0.43*	0.61†
Controls I	0.39*	0.02
Controls II	0.06	0.07

[a]BB-50, brush border protein; RBP, retinol-binding protein.
*$p < 0.05$.
†$p < 0.01$.

certainty about the oxidation state of chromium because of its instability in biological materials.

Urinary LMW proteins may originate from either the tubule cell (e.g., BB-50 or *N*-acetylglucosaminidase) or from outside the kidney (e.g., β_2-microglobulin or retinol-binding protein). Extra-renal LMW proteins are filtered at the glomerulus and taken up by endocytosis at the luminal surface of proximal tubule cells. The intracellular LMW proteins are then catabolized within lysosomes to constituent amino acids. Filtered LMW proteins, consequently, do not normally appear in the urine.

LMW proteinuria indicates tubular dysfunction and is often called "tubular proteinuria." Such tubular dysfunction is usually reversible and is not considered indicative of renal disease unless it predicts the appearance of renal failure manifested by a decrease in glomerular filtration rate. LMW proteinuria has been shown to predict the later development of renal failure in cadmium nephropathy (*19*). It has been suggested that tubular dysfunction may only occur when urinary chromium exceeds 15 μg/g creatinine (*17*). Although it is apparent that chromium filtered at the glomerulus is largely reabsorbed by the tubule, renal clearance calculations are uninterpretable because of the complex binding characteristics of the various chromium species to serum proteins and the dependence of chromium excretion on urine flow rates.

Tubular proteinuria, the excretion of a few milligrams of protein under 20 kDa molecular weight that are normally not found in the urine, must be distinguished from classical glomerular proteinuria. Glomerular proteinuria often exceeds several grams per day and consists of high molecular weight proteins such as albumin and globulin. Tubular proteinuria occurs after a wide variety of physiologic stresses, is usually reversible, and cannot by itself be considered evidence of chronic renal disease. Progression to renal failure has not been observed among chrome workers exhibiting tubular proteinuria (*17,18*). Although acute tubular necrosis induced by single large doses of chromium is preceded by tubular proteinuria, there is no evidence that tubular proteinuria resulting from repeated small doses results in permanent renal damage, i.e., chronic renal disease.

Chronic Renal Injury

Chromate-induced ATN and tubular proteinuria, nevertheless, suggest that low-level, long-term exposure to chromium might produce chronic renal injury. Repeated minor tubular insults would be expected to eventually result in chronic interstitial nephritis. In contrast to glomerular disease, which is readily detected by simple tests for urinary albumin, interstitial nephritis is difficult to detect before the renal disease has become advanced, that is before more than two-thirds of kidney function is lost. At this relatively late state, there is sufficient reduction in the glomerular filtration rate to be detected by standard laboratory tests: elevation of the serum urea nitrogen and creatinine concentration. Immunologically mediated glomerular disease has been described from low-dose mercuric chloride administration in genetically susceptible animals, but primary glomerular disease has not been reported as a consequence of exposure to chromium. Chromium has, however, been reported to modify the immune system in animal models (*1*).

Because of the long delay in appearance, the relatively low attack rate, the difficulty in detecting early interstitial nephritis, and the multifactorial nature of kidney disease, chronic renal disease caused by chromium is unlikely to be identified in the usual one-on-one physician-patient encounter. Rather, systematic, prospective epidemiologic studies must be undertaken in which exposed individuals are compared to controls of similar age, sex, race, and socioeconomic background. Such a study should have a sensitive measure of cumulative past exposure to chromium as well as measures of kidney function. Since chromium may accumulate in kidney tissue over many months (*20*), and the biological half-life approximates 1 month (*21–23*), it may be possible to develop a chelation test to assess cumulative absorption comparable to the EDTA lead-mobilization test that has proven so useful in identifying lead nephropathy (*19*). Minor decreases in glomerular filtration may have to be identified prospectively in relatively large groups of exposed individuals compared to matched controls. Moreover, the contribution of chromium to renal failure may only be evident when superimposed on other causes of renal injury such a lead nephropathy, hypertension, or diabetes mellitis or as a reduction in the renal reserve.

Summary

In summary, both trivalent and hexavalent chromium compounds are selectively accumulated in the proximal convoluted tubule where, in large dosage, they induce acute tubular necrosis following parenteral administration. Coupled with the finding of tubular proteinuria in chromium workers, there is reason to suspect that chromium contributes to the development of chronic renal failure. The absence of reports of chronic renal disease due to chromium may not indicate the absence of an adverse renal effect but merely the absence of adequate clinical and epidemiological investigation. Despite the advances in our understanding of the pathogenesis of renal disease over the past few decades, preventable etiologies of chronic renal disease are only rarely identified. The contribution of environmental toxins to the progressive reduction in renal function with aging and systemic disease remains unknown. Large-scale, prospective case-control epidemiologic studies may be required to demonstrate the presence or absence chromium-induced chronic renal disease. Such an effort may well be worthwhile because chromium-induced kidney disease is potentially preventable. In 1988, over 135,000 Americans had end-stage

renal disease requiring dialysis or transplantation to sustain life at a cost of over $4.5 billion per year. New Jersey has the highest prevalence of end-stage renal disease in the United States (99 per million) (*24*) as well as impressive industrial pollution (*25*). It may therefore be appropriate to begin efforts at identifying preventable renal disease in this setting.

REFERENCES

1. Agency for Toxic Substances and Disease Registry. Toxicological Profile for Chromium. ATSDR/TP-88/10, U. S. Department of Health and Human Services, Public Health Service, Atlanta, GA, July, 1989.
2. Department of Labor of the State of New Jersey. Document No. 15, 1916, pp 3–103. In: New Jersey Legislative Documents 14–23, 1917, p. 82, Trenton, NJ.
3. Major, R. H. Studies on a case of chromic acid nephritis. Johns Hopkins Hosp. Bull. 372: 56–61 (1922).
4. Fristedt, B., Lindquist, B., Schutz, A., and Ovrum P. Survival in a case of acute oral chromic acid poisoning with acute renal failure treated by hemodialysis. Acta Med. Scand. 177: 153–159 (1965).
5. Kelly, P., Day, J. P., O'Hara, M., Tye, C., Burton, C., and Harris, M. Cutaneous absorption of trivalent chromium: tissue levels and treatment by exchange transfusion. Br. J. Ind. Med. 29: 397–400 (1982).
6. Schiffl, H., Weidman, P., Weiss, M., and Massry, S. G. Dialysis treatment of acute chromium intoxication and comparative efficacy of peritoneal versus hemodialysis in chromium removal. Min. Elec. Metab. 7: 28–35 (1982).
7. Biber, T. U., Mylle, M. Bains, A. D., Gottschalk, C. W., Oliver, J. R., and MacDowell, M. A study by micropuncture and microdissection of acute renal damage in rats. Am. J. Med. 44: 664–705 (1968).
8. Kramp, R. A., MacDowell, M., Gottschalk, C. W., and Oliver, J. R. A study by microdissection and micropuncture of the structure and the function of the kidneys and the nephrons of rats with chronic renal damage. Kidney Int. 5: 147–176 (1974).
9. Baines, A. W. Cell renewal following dichromate induced renal tubular necrosis. Am. J. Pathol. 47: 851–876 (1965).
10. Kirschbaum, B. B., Sprinkel, P. M., and Oken, D. E. Proximal tubule and brush border alterations during the course of chromate nephropathy. Toxicol. Appl. Pharmacol. 58: 19–30 (1981).
11. Weber, H. Long-term study of the distribution of soluble chromate-51 in the rat after intratracheal administration. J. Toxicol. Environ. Health 11: 749–764 (1983).
12. Berndt, W. O. Renal chromium accumulation and its relationship to chromium-induced nephrotoxicity. J. Toxicol. Environ. Health 1: 449–459 (1976).
13. Laborda, R., Diaz-Mayens, J., and Nunez, A. Nephrotoxic and hepatotoxic effects of chromium compounds in rats. Bull. Environ. Contam. Toxicol. 36: 332–336 (1986).
14. Mathur, A. K., Chandra, S. V., and Tandon, S. K. Comparative toxicity of trivalent and hexavalent chromium to rabbits. Toxicology 8: 53–61 (1977).
15. Sayato, Y., Nakamuro, K., Matsui, S., and Ando, M. Metabolic fate of chromium compounds. I. Comparative behavior of chromium in rats administered with $Na_2{}^{51}CrO_4$ and $^{51}CrCl_3$. J. Pharmacobiodyn. 3: 17–23 (1980).
16. Lindberg, E. K., and Vesterberg, O. Urinary excretion of proteins in chrome-platers, electroplaters and referents. Scand. J. Work Environ. Health 9: 505–510 (1983).
17. Franchini, I., and Mutti, A. Selected toxicologic aspects of chromium (VI) compounds. Sci. Total Environ. 71: 379–387 (1988).
18. Vershoor, M. A., Bragt, P. C., Herber, R. F. M., Zeilhuis, R. L., and Zwennis, W. C. M. Renal function of chrome-plating workers and welders. Int. Arch. Occup. Environ. Health 60: 67–70 (1988).
19. Wedeen, R. P. Heavy metals and the kidney. In: Oxford Textbook of Clinical Nephrology (J. D. Cameron, A. M. Davison, J.-P. Grunfeld, and E. Ritz, Eds.), Oxford University Press, Oxford, in press.
20. Franchini, I., Mutti, A., Cavbatorta, A., Corradi, A., Cosi,k A. Olivetti, A., and Borghetti, A. Nephrotoxicity of chromium. Remarks on experimental and epidemiologic investigations. Contr. Nephrol. 10: 98–110 (1978).
21. Mutti, A., Lucertini, S., Valcalvi, P., Neri, T. M., Fornari, M. Alinoyi, R., and Franchini, I. Urinary excretion of brush-border antigen revealed by monoclonal antibody: early indicator of toxic nephropathy. Lancet ii: 914–916 (1985).
22. McAughey, J. J., Samuel, A. M., Baxter, P. J., and Smith, N. J. Biological monitoring of occupational exposure in the chromate pigment production industry. Sci. Total Environ. 71: 317–322 (1988).
23. Lindberg, E., and Vesterberg, O. Urinary excretion of chromium in chromeplaters after discontinued exposure. Am. J. Ind. Med. 16: 485–492 (1989).
24. Rosansky, S. J., Huntsburger, T. L., Jackson, K., and Eggers, P. Comparative incidence rates of en-stage renal disease treatment by states. Am. J. Nephrol. 10: 198–204 (1990).
25. Sheehan, H., and Wedeen. R. P., Eds. The Price We Pay: Sharing the Toxic Burden. Rutgers University Press, New Brunswick, NJ, in press.