Biological Responses of the Nonhuman Primate, Chicken, and Rat to Chlorinated Dibenzo-*p*-dioxin Ingestion*

by D.H. Norback † and J.R. Allen †

In 1958 Schmittle et al. (*1*) reported the development of hydropericardium and ascites in poultry following ingestion of feeds containing industrially contaminated fats. The toxic component was demonstrated to have the chlorinated dibenzo-*p*-dioxin (CDD) structure by Cantrell et al. in 1969 (*2*). Experimental animal studies in our laboratory have shown that CDD administration causes varying responses in different animal species. Gastric hyperplasia and ulceration, hydropericardium, ascites, reduced spermatogenesis, focal liver necrosis, decreased hematopoiesis, skin lesions, and eventual mortality have been demonstrated in nonhuman primates (*3*). Chickens succumbed very rapidly to the same dietary concentration with hydropericardium, hydrothorax, and ascites. They also developed liver necrosis, hypoplastic testes, and altered capillary permeability and decreased hematopoiesis (*4–6*). The rat was more resistant to the morbid effects of CDD but developed a hypertrophied liver composed of enlarged hepatocytes with a proliferated intracellular membrane system (*7*). The results of these investigations are reviewed and the variable responses and pathogenesis of lesions are discussed.

The material used in the investigations was crude industrial fat capable of producing hydropericardium, ascites, and death in the chicken. Gas–liquid chromatographic and nuclear magnetic resonance analysis of the materials demonstrated bi-, tri-, tetra-, penta-, hexa-, and heptachlorodibenzo-*p*-dioxin present in the material, with the tetrachlorinated compound comprising 64% (mass) of the total dioxins present. In addition, rats were given radioactive octachloro- or radioactive tetrachlorodibenzo-*p*-dioxin in separate experiments (*8, 9*).

Macaca mulatta monkeys were given a diet that contained varying quantities of the crude industrial fat. The percentage of fat that allowed survival of the nonhuman primate for 100 days produced 50% mortality in chickens within 15 days. The survival time of the monkeys was inversely related to the percentage of the CDD-containing fat given to the animals. Clinical and pathologic changes occurring at their demise were similar regardless of concentration of material in their diet. At death all had developed ascites, hydropericardium, and anasarca. Prior to their demise the monkeys developed a decrease in total serum protein

*This investigation was supported in part by U.S. Public Health Service grants ES–00472 and RR–00167 from the National Institutes of Health. Primate Center Publication No. 13–010.

†Department of Pathology, University of Wisconsin Medical School, and Regional Primate Research Center, University of Wisconsin, Madison, Wisconsin 53706.

from 7.5 to 5.4 g/100 ml and a decrease in the percentage albumin from 61% to 35%. There was a decrease in hematocrit from 41% found in the control animals to 16% in the experimental group, a decrease in the white blood count from 6.8×10^3 per mm^3 to 3.0×10^3 and a decrease in the red cell count from 6.5×10^6 per mm^3 to 2.5×10^6. The hemoglobin values were correspondingly reduced. Analysis of the sternal bone marrow showed a hypoplastic bone marrow with diminished myeloid and erythroid cells being replaced by fatty tissue. The lymphoid tissue of the spleen and lymph nodes was hypoplastic.

The skin changes of the monkeys included alopecia and subcutaneous edema which progressed from the eyelids to the remainder of the face, eventually involving the subcutaneous tissue of the trunk, extremities, and scrotum. Microscopically, there was edema of the dermal layer with disarray of the collagen fibers. Hair follicles, particularly of the face, contained numerous keratin cysts with hyperplasia of the epithelium (Fig. 1).

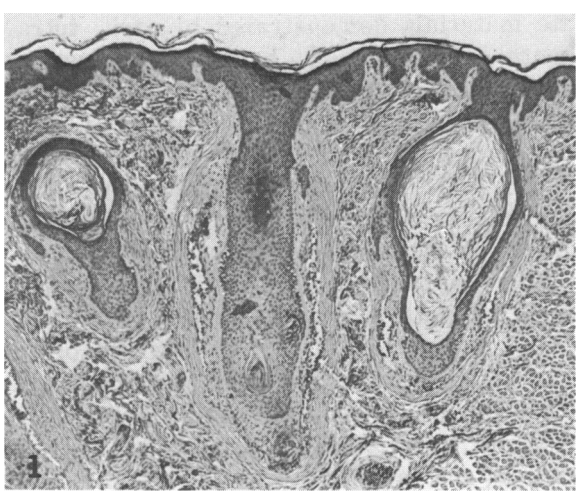

FIGURE 1. Hair follicles, particularly of the face and eyelids, of monkeys fed CDD contained numerous keratin cysts. Light micrograph of skin fixed with formalin and stained with hematoxylin and eosin. ×15.

The seminiferous tubules of the testes contained abundant spermatogonia and Sertoli cells. However, there was a decreased number of primary and secondary spermatocytes, and spermatids were inapparent in most instances (Fig. 2). The interstitial cells of Leydig appeared normal.

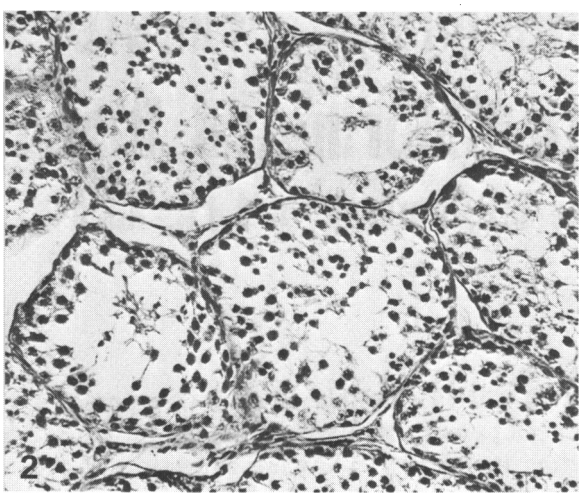

FIGURE 2. In a monkey fed CDD, seminiferous tubules of testes contained decreased numbers of primary and secondary spermatocytes without spermatids. Spermatogonia, Sertoli cells, and interstitial cells were normal in appearance. Light micrograph of testicular tissue fixed with formalin and stained with hematoxylin and eosin. ×115.

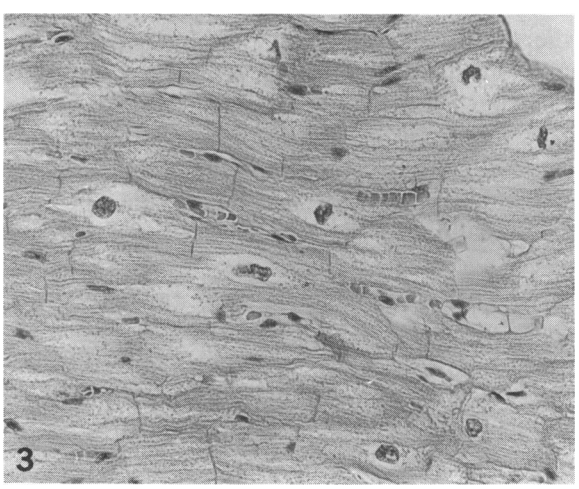

FIGURE 3. Cardiac fibers in the hearts of monkeys fed CDD were hypertrophied, and the myofilaments were widely separated by the increased intracellular fluid. Light micrograph of heart fixed with formalin and stained with hematoxylin and eosin. ×115.

The heart was dilated, particularly in the right chamber, and an increase in the circumference of both the tricuspid and mitral valves was noted. Microscopically, hypertrophic muscle fibers were separated by fluid (Fig. 3). Electron microscopic examination demonstrated separation of the myofibrils and swelling of the mitochondria with widely separated cristae (Fig. 4). In over 60% of the experimental monkeys, marked hypertrophy of the gastric mucosa occurred in the fundic and pyloric regions. The hypertrophied mucosal layer penetrated the muscularis mucosae to form crypts and mucin-containing cysts in the submucosa (Fig. 5). In the same areas, gastric ulcerations of the mucosal layer were present (Fig. 6).

The livers were moderately yellow. On microscopic examination, enlarged multinucleated hepatocytes and fat vacuoles were apparent. Terminally the animals developed centrilobular necrosis and bile duct hyperplasia. Changes in the biliary tree were observed as proliferation and stratification of the bile duct epithelial cells of the small ducts within the portal area and in the larger ducts, including the common bile duct running through the head of the pancreas (Fig. 7). Electron microscopic examination of the hepatocytes demonstrated hypertrophied cells with numerous autophagosomes and fat droplets, an increase in the smooth endoplasmic reticulum with a decrease in the rough endoplasmic reticulum, and swollen mitochondria (Fig. 8). In the morbid animals the parenchymal cells showed numerous degenerative changes. Many of the cells

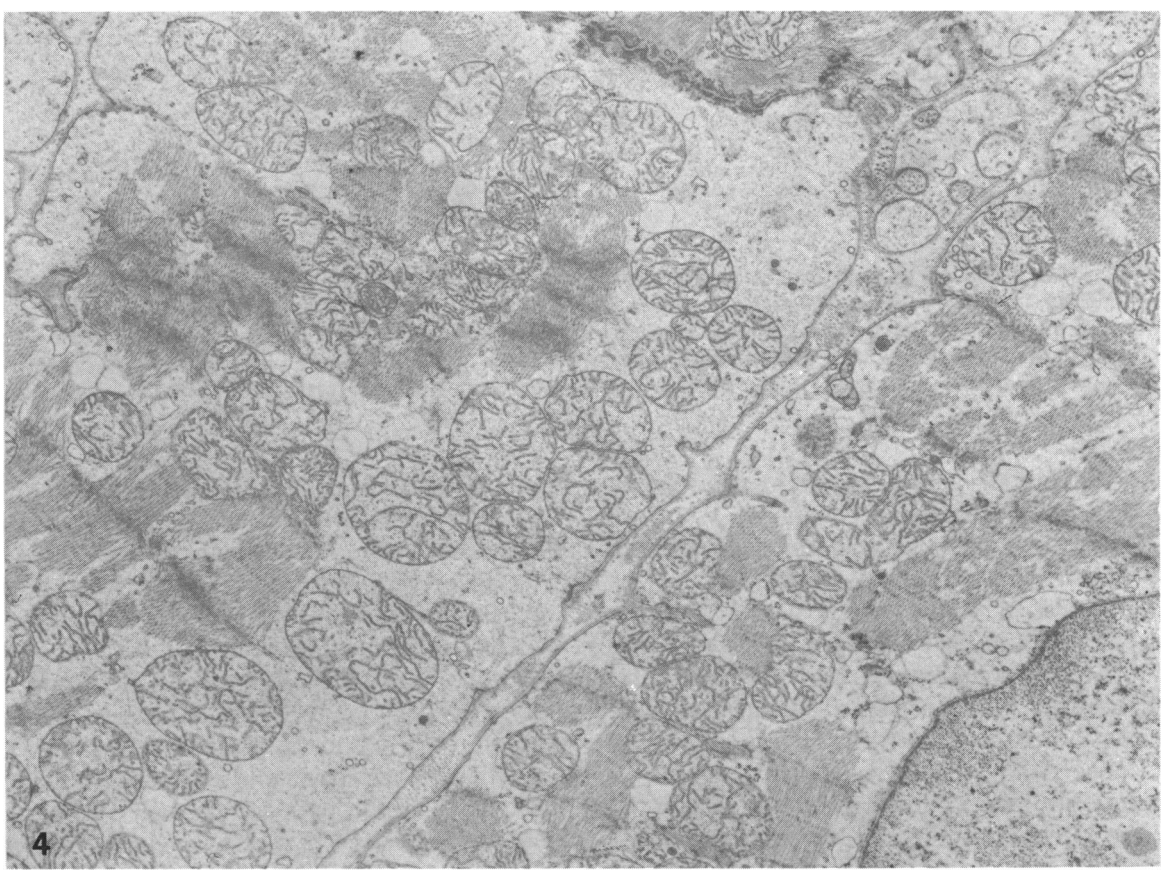

FIGURE 4. Myofibrils of dilated cardiac fibers within the heart of a monkey fed CDD were separated, and the mitochondria were moderately swollen. Electron micrograph of heart fixed with Veronal acetate-buffered osmium tetroxide solution and stained with uranyl acetate. ×9,700.

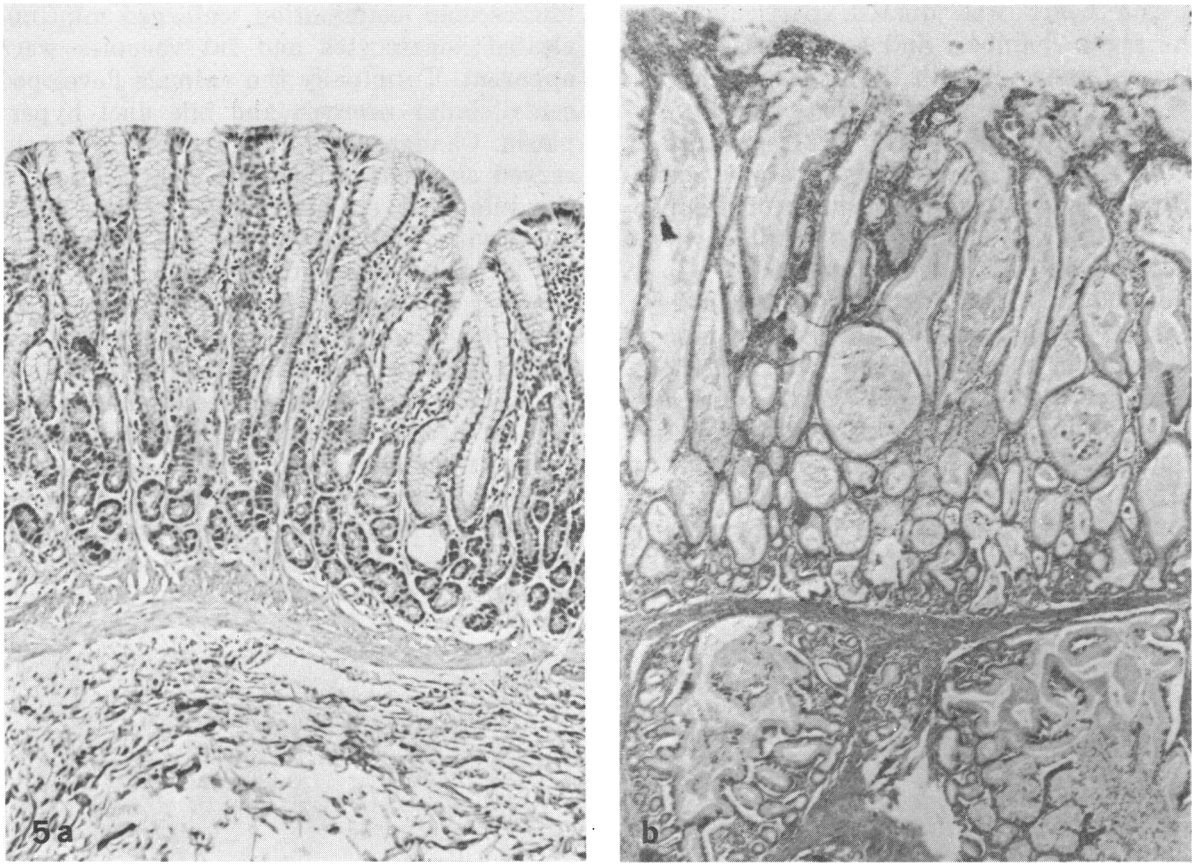

FIGURE 5. (*a*) Normal glands of the gastric mucosa are separated by the muscularis mucosae from the submucosa in this section of a stomach taken from a control monkey. (*b*) Following CDD ingestion, marked hypertrophy of the gastric mucosa occurred in the fundic and pyloric regions. Crypts and mucin-containing cysts within the submucosa are extensions of the hypertrophied mucosa which penetrated the muscularis mucosae. Light micrograph of stomach fixed with formalin and stained with hematoxylin and eosin. (*a*) ×30; (*b*) ×25.

were shrunken and electron-dense, while others were swollen and very lucent.

Of the experimental animals evaluated, the chicken was the most sensitive to the toxic effects of CDD. Low levels of the compounds resulted in a decrease in growth rate and the development of hydropericardium, hydrothorax, and ascites, resulting in death of the animals. Following doses sufficient to cause 50% mortality within 15 days, hemoglobin was reduced from 10 g/100 ml to 6 g/100 ml, hematocrit was reduced from 31% to 18%, and the total serum protein decreased from 3.4 g/100 ml to 2.3 g/100 ml. The percentage albumin also decreased in these animals. The animals developed large hearts, and on microscopic examination the cardiac fibers were separated by edematous fluid. A lymphocytic infiltrate was observed between the myocardial fibers and in the perivascular areas. The capsule of the liver was thickened with adherent fibrinous material. Lymphoid hyperplasia was apparent in the portal areas, and the hepatic cells were infiltrated with fat (Fig. 9). Electron microscopic examination demonstrated viable cells dispersed among degenerative cells. Degenerative changes of hepatocytes and Kupffer cells included electron dense cytoplasm, irregular mitochondria, and indistinct nuclear envelopes. The Sertoli cells and spermatogonia of the semi-

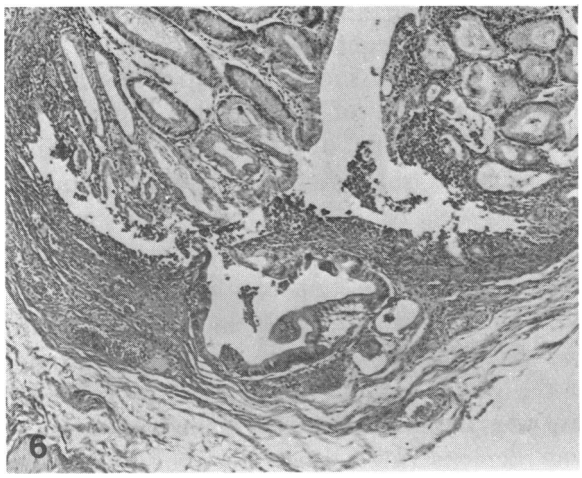

FIGURE 6. Gastric ulcerations of the hypertrophied mucosal layer were present in the stomachs of monkeys receiving CDD. Ulcers were particularly prevalent over areas of epithelial cell-lined submucosal cysts. Edema of the submucosa, portion of a submucosal cyst, fibrotic granulation tissue, a fibrinous exudate and overhanging edges of the mucosa are present. Light micrograph of stomach fixed with formalin and stained with hematoxylin and eosin. ×35.

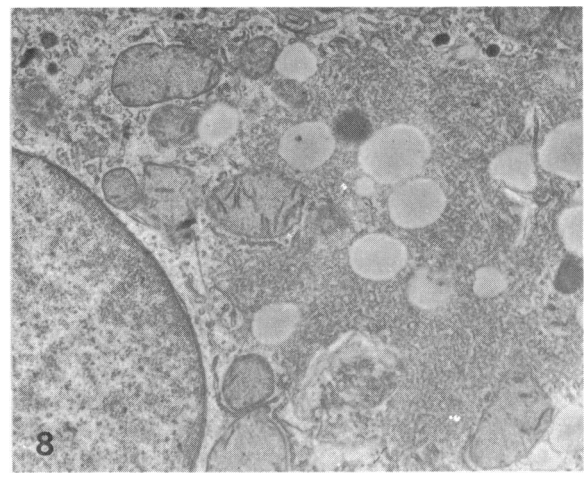

FIGURE 8. Livers of monkeys fed CDD contained hypertrophied cells with swollen mitochondria, increased numbers of lipid droplets, and a proliferation of smooth endoplasmic reticulum. Electron micrograph of liver tissue fixed in Veronal acetate-buffered osmium tetroxide solution and stained with uranyl acetate. ×8500.

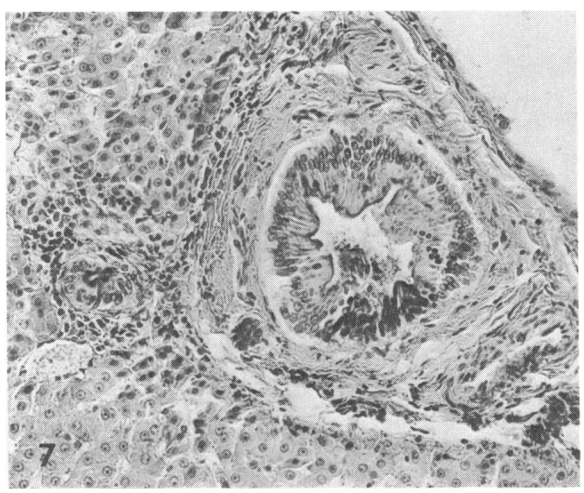

FIGURE 7. Following CDD ingestion by the monkeys, bile duct hyperplasia occurred within the liver. Tall columnar epithelial cells, many of which appeared stratified, replaced cuboidal cells found in the normal bile duct and epithelial folds extended into the lumen. Light micrographs of liver tissue fixed in formalin and stained with hematoxylin and eosin. ×115.

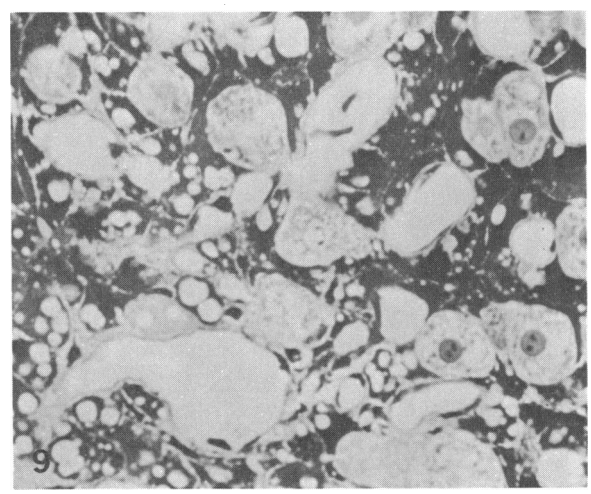

FIGURE 9. Light and dark staining cells were present in the livers of chickens fed CDD. Numerous fat droplets infiltrated the hepatocytes. Light micrograph of liver tissue fixed in Veronal acetate-buffered osmium tetroxide solution and stained with toluidine blue. ×610.

niferous tubules within the testes were normal; however, there was a reduction in the number of primary and secondary spermatocytes, and no spermatozoa were present. Gastrointestinal changes were not observed. The perfusion of the mesenteric vessels with ferritin, thorium dioxide, iron oxide, and carbon black demonstrated a decided alteration in capillary permeability of these experimental animals.

Following administration of approximately five times the concentration of the CDD-containing fat in the diet sufficient to cause hydropericardium, ascites, and focal necrosis of the liver in chickens and in nonhuman primates, the rat developed liver alterations with a 50% mortality at 80 days. At 6 weeks, enlarged livers contained hypertrophied hepatocytes with an increase in droplets and a higher quantity of extractable lipid. The histologic pattern of the livers consisting of sinusoids separated by single sheets of hepatocytes radiating from the portal areas to the central veins was maintained. Within the large hepatocytes a proliferation of the smooth endoplasmic reticulum and reorganization of the parallel cisternae of the rough endoplasmic reticulum to form large agranular concentric membrane arrays was demonstrated electron microscopically (Fig. 10).

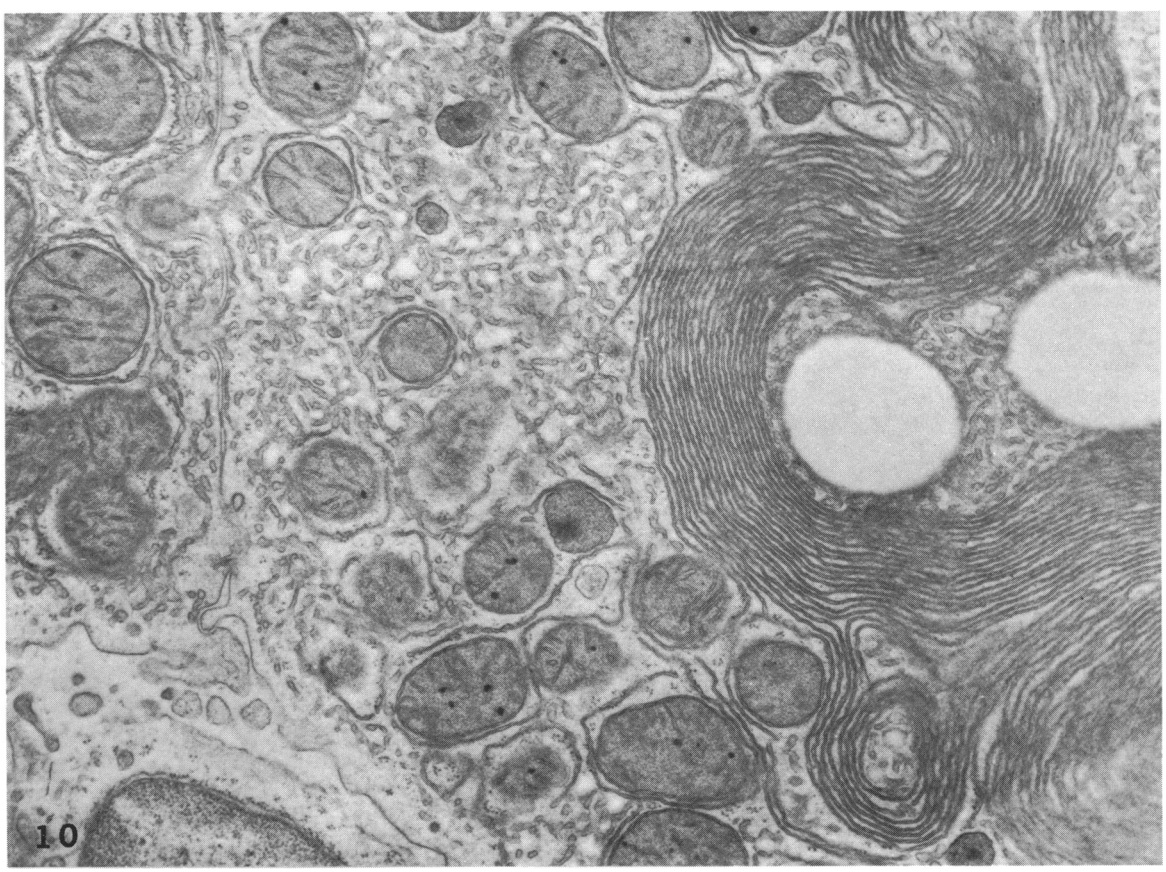

FIGURE 10. Hepatocytes of rats which ingested CDD developed a proliferated smooth endoplasmic reticulum consisting of numerous vesicles and concentric arrays of agranular membranes. The number of lipid droplets was increased. Electron micrograph of liver tissue fixed in Veronal acetate-buffered osmium tetroxide solution and stained with uranyl acetate. ×20,400.

Administration of tetrachlorodibenzo-*p*-dioxin (1 μg/day) resulted in a 50% mortality of the rats at 21 days. The morphologic appearance of the livers was similar to that produced by ingestion of the crude CDD-containing lipid material by rats. The smooth endoplasmic reticulum was proliferated, and large concentric membrane arrays were present.

Over a 21-day period of administration of labeled octachlorodibenzo-*p*-dioxin to rats (100 μg/rat/day, approximately 12.4 mg/kg administered over 21 days), 93% of the compound passed unabsorbed through the gastrointestinal tract. An additional 5% was excreted in a lipid-soluble form in the urine. The administration of the octachloro compound produced few morbid alterations in the rats. The animals continued to gain weight and maintained normal activities and gross appearance. Approximately 50% of the material present within the body tissues was located in the liver. Other reservoirs containing radioactivity at lesser levels were the adipose tissue, skeletal musculature, and skin. Over 95% of the CDD present within the liver was located in the microsomal fraction with equal distribution within the rough and smooth fractions.

Discussion

The data from these experimental animal studies have shown that CDD administration causes varying responses in the chicken, monkey, and rat. The chicken develops extreme morbidity and mortality at dietary concentrations that are only mildly toxic to rats while the monkey is intermediate in its response to the CDD.

The chicken and monkey developed ascites, hydrothorax, hydropericardium, and anasarca; however, the rat failed to develop increased extracellular fluid. These modifications in the fluid content of the tissues and body cavities were attributed in part to hepatic degenerative changes and altered capillary permeability of the chicken and monkey. The low serum albumin, a direct result of hepatic dysfunction, was associated with decreased osmolarity of the blood and subsequent extravasation of the fluid. In addition, the capillaries were demonstrated to be more permeable to colloidal particles before the decline in serum protein was sufficiently severe to produce an accumulation of fluid in the tissues.

Gastric hyperplasia and ulceration were limited to the nonhuman primate. Hyperplastic changes are thought to be related to the chronic irritation following ingestion of the compounds and other closely related chlorinated aromatic hydrocarbons (*10*). The dysplastic histologic and cytologic pattern as demonstrated by the invasion of the mucosal cells through the muscularis mucosae and the stratification of the epithelial cells within the cysts are changes suggestive of an eventual neoplastic transformation.

Monkeys developed widespread alopecia, moderate hyperkeratosis, follicular keratin cysts, and hyperplasia of the epithelium of the hair follicles, particularly of the face. However, the skin of rats or chickens was not altered appreciably.

Hypoplasia of the lymph tissue and bone marrow was present in all three animal species. However, the blood-forming tissues of the chicken and the monkey were affected earlier and more severely than were those of the rat. As a result of these changes in the lymph tissue and bone marrow, the animals became anemic and displayed a progressive leukopenia. Due to the reduced resistance of these animals they became prime hosts for opportune pathogens which in many instances were responsible for their death.

Hypoactivity of the seminiferous tubules of the testes was associated with chronic intoxication of the monkeys and chickens. Young chickens exposed to low levels of the dioxins experienced retardation in the development of the testes and at maturity were of normal size with hypoplastic gonads. There were no other alterations in growth, blood elements, or histologic appearance of the tissues.

Enlargement of the liver occurred in all animals used in these investigations. Increased size was related to the cell hyper-

trophy resulting from proliferation of the smooth endoplasmic reticulum and accumulation of lipid within the cytoplasm of the hepatocytes. The chicken rapidly developed widespread liver necrosis; similar degenerative changes occurred at a less rapid rate in the liver of the monkey, and the rat was very resistant to hepatic necrosis.

Radioactive studies which determined tissue and cell fraction levels of the CDD in the rat and possibly in other animal species demonstrated the proliferated hepatic endoplasmic reticulum present in animals following exposure to the CDD may serve not only as a source of enzymes to enhance the metabolism of foreign substances but may also function as an area of localization for these toxic compounds. The presence of a large portion of the ingested CDD within the microsomal fraction of the hepatic tissue may be one explanation as to why the rat is able to tolerate larger doses of the dioxins. The localization of the dioxins in these membranes may prevent their movement to other tissues of the body that are more susceptible to the toxic effects of these compounds. Although the specific reason for the difference in response of various animal species to the dioxins has not been established, further studies on absorption, metabolism, body distribution, excretion, or sensitivity of the tissues to the toxic effects of the dioxins are avenues of research that will likely clarify these questions.

REFERENCES

1. Schmittle, S. C., Edwards, H. M., and Morris, D. A disorder of chickens probably due to a toxic feed—preliminary report. J. Amer. Vet. Med. Assn. **132**; 216 (1958).
2. Cantrell, J. S., Webb, N. C., and Mabis, A. J. The identification and crystal structure of a hydropericardium producing factor: 1,2,3,7,8,9-hexachlorodibenzo-*p*-dioxin. Acta Cryst. **B25**: 150 (1969).
3. Allen, J. R., and Carstens, L. A. Light and electron microscopic observations in *Macaca mulatta* monkeys fed toxic fat. Amer. J. Vet. Res. **28**; 1513 (1967).
4. Allen, J. R. The role of toxic fat in the production of hydropericardium and ascites in chickens. Amer. J. Vet. Res. **25**; 1210 (1964).
5. Allen, J. R., and Carstens, L. A. Electron microscopic alterations in the liver of chickens fed toxic fat. Lab. Invest. **15**; 970 (1966).
6. Allen, J. R., and Lalich, J. J. The effects of "toxic fat" on spermatogenesis. Proc. Soc. Exp. Biol. Med. **109**; 48 (1962).
7. Norback, D. H., and Allen, J. R. Morphogenesis of the toxic fat-induced concentric membrane arrays in rat hepatocytes. Lab. Invest. **20**; 338 (1969).
8. Norback, D. H. Morphological and biochemical responses of the rat hepatic endoplasmic reticulum to polychlorinated triphenyls and to chlorinated bibenzo-*p*-dioxins. Ph.D. dissertation, University of Wisconsin, Madison, Wisc., August 1973; Dissertation Abstr., in press.
9. Norback, D. H., and Engblom, J. F. Chlorinated dibenzo-*p*-dioxin distribution within rat tissue and subfractions of the liver. Fed. Proc. **32**; 236 (1973).
10. Allen, J. R., and Norback, D. H. Polychlorinated biphenyl- and triphenyl-induced gastric mucosal hyperplasia in primates. Science **179**; 498 (1973).