Environmental Health Perspectives
Vol. 21, pp. 195–210, 1977

Pathologic Changes Following Chronic Exposures to Halothane: A Review

by Louis W. Chang*

The toxic effects of halothane on the liver, kidney, and brain are reviewed. Increasing evidence has indicated that hepatic degeneration can be induced in several animal species after exposure to halothane. Recent electron microscopic investigations have also revealed cytological degeneration of the liver cells after chronic exposure to subclinical levels of halothane. Degeneration of the kidney and the nervous system after halothane exposure have also been reported. The pathological effects of halothane on the neonatal (developing) liver, kidney, and brain are also demonstrated by electron microscopy. Although the full significance of these observations on experimental animals in relationship to human exposure is still not known, the indication of the toxic potential of halothane on the biological system is strong and deserves further investigation.

Since its introduction in 1956 for clinical use (*1*), halothane or fluothane (1,1,1-trifluoro-2,2-chlorobromoethane) has gained considerable popularity as an anesthetic agent because it gives the anesthetist for the first time a controllable, potent, nonexplosive, and nonflammable agent which can be used with oxygen and nitrous oxide. Despite its popularity, isolated cases of hepatitis following exposure to halothane have been reported in medical literature (*2–5*), suggesting the possible role of halothane in the induction of hepatic injury. The controversy over the existence of halothane hepatitis has been reviewed by various investigators (*6–8*), and halothane hepatitis has been generally accepted as a medical entity (*7*). Recent studies have demonstrated that hepatic lesions similar to those in human cases could be induced in rats (*9–11*) and in guinea pigs (*12*) after single or repeated exposure to halothane, further confirming the hepatotoxicity of halothane.

Besides the biohazard of halothane towards the patients, a nationwide epidemiologic survey by a panel of scientists indicates that chronic exposure to trace amounts of anesthetics in the ambient air of the operating room may also constitute a potentially hazardous condition for the operating room personnel (*13*). It was also indicated that such an exposure may be related to increased frequency of cancer, liver disease, spontaneous abortion, and congential abnormalities among OR personnel (*13–18*).

Only recently have reports appeared documenting the concentration of anesthetic agents in the vicinity of the anesthetist in the operating room (*19–22*). Linde and Bruce reported peak concentrations of 50 ppm halothane around the anesthesiologist (*19*), while Askrog and Peterson indicated that up to 85 ppm halothane was detected near the anesthesiologist when a nonrebreathing system was used (*23*). In modern, well ventilated operating rooms, 5–15 ppm halothane could still be detected in the ambient air of the operating room (*21–25*). Increased concern was generated in the effects of chronic exposure to low levels of anesthetics, in particular, halothane (*13, 18, 19, 21, 25–35*).

Numerous investigations have been performed in the attempt of providing pathological or morphological evidences of halothane toxicity. These informations and reports are published at various times and in different scientific journals. The purpose of the present review paper is to provide a general overview and summary on the representative pathological findings in the liver, kidney, and brain, as a result of exposure to halothane. Specific information on each investigation should be consulted with the original articles.

*Department of Pathology, University of Arkansas for Medical Sciences, Little Rock, Arkansas 72201 and National Center for Toxicological Research, Jefferson, Arkansas 72709.

Pathological Effects on the Liver

Because of the controversy concerning the ability of halothane in the induction of hepatic necrosis, a pathology panel was formed by the National Institute of Health and National Institute of General Medical Sciences to investigate the pathological findings of halothane hepatitis. A report of their findings was published later (*36*). It was found that the hepatic necrosis in most cases has no consistent pattern, varying from minor focal lesions with either random or regular zonal distribution to total parenchyma destruction. In some cases, however, the necrosis tended to orient about the centrilobular vein. Qizilbash has recently reviewed five cases of hepatocellular injury following halothane anesthesia (*37*). Four of the patients had received multiple exposures to the anesthetic, and three of them died from massive hepatic necrosis (*37*).

Ultrastructural studies on hepatitis induced by short-term and acute exposures to halothane have been performed in both human cases and in animal models (*38–45*). The general pathological changes consisted of swelling and necrosis of the liver cells, especially in central zones, with inflammatory infiltrate. The liver cells appeared dark and shrunken in some areas, swollen and pale in others. Active parenchymal hepatitis with foci of hepatocellular necrosis and cytoplasmic reticulum and bil canaliculi, mitochondrial changes, and myelin-figure formation were found in some cases indicating definitive cytological changes in the hepatocytes.

In a recent study, Stevens et al. compared the toxicities of halothane, isoflurane, and diethyl ether at subanesthetic concentrations in mice, rats, and guinea pigs (*46*). It was found that after 35 days exposure, halothane produced a greater decrement in weight gain and a greater incidence of hepatic degenerative changes than isoflurane of diethyl ether despite its administration at lower anesthetic concentrations (0.005–0.03%). Chang et al., by means of electron microscopy, further demonstrated cellular changes (such as degeneration of the mitochondria, endoplasmic reticulum, and bile canaliculi) in the liver of rats (Figs. 1 and 2) which were exposed to subclinical level of halothane

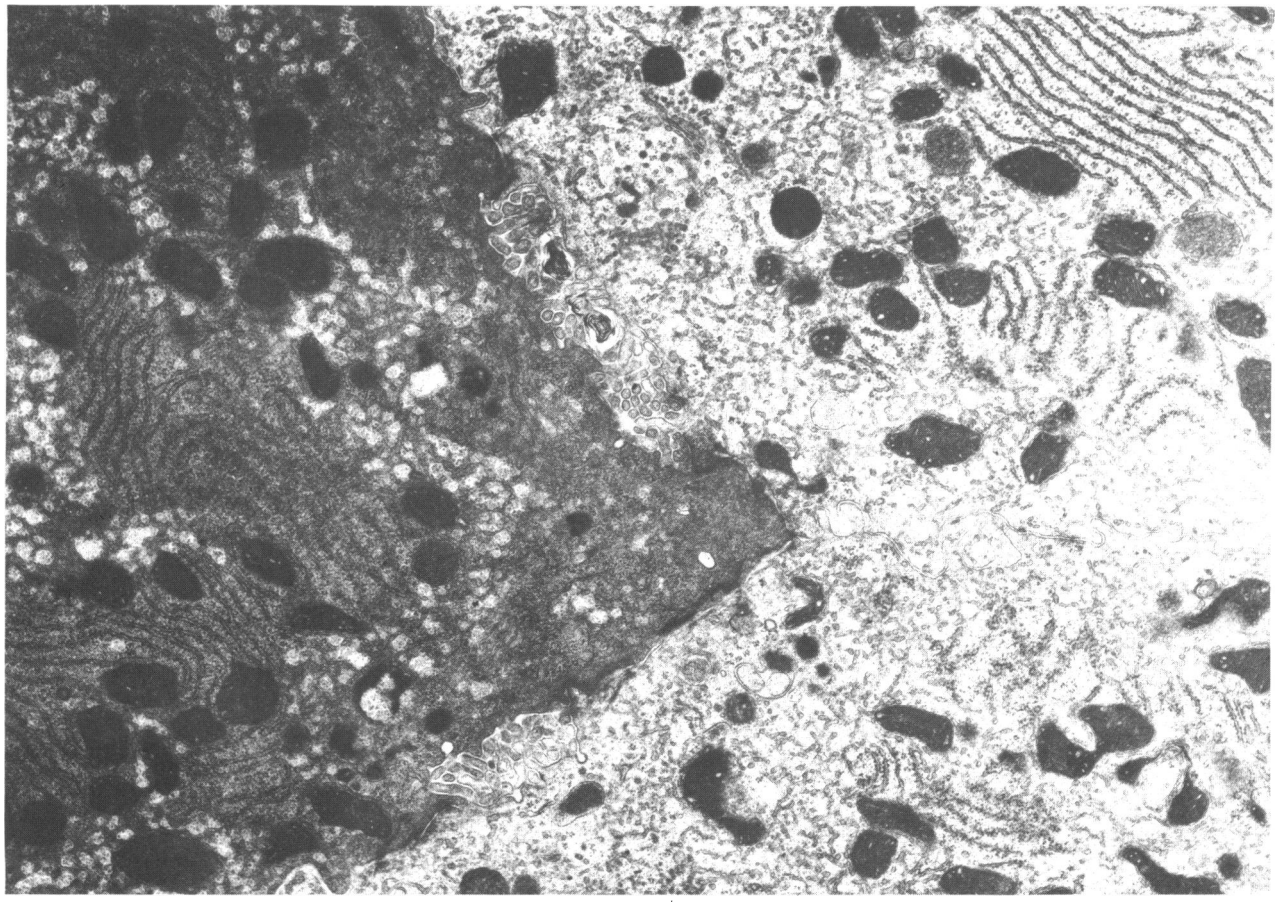

FIGURE 1. Liver, adult rat, 10 ppm halothane, 8 weeks. Mitochondria of the hepatocytes appear to be condensed and of irregular shape. Increase of cytoplasmic density of hepatocyte is also evident indicating cellular injury. × 9,158.

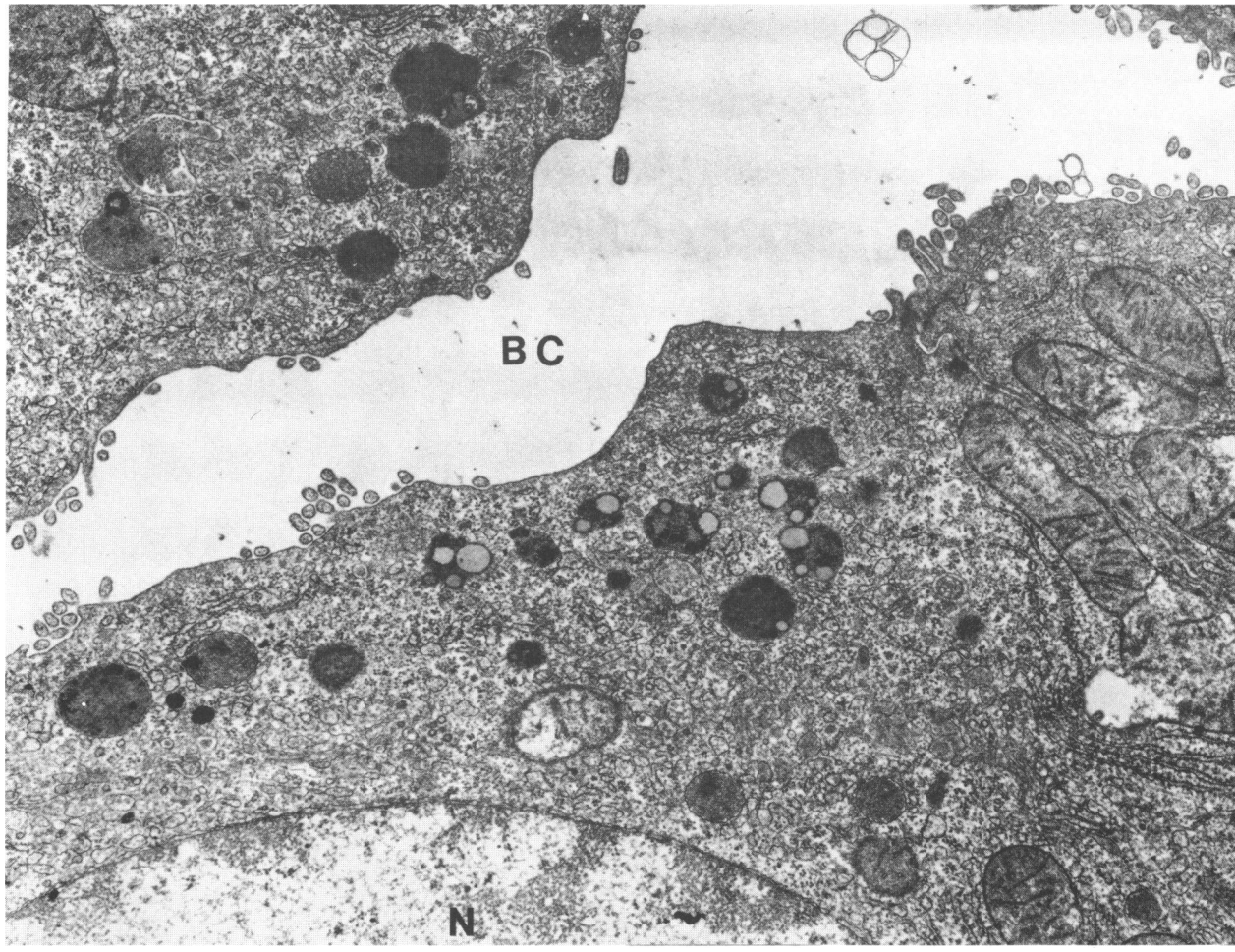

FIGURE 2. Liver, adult rat, 500 ppm halothane, 4 weeks. Severe dilatation of the bile canaliculi (BC) with peribiliary accumulation of lysosomes. × 12,753.

(10–500 ppm) for 4–8 weeks (*11*). When pregnant rats were exposed to halothane gas under similar conditions, degenerative changes (such as fatty changes, leukocytic infiltration, accumulation of lysosome, and cellular necrosis) were also observed in the livers of the offspring (*34*) (Figs. 3 and 4).

Despite increasing evidence indicating that halothane is hepatotoxic, incidence of fully recognizable hepatic necrosis in human patients following halothane anesthesis is very low (*47*). However, Stevens et al. have cautioned that perhaps the extent of hepatic injury following halothane anesthesia in man is not as rare as the incidence of massive hepatitis would suggest (*46*). They point out that an elevation of SGPT was frequently found in patients following halothane anesthesia. Moreover, prolonged elevations of sulfobromophthalein retention was found in volunteers subjected to halothane anesthesia than with isoflurane. These findings would indicate that a mild hepatic injury is not really uncommon following halothane anesthesia (*46*).

At least two explanations have been suggested for the hepatotoxic effects of halothane. It was suggested that since granuloma formation and eosinophilia are sometimes associated with halothane hepatitis (*37*), hypersensitivity may underlie the pathogenic mechanism of halothane hepatitis (*48–55*). A sensitivity phenomenon of antibody–antigen type could occur if a hapten is formed by conjugation of the liver protein to the halothane molecule, or a metabolite of it. However, increasing evidence has indicated that halothane, or its metabolite, probably has a direct hepatotoxic effect on the liver. Damage to liver cells following halothane exposure in dogs (*56*), mice (*46, 57*), guinea pigs (*12, 46*), and rats (*9–11, 34, 36, 58*) have been reported. It is believed that, as in the case of some other volatile anesthetics such as chloroform or some other halogenated compounds such as carbon tetrachloride, there may be a toxic intermediate

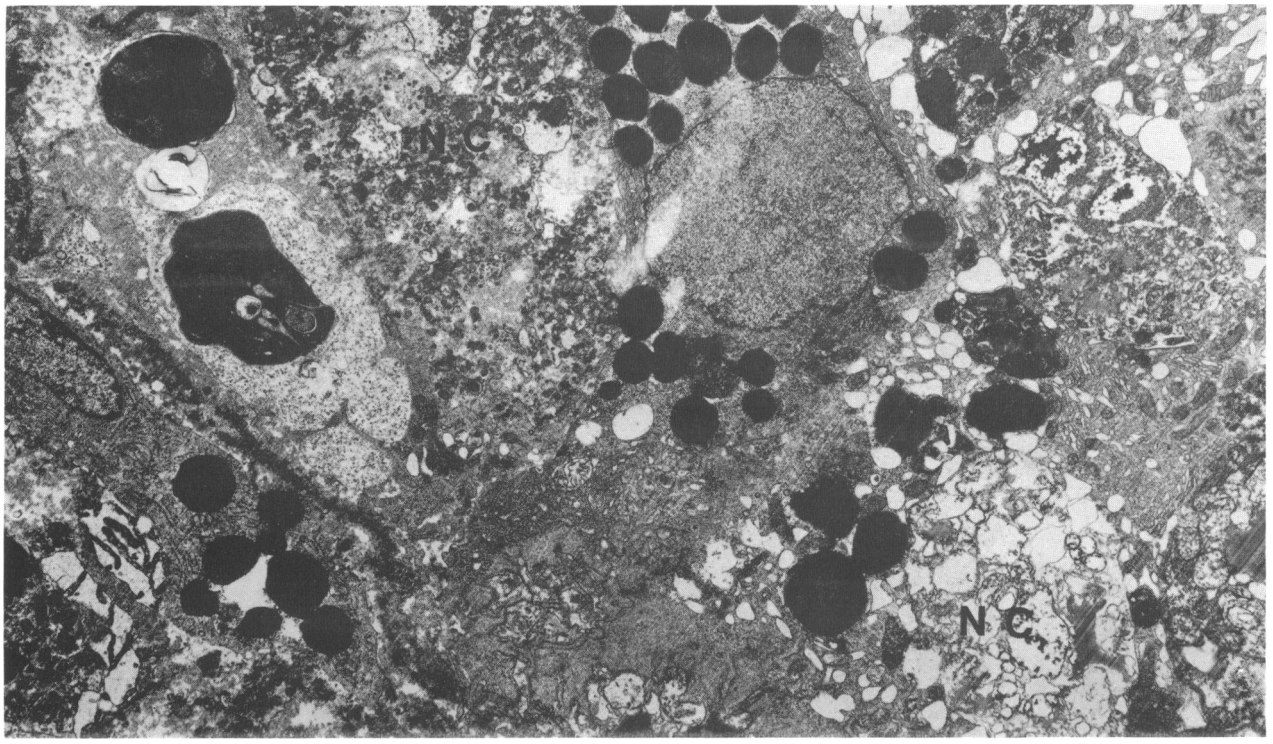

FIGURE 3. Liver, neonatal rat, 10 ppm halothane through pregnancy. Fatty changes and extensive necrosis of the hepatocytes (NC) are observed. × 4,409.

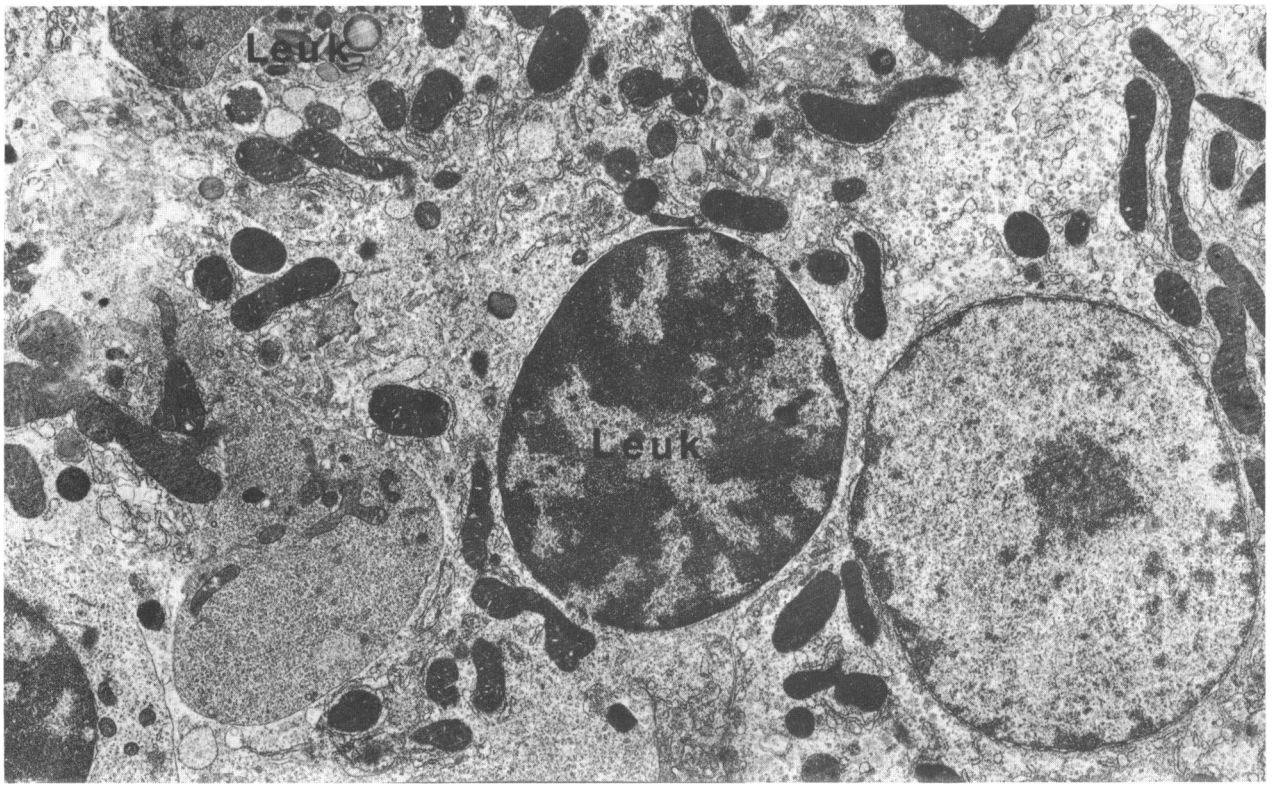

FIGURE 4. Liver, neonatal rat, 10 ppm halothane through pregnancy. Infiltration of leukocytes (Leuk) is evident. × 5,766.

metabolite which accumulates within the biological tissues (*7, 59*). Cohen and Hood revealed an accumulation of metabolites from volatile anesthetics such as halothane (*60, 61*), but these metabolites were tissue bound to the cell constituents and were not extractable at the present time. Of interest from a chronic low dose exposure point of view is the fact that the hepatic halothane metabolism is concentration-dependent (*62*). More metabolism and breakdown of halothane occurred in the liver of subjects who were exposed to lower concentration of the agent. If the metabolites of halothane are responsible for liver damage, chronic exposure to low levels of halothane would then be more toxic than acute exposures.

Pathological Effects on the Kidney

It has been claimed that some fluorinated anesthetics, methoxyfluorane in particular (*63–71*), are nephrotoxic. The nephrotoxicity is largely attributed to the accumulation of inorganic fluoride in the renal tubules (*67, 68, 70, 72, 73*). Although there are no known reports of high-output renal failure in anesthetists, it is interesting that Bruce et al. reported a twofold increase in chronic renal disease as a cause of death among anesthetists in the period from 1957 to 1966 over the period from 1947 to 1956 (*74*). It was during the latter 10-year period that the fluorinated anesthetic agents were introduced. Halothane must be considered a possible nephrotoxic agent because it is a fluorinated compound. However, because there was no significant alteration in the renal function of human volunteers who were subjected to short-term exposures to acute doses of methoxyfluorane and halothane (*75*), no histologic or cytologic studies of the kidney were performed.

In a recent report (*32*), the renal changes following chronic exposure to halothane was demonstrated by electron microscopy. Adult rats which were exposed to 10–500 ppm halothane for 4-8 weeks demonstrated tubular lesions (proximal convoluted tubules, PCT) in the kidney. Degeneration of the mitochondria, forming large membranous bodies, were frequently found (Fig. 5). Accumulation of atypical lysomes was also observed in the proximal tubular epithelial cells (*32*) (Fig. 6). Simi-



FIGURE 5. Kidney, adult rat, 500 ppm halothane 4 weeks. Extensive accumulation of membraneous bodies, presumably derived from degenerated mitochondria, within an epithelial cell of the proximal tubule. × 19,537.

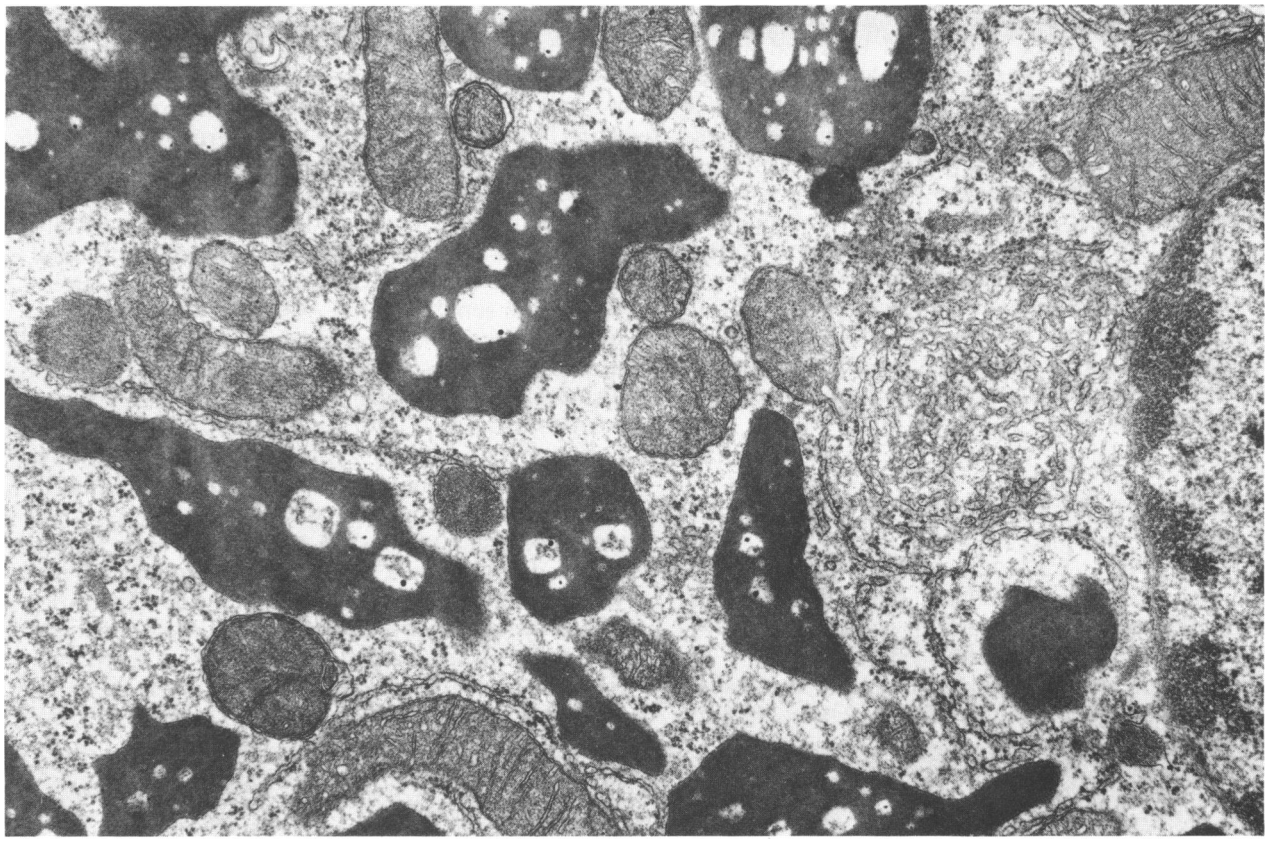

FIGURE 6. Kidney, adult rat, 500 ppm halothane, 4 weeks. Accumulation of atypical lysosomes (appear to be irregular dense bodies, presumably through tusion of lysosomes) within an epithelial cell of the proximal tubule. × 19,537.

lar changes of the lysomes have been reported in methoxyflurane nephropathy (*68*), choline-deficient rats (*76*), manganese-deficient mice (*77*), and in mice with Chediak-Higashi syndrome (*78*). It has been proposed that these abnormal lysosomal structures might be directly related to an alteration in the lysosomal functions (*78*).

Besides the mitochondrial and lysosomal changes, accumulation of spherical particles in the basement membrane (Fig. 7) extrusion of large cytoplasmic masses (exocytosis) into the tubular lumen (Fig. 8) aggregation of smooth endoplasmic reticulum, and swirling of the basal plasma membrane (Fig. 9) were also observed in the PCT of the kidney (*32*). The occurrence of clusters of spherical microparticles within the basement membrane as well as the exocytosis of cytoplasmic material have been described in both human and animal kidneys under diseased situations (*79–82*). It is believed that these phenomena represent discharge or extrusion of cellular debris and material from injured cells. The formation of smooth endoplasmic reticulum aggregates (hyperplastic hypoactive endoplasmic reticulum), the swirling of basal plasma membrane, however, may only represent a "normal" detoxification and compensatory response of the kidney towards the halothane toxicity and its effects of the transport system of the cell membrane (*83*).

Chang and co-workers further reported the pathological changes in the neonatal kidneys from newborn rats which subjected to prenatal exposure to low levels (10 ppm) of halothane (*33*). General degenerative changes such as mitochondria swelling (Fig. 10), accumulation of lysosomes and lipid droplets (Fig. 11), and enlargement of the apical vacuoles (Fig. 12) were observed. These degenerative changes were found to be confined to the proximal convoluted tubules only. Massive cellular casts and cytoplasmic materials were also found within the tubular lumen indicating tubular injury.

Pathological Effects on the Nervous System

Three reports in the European literature suggest headaches and irritability in anesthetists as occupational hazards (*14, 84, 85*), possibly attribute to the direct effects of the agent on the brain or cerebral vessels. A survey of Russian anesthetists indicates an increase in functional disturbances of the central

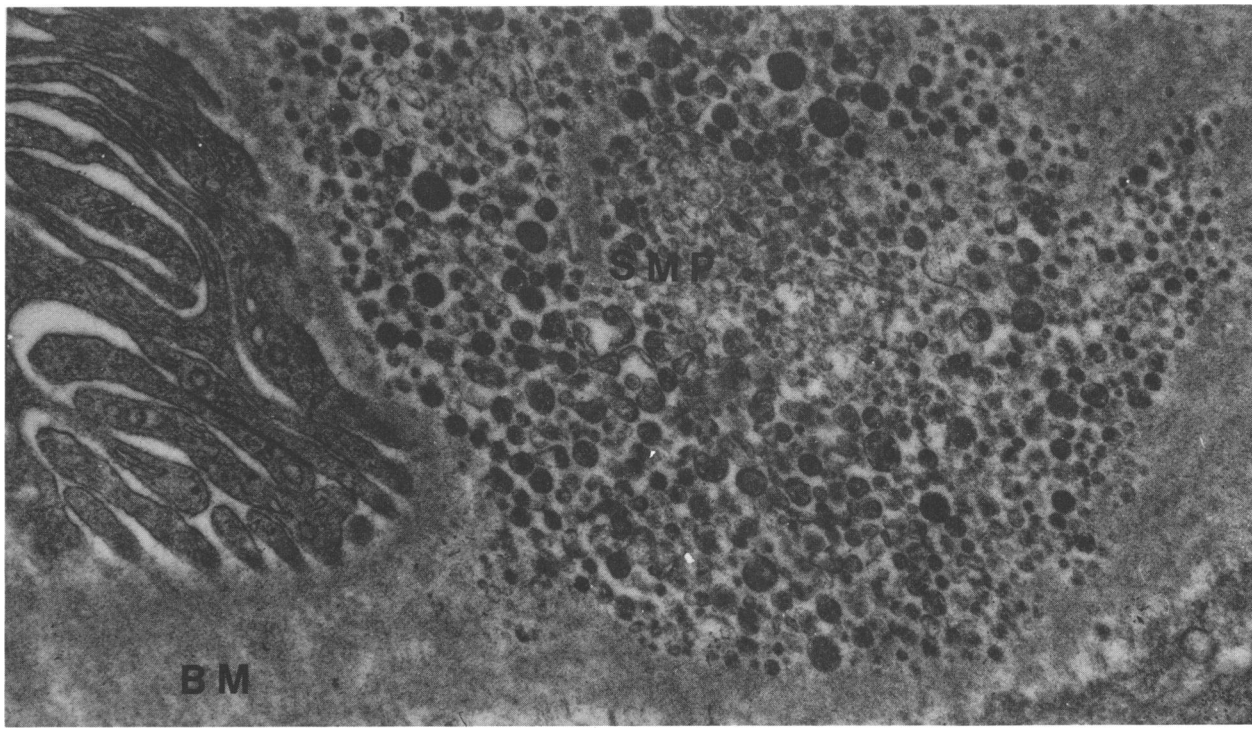

FIGURE 7. Kidney, adult rat, 500 ppm halothane, 4 weeks. Accumulation of spherical microparticles (SMP) in the basement membrane (BM) of the proximal tubules. × 28,491.

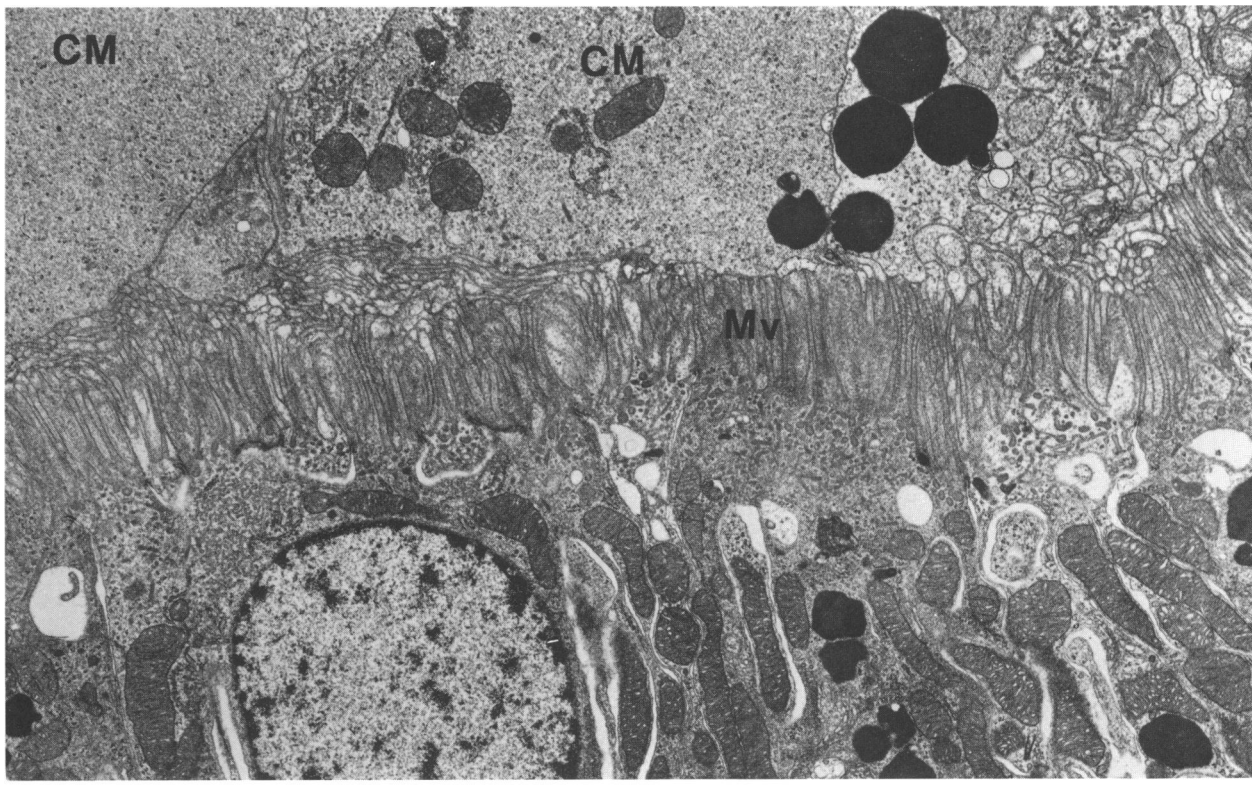

FIGURE 8. Kidney, adult rat, 500 ppm halothane, 4 weeks. Extension of large cytoplasmic masses (CM) and organelles into the tubular lumen. × 5,766.

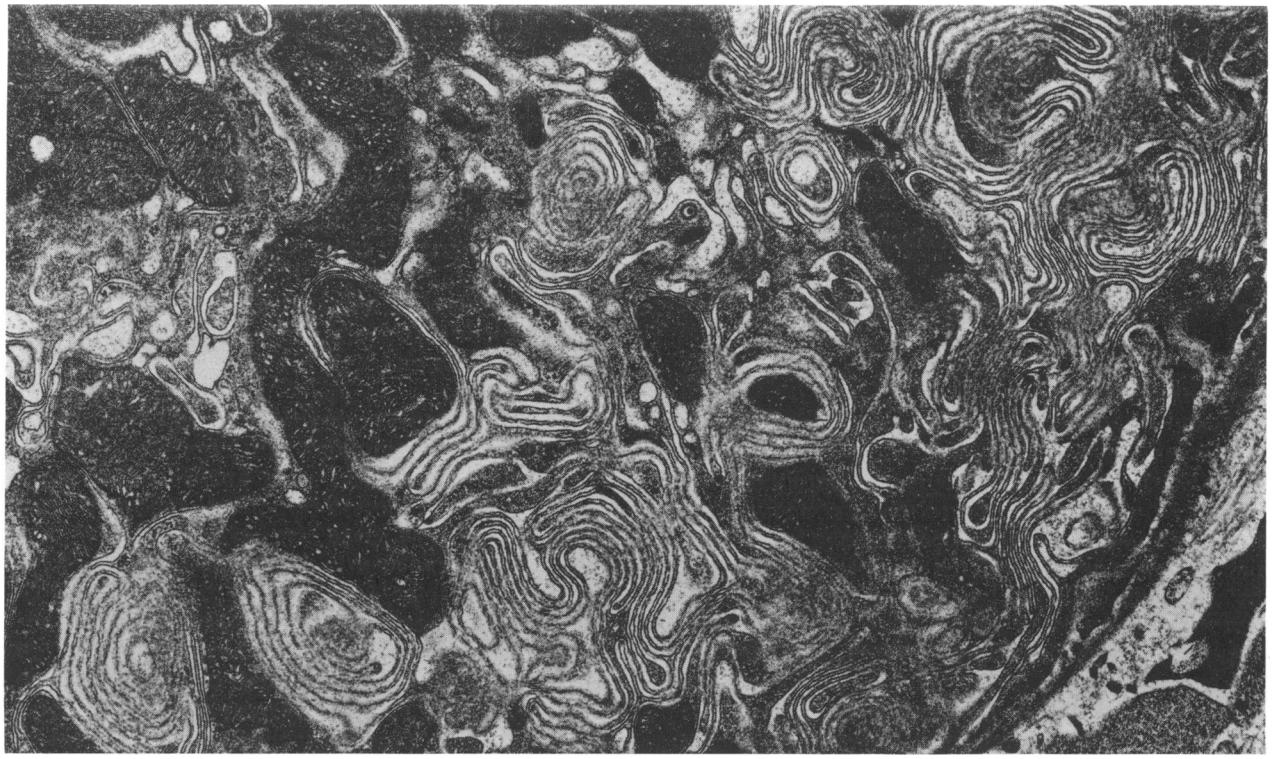

FIGURE 9. Kidney, adult rat, 500 ppm halothane, 4 weeks. Swirling of the basal infoldings (plasma membrane) of the epithelial cells in the proximal tubules. × 12,753.

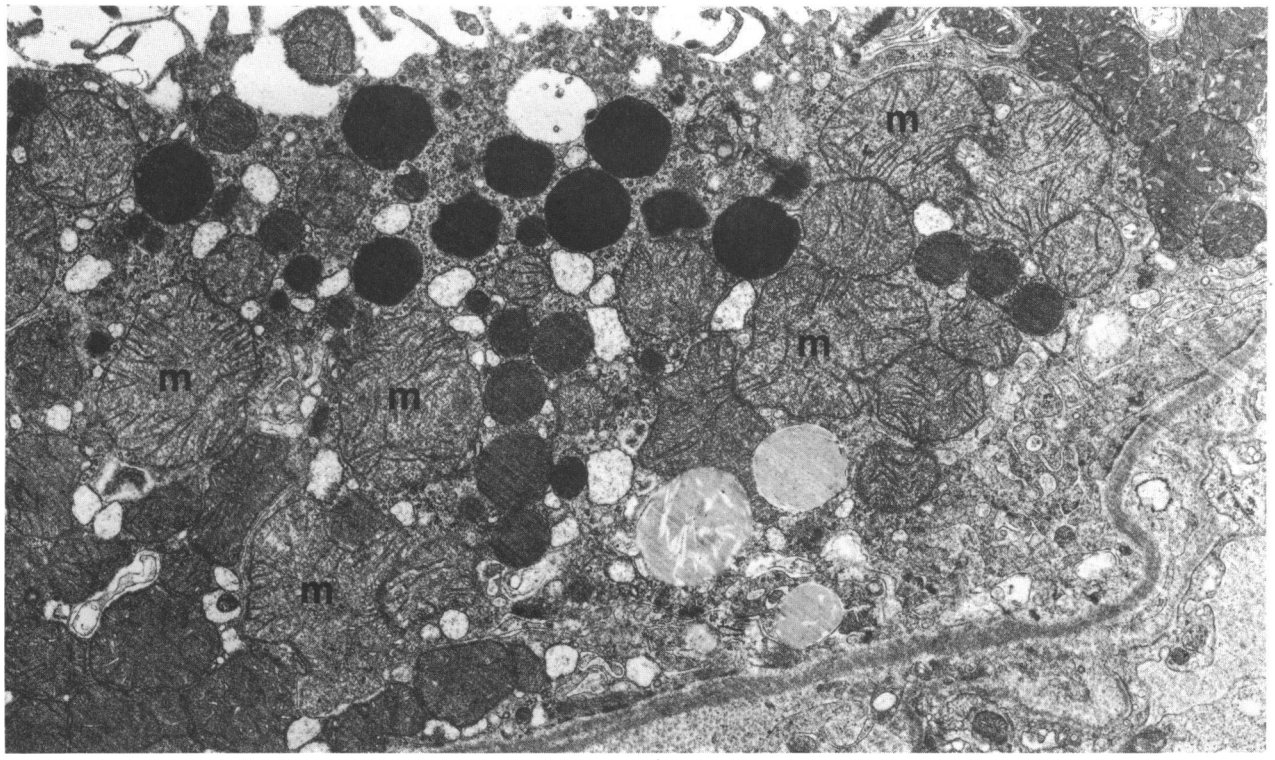

FIGURE 10. Kidney, neonatal rat, 10 ppm halothane through pregnancy. A degenerative tubule with much lysosomes and swollen mitochondria (M). × 5,766.

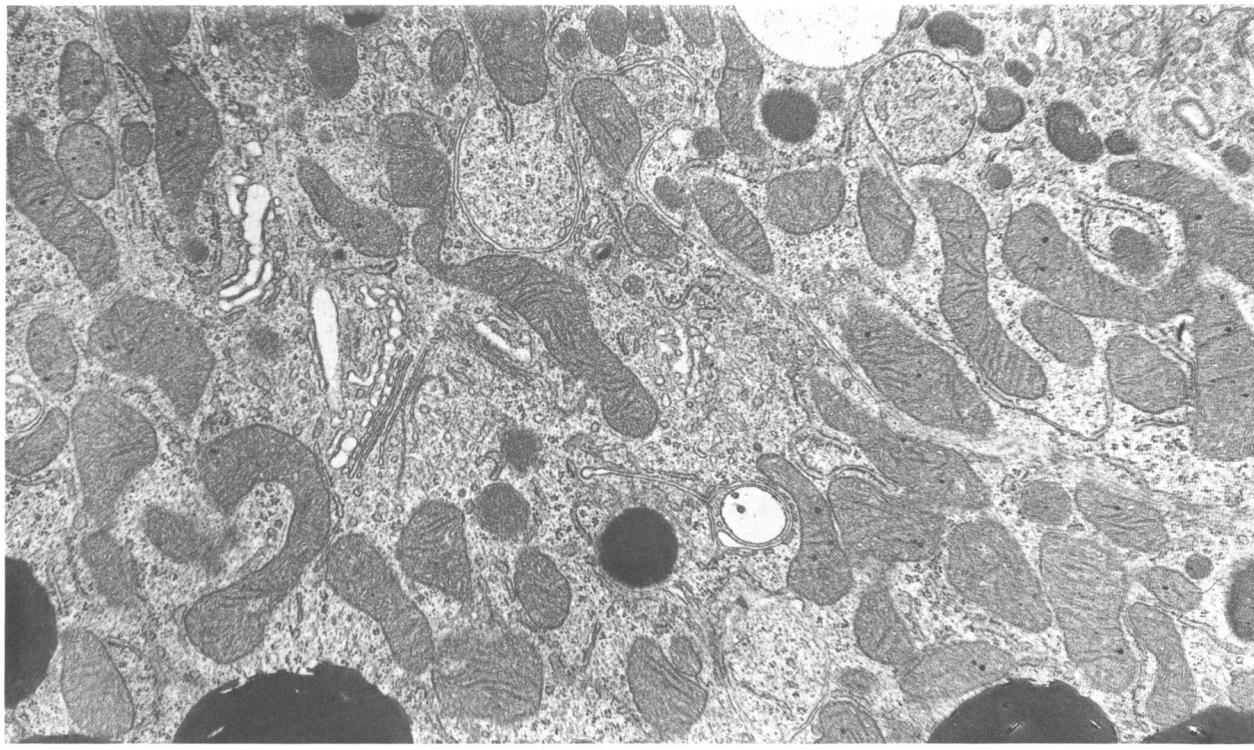

FIGURE 11. Kidney, neonatal rat, 10 ppm halothane through pregnancy. Accumulation of lipid droplets at the basal portion of the epithelial cells of the proximal tubules. × 12,753.

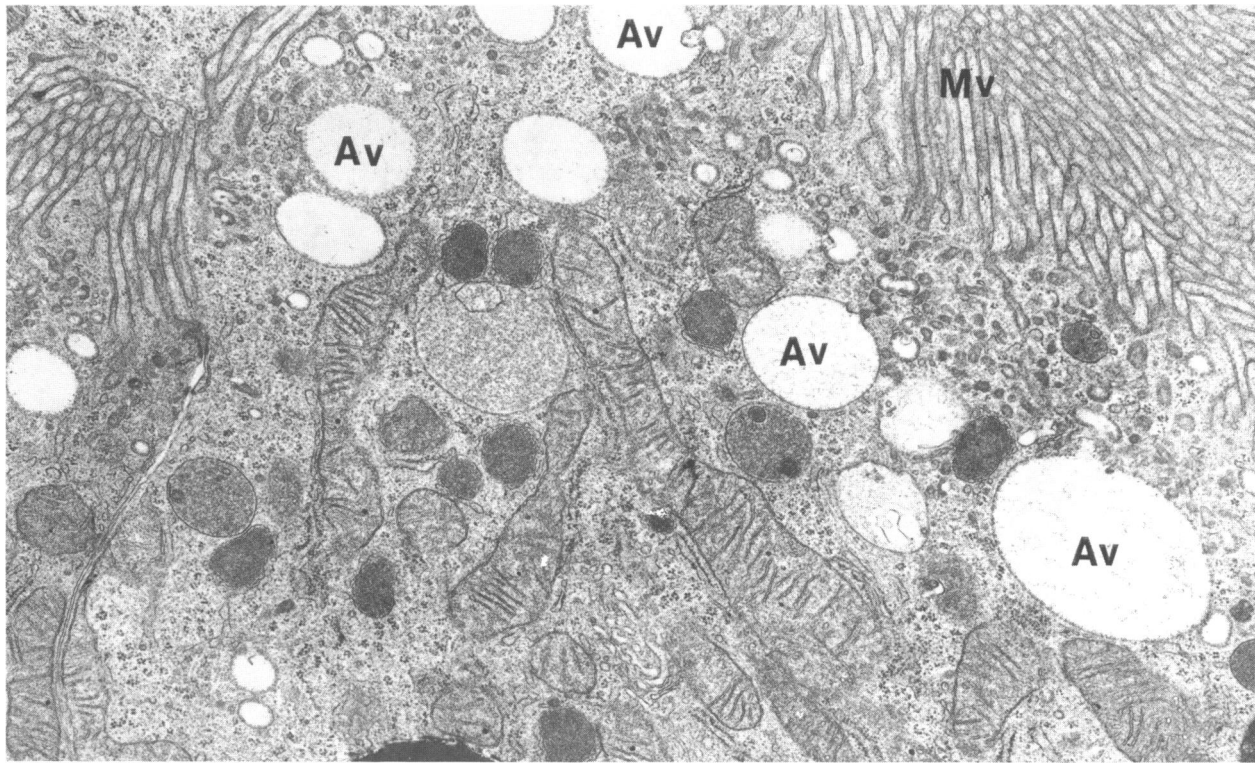

FIGURE 12. Kidney, neonatal rat, 10 ppm halothane through pregnancy. Enlargement of the apical vacuoles (AV) in the proximal epithelial cell. × 12,753.

system following prolonged exposure to poorly ventilated operating rooms (*14*). Various investigators (*20, 86, 87*) also indicated that acute exposure to subanesthetic concentrations of anesthetics produces temporary deficits in a variety of human behavioral function, including memory, mood, and psychomotor impairment.

Due to its small molecular size and high lipid solubility, halothane as well as other anesthetics, readily transfers across the blood-brain barrier (*88*). An autoradiographic study (*89*) indicated that halothane is distributed to the cerebral cortical gray matter rapidly during exposure. Despite the known physiological effects of halothane on the nervous system (*90*), little investigation has been performed to study any morphological changes in the nerve cells following exposure to halothane.

It is not until in a recent report (*29*) that the information concerning the morphological changes in the brain as a result of halothane exposure was made available. Chang and co-workers described that as a result of chronic exposure (4–8 weeks) to low levels (10–500 ppm) of halothane, degeneration changes such as severe vacuolation of the Golgi complex (Figs. 13 and 14) and collapse of the rough endoplasmic reticulum (RER) (Fig. 15) could be observed in some cortical neurons of the rat brain (*29*). The significance of the Golgi vacuolation is still not fully understood. However, the disruption of the RER certainly denoted a dysfunction of protein synthesis in these neurons. Neuronal death was also occasionally observed. Chang and co-workers (*30*) further reported degenerative changes in the cortical neurons of neonatal rats which were prenatally exposed to halothane (pregnant animals were exposed to 10 ppm halothane during pregnancy). Degeneration of the Golgi complex was again a prominent pathological feature (Figs. 16 and 17). Weaking and focal disruption of the neuronal nuclear membrane (Figs. 18 and 19) was also a frequent finding. Such lesions may lead to eventual cell deaths. Accumulation of cytoplasmic debris and lysosomes could still be observed within some neuronal processes and macrophages (Fig. 20) in 100-day-old rats which were subjected to prenatal halothane exposure indicating that the damage to the nerve cells in these animals by halothane or its metabolite is an unduring one. Learning deficits in rats which were exposed to halothane during early life has been reported (*35*). Such finding further

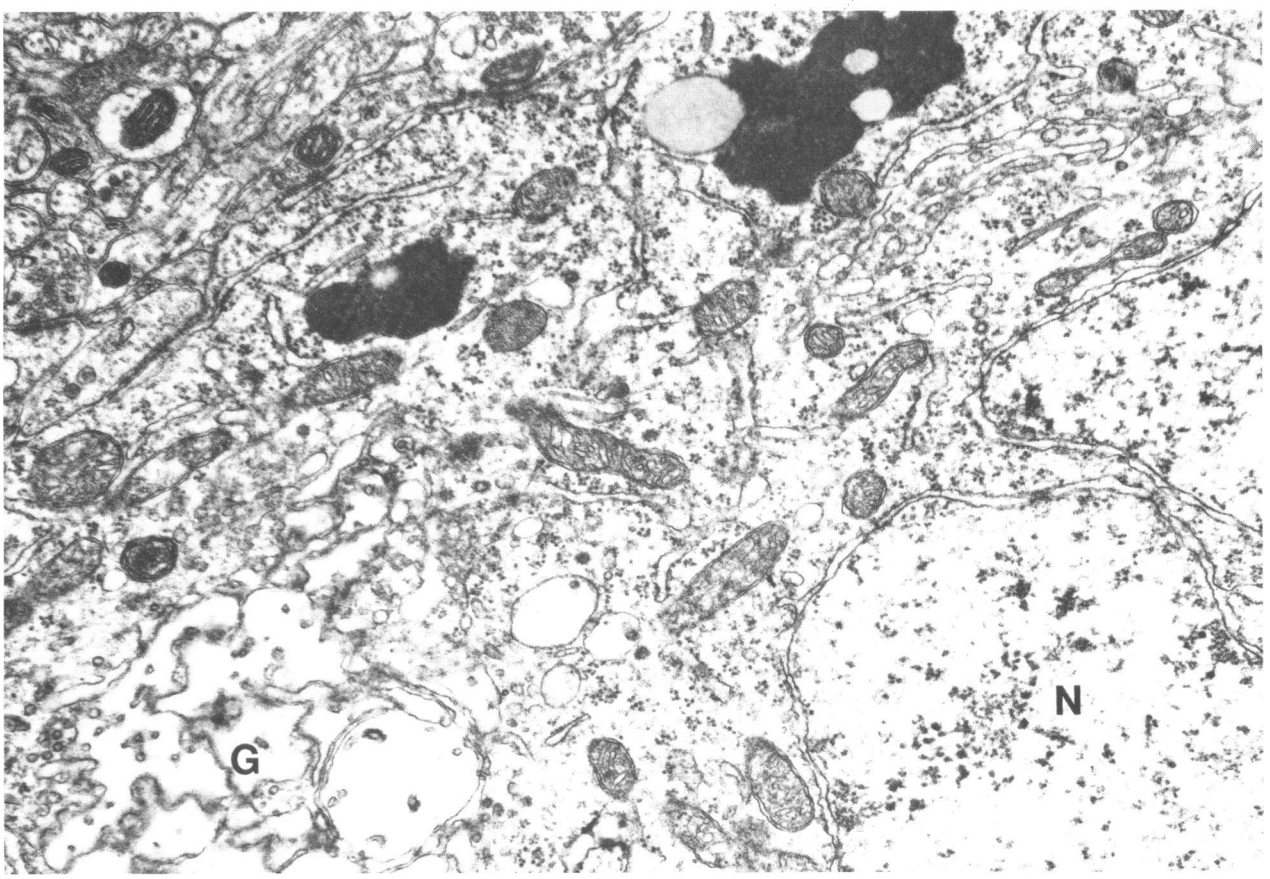

FIGURE 13. Cerebral cortex, adult rat, 500 ppm halothane, 4 weeks. Degradation of the neuronal Golgi complex (G) is seen. × 19,537.

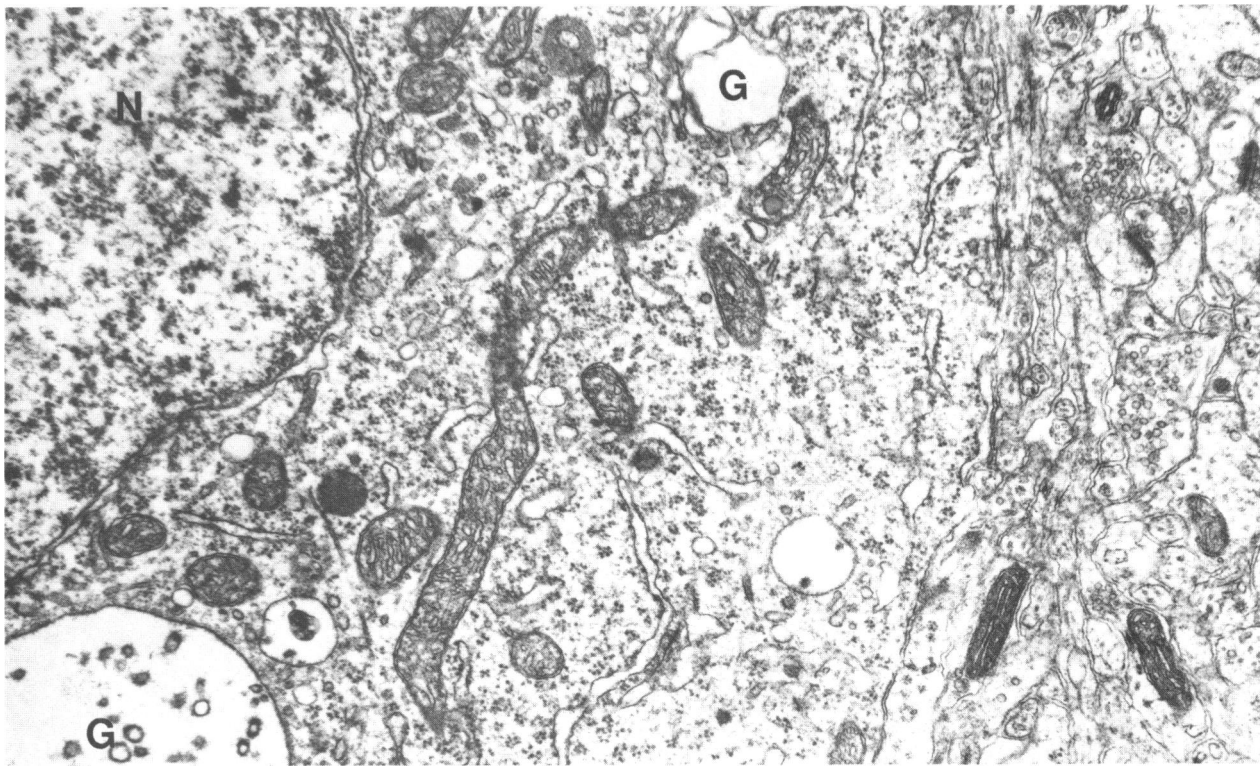

FIGURE 14. Cerebral cortex, adult rat, 500 ppm halothane, 4 weeks. Extensive degradation and vacuolation of the Golgi complex (G). × 19,537.

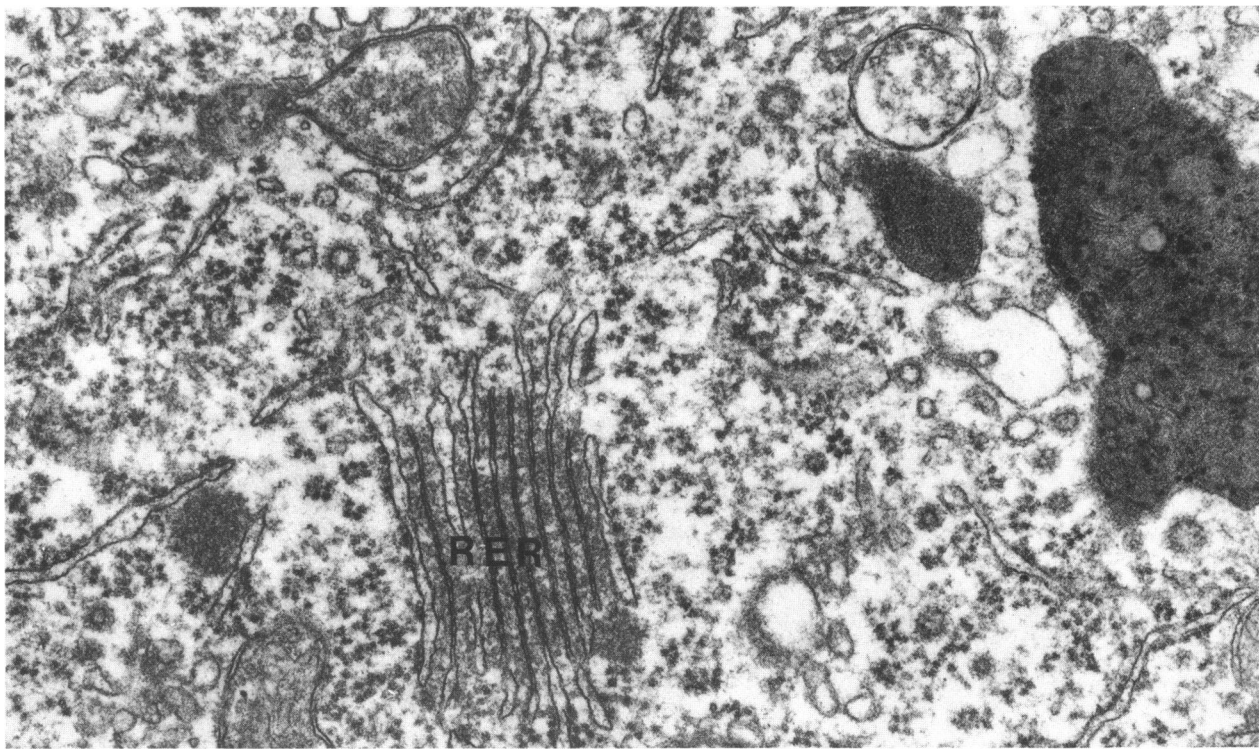

FIGURE 15. Cerebral cortex, adult rat, 500 ppm halothane, 4 weeks. Collapse of the rough endoplasmic reticulum (RER). No ribosome is observed on the collapsed portion of the endoplasmic reticulum. × 39,142.

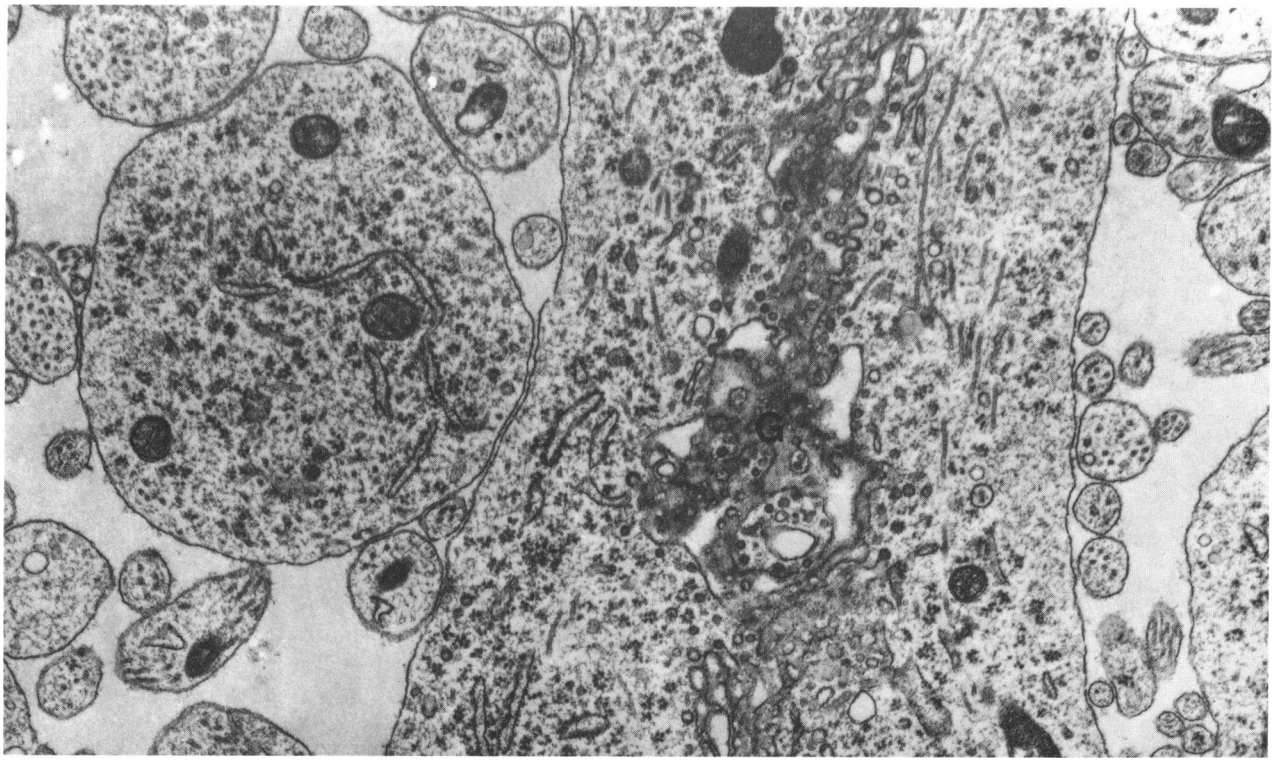

FIGURE 16. Cerebral cortex, neonatal rat, 10 ppm halothane through pregnancy. Dissolution of the Golgi complex (G) in a neuron. × 19,537.

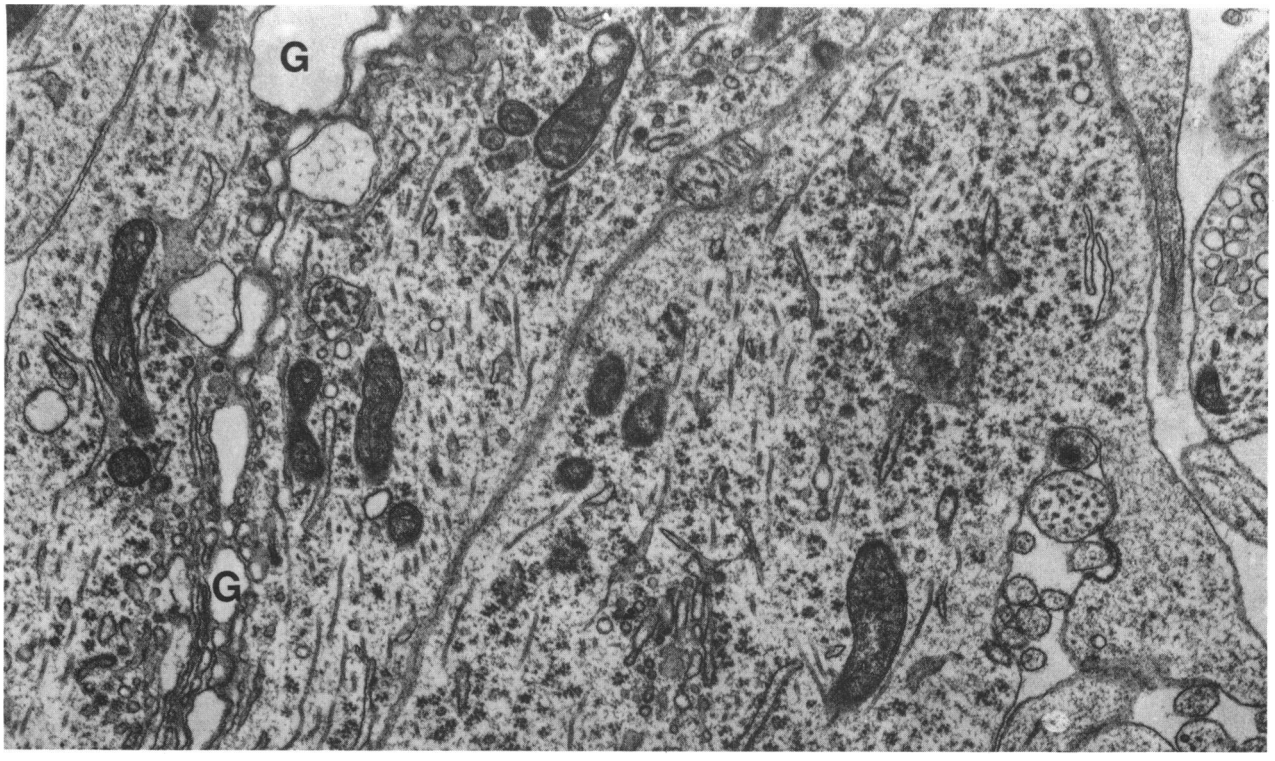

FIGURE 17. Cerebral cortex, neonatal rat, 10 ppm halothane through pregnancy. Dilation and vacuolation of the neuronal Golgi complex (G) × 19,537.

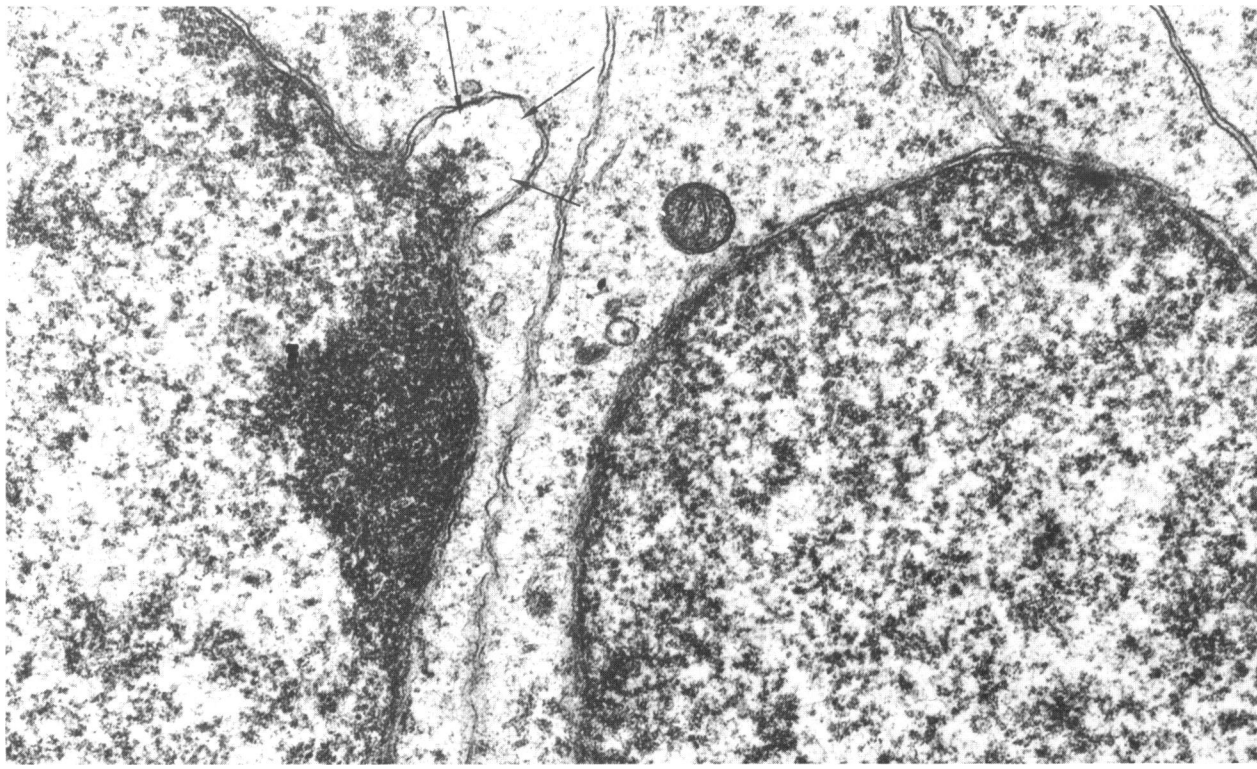

FIGURE 18. Cerebral cortex, neonatal rat, 10 ppm halothane through pregnancy. Weakening and out-pouching of the neuronal nuclear membrane (⟶). × 28,627.

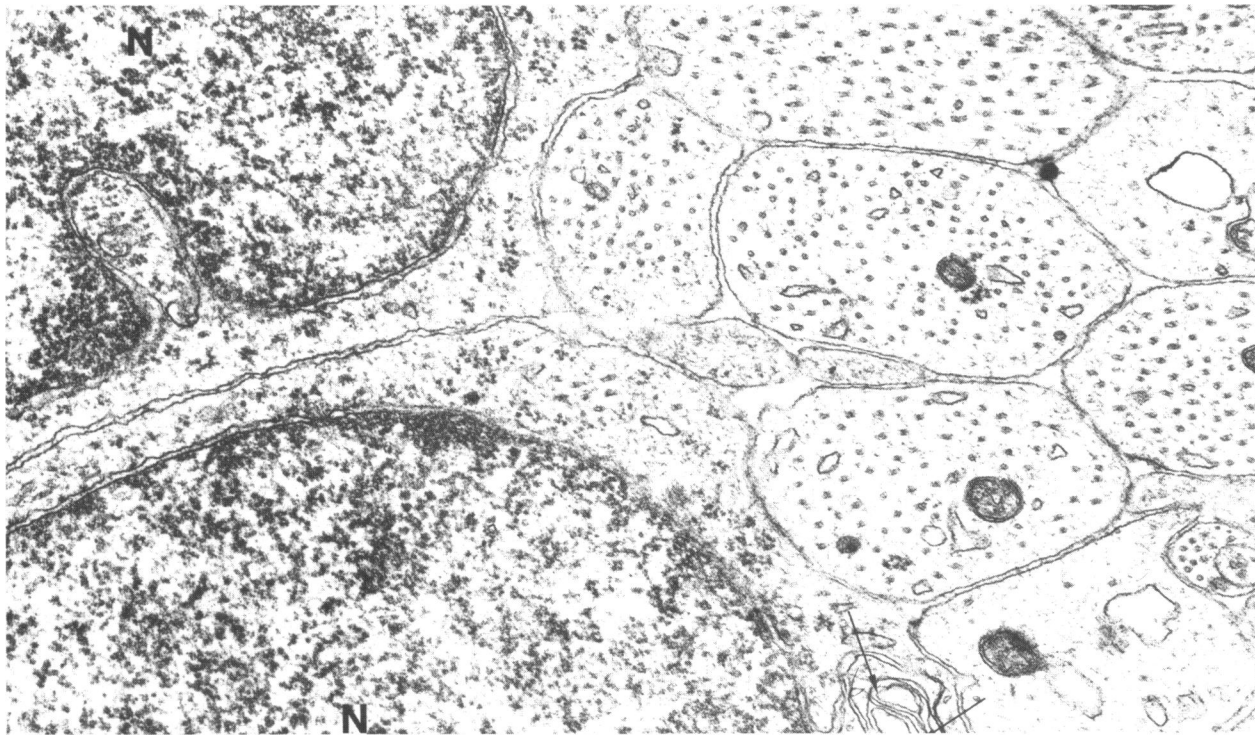

FIGURE 19. Cerebral cortex, neonatal rate, 10 ppm halothane through pregnancy. Myelin-figure formation by the neuronal nuclear envelop (⟶). × 28,627.

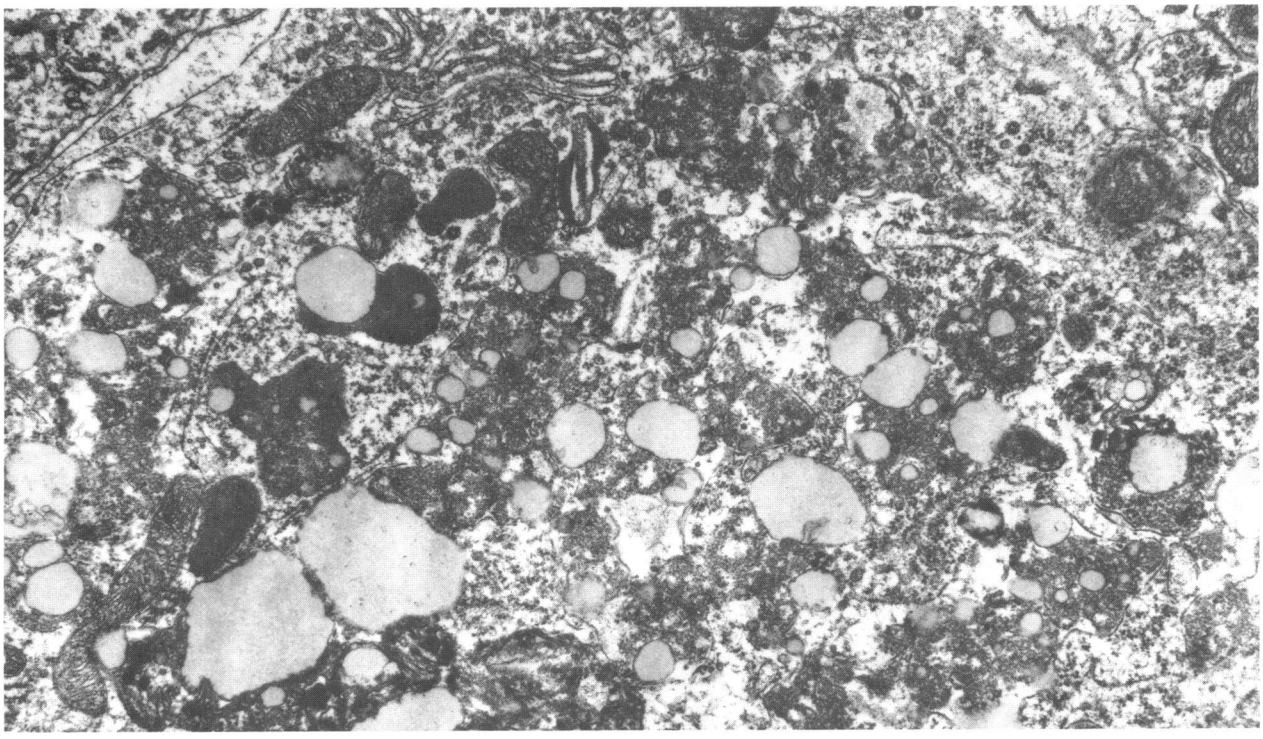

FIGURE 20. Cerebral cortex, adult rat, 10 ppm halothane inuteral exposure. Degenerative products are still observable in some macropheyes. × 19,537.

supports the concept that halothane may exert an undesirable effect on the developing nervous system.

Concluding Remarks

The present review represents an overview of the pathological findings in the liver, kidney, and nervous system of the adult and neonatal rats following chronic exposure to low levels of halothane. From all the information collected to date, one may conclude that halothane could have a direct cellular toxicity. In view of the various pathological involvements (mitochondria, plasma membrane, Golgi couplex, endoplasmic reticulum etc.) it appears that the biological membrane system could be one of the prime targets of action by halothane.

Since all the present observations were based on laboratory animals under experimental conditions, direct extrapolation of these findings to human situations may be overly hasty at this time. These findings should only serve as an indication and basis for further studies on the effects of halothane or the biological system and human subjects.

REFERENCES

1. Raventos, J. Action of fluothane: a new anesthetic. Brit. J. Pharmacol. 11: 394 (1956).
2. Barton, J. D. M., Jaundice and halothane. Lancet 1: 1097 (1959).
3. Brody, G. L., and Sweet, R. B. Halothane anesthesia as a possible cause of massive hepatic necrosis. Anesthesiology 24: 29 (1963).
4. Temple, R. L., Cote, R. A., and Gorens, S. W. Massive hepatic necrosis following general anesthesia. Anesth. Analg. 41: 86 (1962).
5. Qizilbash, A. H. Halothane hepatitis. Can. Med. Assoc. J. 108: 171 (1973).
6. Ngai, S. H. Hepatic effects of halothane-reviews of the literature. In: The National Halothane Study, J. P. Bunker et al., Eds., National Institute of Health and National Institute of General Medical Sciences, Bethesda, Md., 1969, pp. 11.
7. Carney, F. M. T., and Van Dyke, R. A. Halothane hepatitis—a critical review. Anesth., Analg. 51: 135 (1972).
8. Simpson, B. R., Strunin, L., and Walton, B. Halothane hepatitis—fact or fallacy. Bull. N.Y. Acad. Med. 49: 708 (1973).
9. Ross, W. T., and Cardell, R. R. Effects of halothane on the ultrastructural of rat liver cells. Amer. J. Anat. 1972, 135.
10. Chang, L. W., Dudley, A. W., Jr., and Katz, J. Ultrastructural evidence of hepatic injuries by chronic exposure to low levels of halothane. Amer. J. Pathol. 74: 103a (1974).
11. Chang, L. W., et al. Ultrastructural studies of the hepatocytes following chronic exposure low levels of halothane. Exp. Mol. Pathol. 23: 35 (1975).
12. Hughes, H. C., and Lang, C. M. Hepatic necrosis produced by repeated administration of halothane to guinea pigs. Anesthesiology 35: 466 (1972).
13. ASA Scientific Panel. A preliminary report: the hazard of trace anesthetics in unventilated operating rooms. Anesth. Rev. 1: 22 (1974).

14. Vaisman, A.I. Working conditions in surgery and their effect on the health of anesthesiologists. Eksp. Klur. Anesth. 3: 44 (1967).
15. Vskrog, V., and Harvald, B. Teratogen effects of inhalation anesthika. Nord. Med. 83: 490 (1970).
16. Cohen, E. N., Bellville, J. W., and Brown, B. W. Anesthesia, pregnancy, and miscarriage: a study of operating room nurses and anesthetics. Anesthesiology 35: 343 (1971).
17. Smith, B. E., Gaub, M. L., and Moya, F. Investigations into the teratogenic effects of anesthesia agents: the flurinated agents. Anesthesiology 26: 260 (1965).
18. Gotell, P., and Sundell, L. Anesthetists exposure to halothane. Lancet 1: 424 (1972).
19. Linde, H. W., and Bruce, D. L. Occupational exposure of anesthetists to halothane, nitrous oxide and radiation. Anesthesiology 30: 363 (1969).
20. Bruce, D. L. Trace anesthetic effects on perceptual and cognitive skills, Anesthesiol. Rev. 1: 24 (1974).
21. Corbett, T. H., and Ball, G. L. Chronic exposure to methoxyflurane: a possible occupational hazard to anesthesiologists. Anesthesiology 34: 532 (1971).
22. Whitcher, C. E., Cohen, E. N., and Trudell, J. R. Chronic exposure to anesthetic gases in the operating room. Anesthesiology 35: 348 (1971).
23. Askrog, V., and Peteraon, R. Forurening of operationsstuer med luftformige anesthetike of rontgenbestraling. Nord. Med. 83: 501 (1970).
24. Bruce, D. L. What is a "safe" interval between halothane exposures? J. Amer. Med. Assoc. 221: 1140 (1972).
25. Jenkins, L. C. Chronic exposure to anesthetics—a toxicity problem? Can. Anesth. Soc. J. 20: 104 (1973).
26. Linde, H. W., and Bruce, D. L. Effects of chronic exposure of rats to traces of halothane. Progress in Anesthesiology, Excerpta Med. Intern. Congr. Serial No. 200: 923 (1968).
27. Corbett, T. H. Anesthetics as a cause of abortion. Fertility and Sterility 23: 866 (1972).
28. Corbett, T. H. Retention of anesthetic agents following occupational exposure. Anesth. Analg. 52: 614 (1973).
29. Chang, L. W., et al. Ultrastructural changes in the nervous system after chronic exposure to halothane in low levels. Exptl. Neurol. 45: 209 (1974).
30. Chang, L. W., Dudley, A. W., Jr., and Katz, J. Pathological changes in the nervous system following *in utero* exposure to halothane. Environ. Res. 11: 40 (1976).
31. Chang, L. W., et al. Ultrastructural changes in the kidney following chronic exposure to low levels of halothane. Amer. J. Pathol. 78: 225 (1975).
32. Chang, L. W., et al. Ultrastructural studies on the pathological changes in the neonatal kidney following *in utero* exposure to halothane. Environ. Res. 10: 74 (1975).
33. Chang, L. W., et al. Nervous system development following *in utero* exposure to trace amounts of halothane. Teratology 9: A-15 (1974).
34. Chang, L. W., et al. Ultrastructural evidence of hepatotoxicity of halothane in rats following *in utero* exposure. Can. Anesth. Soc. J. 22: 330 (1975).
35. Quimby, K. L., et al. Enduring learning deficits and cerebral synaptic malformations from exposure to 10 ppm halothane. Science 185: 625 (1974).
36. Gail, E. Report of the pathology panel: national halothane study. Anesthesiology 29: 233 (1968).
37. Qizilbash, A. H. Halothane hepatitis. Can. Med. Assoc. J. 108: 171 (1973).
38. Smuckler, E. A. The pathology of halogenated hydrocarbons and halothane: a brief review and speculation. In: Cellular Biology and Toxicity of Anesthetics. B. R. Fink, Ed., Williams and Wilkins, Baltimore, 1972, p. 221.
39. Inamoto, A., Okamoto, T., and Matsuo, Y. Electron microscope investigation on the hepatotoxicity effects following the repeated use of various inhalation anesthetic agents. Prog. Anesth. Proc. World. Congr. Anesth., London, 1968, p. 913.
40. Corssen, G. Cytotoxic effects of halogenated anesthetics. In: Toxicity of Anesthetics. B. R. Fink, Ed., Williams and Wilkins, Baltimore, Md., 1968, p. 50.
41. Kilion, F. M., Schaffner, F., and Popper, H. Hepatitis after exposure to halothane. Ann. Int. Med. 71: 467 (1969).
42. Schaffner, F., and Paronetto, H. Immunological observations and electron microscopy of halothane-induced hepatic injury. In: Immunology of the Liver. M. Smith and R. Williams, Eds., F. A. Davis, Philadelphia, Pa., 1970, p. 186.
43. Keeley, A. F., et al. Anicteric halothane hepatitis: histologic and ultrastructural lesions associated with postoperative fever in two patients. Gastroenterology 58: 965 (1970).
44. Uzmalinoglu, B., Yardley, J., and Boitnott, J. The liver in mild halothane hepatitis. Amer. J. Pathol. 61: 457 (1970).
45. Schatzki, P. F., Kay, S., and McGavic, J. D. Ultrastructural pathology of a case of halothane hepatitis. Amer. J. Dig. Dis. 18: 905 (1973).
46. Stevens, W. C., et al. Comparative toxicities of halothane, isoflurane, and diethyl ether at subanesthetic concentrations in laboratory animals. Anesthesiology 42: 408 (1975).
47. Bunker, J. P., et al., Eds. The National Halothane Anesthesia and Post-Operative Hepatic Necroaia. Government Printing Office, Bethesda, Maryland, 1969.
48. Belfrage, S., Ahlgreen, I., and Axelson, E. Halothane hepatitis in anesthetist. Lancet 2: 466 (1966).
49. Mathieu, A., DiPadma, D., Mills, J. Experimental immunity to a metabolite of halothane and fluroxane: cutaneous delayed hypersensitivity. Anesthesiology 40: 385 (1974).
50. Klatskin, G., and Kinberg, D. V. Recurrent hepatitis attribute to halothane sensitivity antibodies in jaundice following drug administration. J. Amer. Med. Assoc., 208: 148 (1969).
51. Rodriquez, M., et al. Antimitochondria antibodies in juandice following drug administration. J. Amer. Med. Assoc. 208: 148 (1969).
52. Dorval, E., et al. Fatal halothane hepatitis with transient granulomas. New Engl. J. Med. 283: 357 (1970).
53. Doniach, D. Cell mediated immunity to halothane hypersensitivity. New Engl. J. Med. 283: 315 (1970).
54. Paronetto, F., and Popper, H. Lymphocyte stimulation induced by halothane in patients with hepatitis following exposure to halothane. New Engl. J. Med. 283: 277 (1970).
55. Sherlock, S. Progress report: halothane hepatitis. Gut 12: 324 (1971).
56. Stephen, C. R., Margolis, G., and Fabia, L. W. Laboratory observation with flurane. Anesthesiology 19: 770 (1958).
57. Jones, W. M., Margolis, G., and Stephen, C. R. Hepatotoxicity of inhalation anesthetic drugs. Anesthesiology 19: 715 (1958).
58. Scholler, V. Electron microscopic and autoradiographic studies on the effects of halothane and chloroform in liver cells. Acta Anesth. Scand. (Suppl.) 32: 1 (1968).
59. Van Dyke, R. A. Biotransformation of volatile anesthetics with special emphasis on the role of metabolism in the toxicity of anesthetics. Can. Anesthesiol. Soc. J. 20: 21 (1973).
60. Cohen, E. N., and Hood, N. Application of low temperature autoradiography to studies of the uptake and metabolism of volatile anesthetics in the mouse. I. Chloroform. Anesthesiology. 30: 306 (1969).
61. Cohen, E. N., and Hood, N. Application of low temperature autoradiography to studies of the uptake and metabolism of volatile anesthetics in the mouse. II. Diethyl ether. Anesthesiology 31: 61 (1969).
62. Sawyer, D. C., et al. Concentration dependence of hepatic halothane metabolism. Anesthesiology 34: 230 (1971).
63. Crandell, W. B., Pappas, S. G., and MacDonald, A. Ne-

phrotoxicity associated with methoxyflurane anesthesia. Anesthesiology 27: 591 (1966).
64. Pezzi, P. J., Probese, A. S., and Greenberg, S. R. Methoxyflurane and renal toxicity. Lancet 1: 823 (1966).
65. Elkington, S. G., Goffinet, J. A., and Conn, H. D. Renal and hepatic injury associated with methoxyflurane anesthesia. Ann. Med. Intern. 68: 1229 (1970).
66. Kuzucu, E. Y. Methoxyflurane, tetracycline and renal failure. J. Amer. Med. Assoc. 211: 1162 (1970).
67. Taves, D. R., Fry, R. W., and Freeman, R. B. Toxicity following methoxyflurane anesthesia. II. Fluoride concentrations in nephrotoxicity. J. Amer. Med. Assoc. 214: 91 (1970).
68. Kosek, T. C., Mazze, R. I., and Cousins, M. F. The morphology and pathogenesis of nephrotoxicity following methoxyflurane (penthrane) anesthesia—an experimental model in rats. Lab. Invest. 27: 575 (1972).
69. Hetrick, W. D., et al. Renal responses to light methoxyflurane anesthesia. Anesthesiology 38: 30 (1973).
70. Mazze, R. I., and Cousins, R. J. Renal toxicity of anesthetics: with specific references to the nephrotoxicity of methoxyflurane. Can. Anesth. Soc. J. 20: 64 (1973).
71. Cousins, M. J., et al. A comparison of the renal effect of isoflurane and methoxyflurane in Fischer-344 rats. Anesthesiology 38: 557 (1973).
72. Mazze, R. I., Cousins, M. J., and Kosek, J. C. Dose-related methoxyflurane nephrotoxicity in rats: a biochemical and pathological correlation. Anesthesiology 36: 571 (1972).
73. Mazze, R. I., Trudell, J. R., and Cousins, M. J. Methoxyflurane metabolism and renal dysfunction. Clinical correlation in man. Anesthesiology 35: 247 (1971).
74. Bruce, D. L., et al. Causes of death among anesthesiologists—a 20 year survey. Anesthesiology 29: 565 (1968).
75. Tobey, R. E., and Clubb, R. J. Renal function after methoxyflurane and halothane anesthesia. J. Amer. Med. Assoc. 223: 649 (1973).
76. Newberne, P. M., Bresnahan, M. R., and Kula, N. Effects of two synthetic antioxidants, vitamin E and ascorbic acid on the choline-deficient rat. J. Nutr. 97: 219 (1969).
77. Bell, L. T., and Hurley, L. S. Ultrastructural effects of manganese deficiency in liver, heart, kidney, and pancreas of mice. Lab. Invest. 29: 723 (1973).
78. Prieur, D. J., Davis, W. C., and Padgett, G. A. Defective function of renal lysosomes in mice with the Chediak-Higashi syndrome. Amer. J. Pathol. 67: 227 (1972).
79. Ericsson, J. L. Z., and Trump, B. F. Electron microscopy of the uriniferous tubules. In: The Kidney, Vol. I. Rouiller and A. F. Miller, Eds., Academic Press, New York, 1969, p. 351.
80. Burkholder, P. M., Hyman, L. R., and Barber, T. A. Extracellular clusters of spherical microparticles in glomeruli in human renal glomerular disease. Lab. Invest. 28: 415 (1973).
81. Chang, L. W., and Sprecher, J. A. Degeneration changes in the neonatal kidney following in utero exposure to methylmercury. Environ. Res. 11: 392 (1976).
82. Ware, R. A., Burkholder, P. M., and Chang, L. W. Ultrastructural changes in renal proximal tubules after chronic organic and inorganic mercury intoxication. Environ. Res. 10: 121 (1975).
83. Andersen, N. B., and Amaranath, L. Anesthetic effects on transport across cell membranes. Anesthesiology 39: 126 (1973).
84. Tyrrell, M. F., and Feldman, S. A. Headache following halothane anesthesia. Brit. J. Anesth. 40: 99 (1968).
85. Leucz, L., Nemes, C. S., and Berta, L. Psychische Belastungen and Morbidität der Anasthisten. Paper presented at 3rd European Anesthesiology Conference, Prague, 1970, Abstr. no. 63/02.
86. Porter, A. L. An analytical review of the effects of nonhydrogen bonding anesthetics on memory processings. Behav. Biol. 7: 291 (1972).
87. Adam, N. Effects of general anesthesia on memory function in man. J. Comp. Physiol. Psychol. 8: 294 (1973).
88. Pittinger, C. B., Conn, H. L., and Featherstone, R. M. Observations on the kinetics of transfer of xenon and chloroform between blood and brain of dog. Anesthesiology 17: 523 (1956).
89. Cohen, E. N., Chow, K. L., and Mathers, L. Autoradiographic distribution of volatile anesthetics within the brain. Anesthesiology 39: 377 (1973).
90. Smith, A. L., Larson, C. P., and Hoff, J. T. Effects of halothane on regional cerebral blood flow in experimental focal ischemia. Anesthesiology 39: 377 (1973).