Environmental Health Perspectives
Vol. 41, pp. 31-52, 1981

Neoplastic and Nonneoplastic Effects of Vinyl Chloride in Mouse Lung

by Yasunosuke Suzuki*

Neoplastic effects of vinyl chloride were studied in lungs of 27 mice exposed to vinyl chloride monomer at 2500 and 6000 ppm for 5 and 6 months (large doses and long-term exposure). Pulmonary tumors were observed in 26 of 27 experimental animals. Light microscopy showed the tumors to be multiple and arranged in either tubulo-papillary or adenomatous formations. Although occasional mitotic divisions and invaginations into the bronchiolar lumen were observed, no metastases were found. By electron microscopy, short microvilli, tight junctions between two adjacent cells, appearance of osmiophilic lamellar bodies, large mitochondria of irregular shape, well developed Golgi complexes, continuous or discontinuous basement membranes, occasional appearance of "sequestration" and of crystalloids and lack of both cilia and mucous secretory granules were observed as characteristic features of the neoplastic cells. Some of the cells were poorly differentiated and were equipped with poorly developed organoids, without formation of osmiophilic lamellar bodies. The pulmonary tumors corresponded to "alveologenic" tumors. It is suggested that the neoplastic cells were transformed from type II alveolar epithelium via its hyperplastic form.

Nonneoplastic effects of the chemical were also studied in the 27 mice. Major light microscopic alterations observed were proliferation and hypertrophy of the terminal bronchiolar cells, consisting of ciliated and Clara cells, hypersecretion of the epithelial mucin in the goblet cells of both the bronchial and the proximal bronchiolar epithelium, hyperplasia of alveolar epithelium, mobilization of alveolar macrophages and occasional presence of peribronchial or bronchiolar chronic inflammation. Electron microscopically, Clara cells of the terminal bronchiolar epithelium showed proliferation of the rough and smooth surfaced endoplasmic reticulum and appearance of large and abnormally shaped mitochondria. Similar alterations were found in the ciliated cells. Submicroscopic changes of pulmonary alveoli were represented by focal thickening of the basement membrane, multiple foci of hyperplastic type II cell (the precondition of the alveologenic tumor), active discharge of osmiophilic lamellar bodies from the type II cell and phagocytosis of the bodies by macrophages, appearance of cholesterol crystalloids in the macrophages, degeneration of alveolar septal cells and occasional appearance of a large nucleus with swelling of the capillary endothelium.

The neoplastic effect of vinyl chloride of smaller doses (100, 10, 1 and 0 [control] ppm) and shorter exposure (four weeks) was studied in lungs of 120 mice. Our preliminary observation indicated that sacrificed animals at 40 weeks after the exposure showed productions of the alveologenic tumor in 5 of 9 (100 ppm), 2 of 9 (10 ppm), 1 of 9 (1 ppm) and 0 of 10 (control = 0 ppm). A dose-response relation was considered in the incidence of the alveologenic tumor production of vinyl chloride. It is concluded that mouse lung is an extremely sensitive indicator of the oncogenicity of vinyl chloride.

Introduction

Hepatic hemangiosarcoma has been accepted as a serious health hazard associated with vinyl chloride exposure among workers in vinyl chloride polymerization plants (*1-7*). A risk of lung cancer has also been reported among the workers on the basis of epidemiological studies (*8,9*).

Experimental studies in rats, mice, and hamsters have shown that, in addition to liver, various organs such as lung, brain, breast and skin, including sebaceous glands, were involved in induction of primary neoplasia by vinyl chloride. Although a

*Environmental Sciences Laboratory, Department of Community Medicine and Department of Pathology, Mount Sinai School of Medicine of the City University of New York, One Gustave Levy Place, New York, N.Y. 10029.

number of studies have demonstrated that pulmonary tumors can be induced by vinyl chloride in mice, the significance of such occurrence and the nature of the tumors have not yet been appropriately explored (*10-17*).

The occurrence of the nonneoplastic pulmonary abnormalities among vinyl chloride polymerization workers has been reported on the basis of chest x-ray (*18*), pulmonary function (*19*) and smear cytology (*1*) of the worker's sputum. No histopathological evaluation of the abnormalities has been reported.

It is believed that a relationship between lung cancer and vinyl chloride exposure exists from epidemiological studies (*6,8,9,20*). A high incidence of pulmonary tumors in mice exposed to vinyl chloride has been reported by several investigators (*10-15*). However, the nonneoplastic pulmonary effects of the chemical have not been completely explored. We have, therefore, undertaken detailed light and electron microscopy of the mouse lung, to characterize the neoplastic and nonneoplastic pulmonary effects of vinyl chloride.

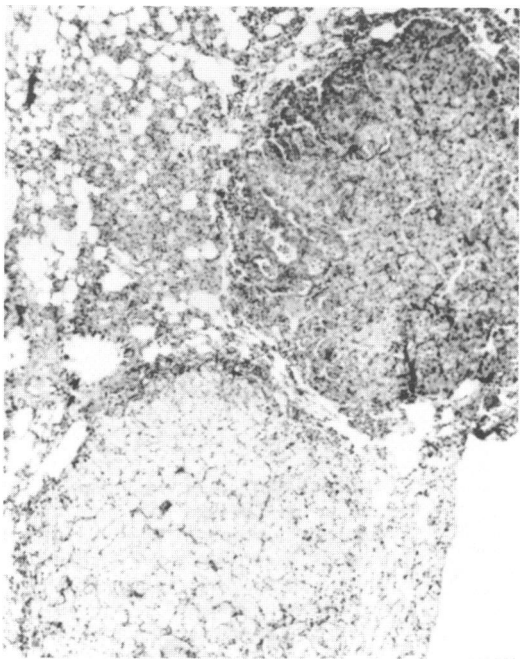

FIGURE 1. Two pulmonary tumors induced by vinyl chloride are seen in the peripheral part of a mouse lung (2500 ppm in group III). Hematoxylin and eosin; 64×.

Materials and Methods

Twenty-seven CDI Charles River white strain male mice, 4 to 5 weeks old at first exposure, were used. All of 27 mice used for this study were alive until they were sacrificed at three separate stages. The mice that died in the course of the experiment were excluded from the study. Group I consisted of six animals exposed to vinyl chloride at 2500 (three mice) and 6000 (three mice) ppm/hr, 5 hr/day, 5 days/week, for 5 months. They were then kept for 6 days without exposure before sacrifice. Group II included 13 mice exposed at 2500 (seven mice) and 6000 (six mice) ppm for 6 months and were kept for an additional 2 days for recovering before sacrifice. Group III included eight animals (seven at 2500 ppm and one at 6000 ppm) which were exposed to vinyl chloride monomer for 6 months followed by a 37-day recovery period. The inhalation exposures were accomplished at the Industrial Bio-Test Laboratory, Northbrook, Illinois. In addition to the experimental animals, 16 mice (four for group I, four for group II, three for group III, and five which were 12 months old) were used as controls.

To study the pulmonary effects of the chemical at smaller doses with shorter exposure, 120 mice of the same strain, sex and age were prepared. These animals were divided into four groups (30 mice in

Table 1. Pulmonary tumor production in CD1 male mice with lower doses of VC and shorter exposure (4 weeks).[a]

VC dose, ppm	1st sacrifice (immediately after dosing)	Between 1st and 2nd sacrifice	2nd sacrifice (12 weeks)	Between 2nd and 3rd sacrifice	3rd sacrifice (40 weeks)
100 (N = 30)	0/10[b]	0/4[c]	0/6[b]	0/1[c]	5/9[b]
10 (N = 30)	0/10[b]	0/1[c]	0/9[b]	0/1[c]	2/9[b]
1 (N = 30)	0/10[b]		0/10[b]	0/1[c]	1/9[b]
0 (N = 30)	0/10[b]	0/1[c]	0/9[b]		0/10[b]

[a]Reported as pulmonary tumor-bearing mice/total number of mice.
[b]Sacrificed.
[c]Found dead.

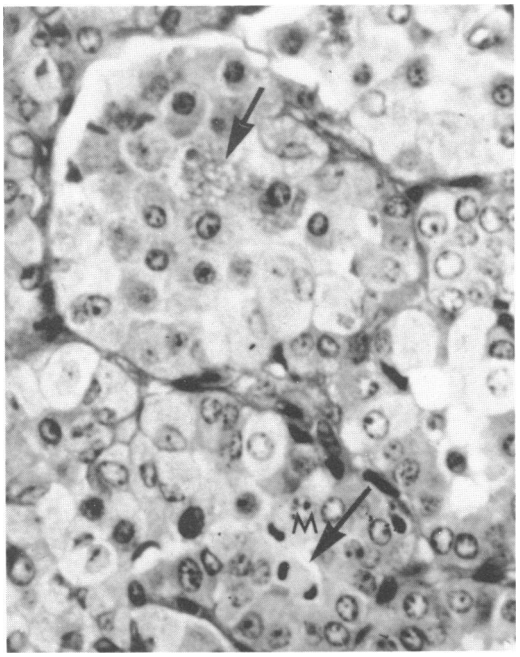

FIGURE 2. Neoplastic cells stained with PAS. An arrow indicates fine PAS-positive material digested by diastase. The arrow labeled M shows an abnormal mitosis (2500 ppm in group III). 560×.

each group) and were exposed to the chemical for 4 weeks (5 hr/day, and 5 days/week) at 100 ppm, 10 ppm, 1 ppm and 0 ppm (control). The low dose exposures were performed at the Toxicology Research Laboratory, Health and Environmental Sciences, Dow Chemical U.S.A. As shown on Table 1, these animals were sacrificed at three different periods: immediately after, 12 weeks after and 40 weeks after exposure to the chemical. Six (four 100 ppm, one 10 ppm, and one control) were found dead between the first and second periods, and three (one 100 ppm, one 10 ppm and one 1 ppm) were found dead between the second and third periods.

Lungs were examined under a dissecting microscope after the organs were removed from sacrificed animals, to determine whether macroscopic abnormalities including tumor production were present.

For light microscopy, the organs were fixed in 10% neutral buffered formalin and embedded in paraffin after dehydration in alcohol. Sections (5-6 μm) were made and stained with hematoxylin–eosin, Masson's trichrome, Weigert's silver, periodic acid-Schiff's (PAS) with and without digestion by diastase, elastin and Van Gieson's picrofuchsin technique. For electron microscopy small pieces, smaller than 1 mm^3, were taken from both pulmonary tumors and nonneoplastic pulmonary tissues and were fixed in 1% phosphate-buffered osmic acid at pH 7.2-7.4 for 2 hr or in 2% paraformaldehyde fixative followed by the osmic acid. After alcohol dehydration, the blocks were embedded in epoxy resin. Ultrathin sections were obtained with an LKB microtome. The sections were stained with uranyl acetate and lead. A Siemens 101 electron microscope was used for ultrastructural observations.

Observations

Neoplastic Effects of Vinyl Chloride at Heavy Doses and Long-Term Exposures

Gross Anatomical Findings. Pulmonary tumors were observed in all experimental mice except one from the 6000 ppm series of group II (26 of 27). None were found in 16 controls. These tumors were round, whitish in color, multiple in number and variable in size from 1 to 5 mm in diameter. No metastases to regional lymph nodes or other organs were observed. Neither parenchymal fibrosis nor fibrotic adhesions of the pleura were detected.

Light Microscopy. As shown in Figure 1, the tumors were usually seen in the peripheral part of

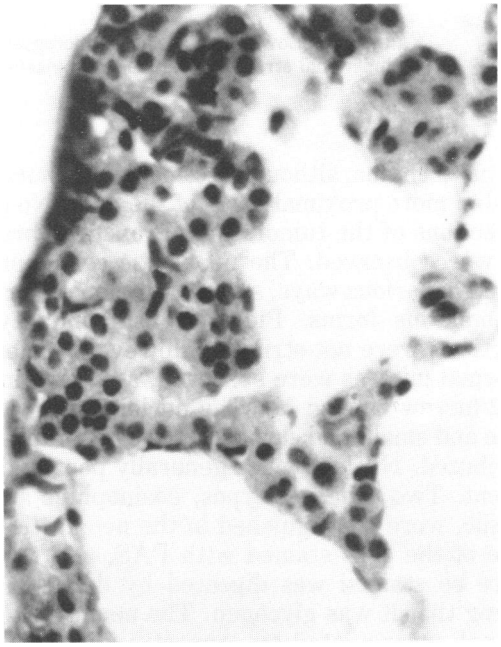

FIGURE 3. Hyperplastic pulmonary cells are seen beneath the visceral pleura of a mouse lung (2500 ppm in group III). Hematoxylin and eosin; 430×.

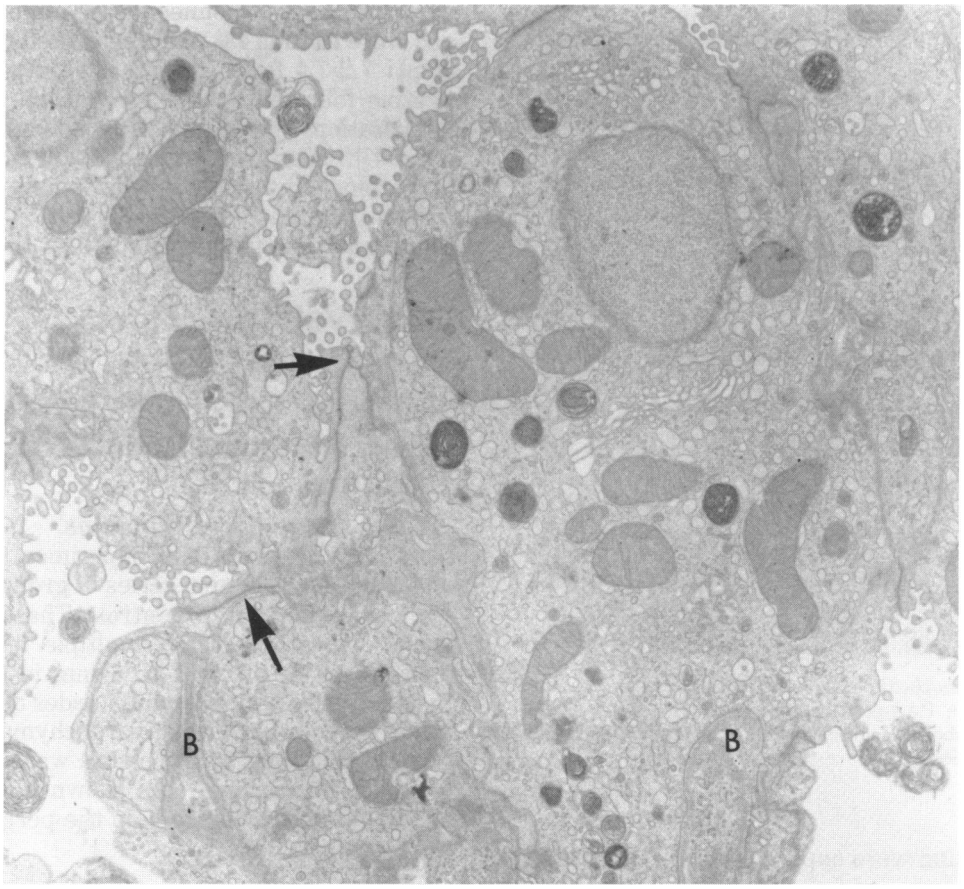

FIGURE 4. Low-power electron micrograph of a well-differentiated pulmonary tumor. Arrows indicate junctional structures between neoplastic cells. B, Basement membrane (2500 ppm in group III), OsO_4; 7900×.

lung parenchyma, although occasionally tumors were found in more proximal parts of the lung. No direct connections of the tumors with bronchi or bronchioles were observed. The neoplastic cells were arranged in various ways, such as tubulopapillary and adenomatous forms. Pleomorphism and atypical structures were not striking. However, sometimes abnormal mitoses were observed, as shown in Figure 2 (arrow labeled M). The nuclei were round in shape and small, and chromatin was generally finely distributed. Nucleoli were generally poor in development. Two different types, eosinophilic and basophilic, were distinguished in the neoplastic cells. Some of the cells stained with PAS, and the substance so stained was digested by diastase, suggesting that it was glycogen. The neoplastic tissue was not encapsulated by connective tissue. Often, air spaces separated neoplastic tissue from normal tissue. Although malignant invasion, such as destruction of preexisting tissue, was not observed in the animal lungs, invagination of the neoplastic tissue into bronchiolar air spaces was detected in instances of extremely large tumors. Collagen and reticular fibers showed little development in the neoplastic tissues. In addition to neoplastic changes, as shown in Figure 3, focal and multiple hyperplastic changes of the alveolar lining cells were noted in lungs exposed to vinyl chloride. In Figure 3, the hyperplastic cells are seen just beneath the visceral pleura. Since the lining cells beneath the thin connective tissue of the visceral pleura are known to be alveolar epithelium, the hyperplastic cells are assumed to be alveolar epithelial cells. Hyperplastic cells are also found in the deeper part of lung parenchyma. Occasionally, neoplasia and hyperplasia coexisted in the same lobe of the lung, and the distinction between neoplastic and hyperplastic cells with confidence was not always clear, as some cellular similarities were found between the two. Identification of the cell types of both

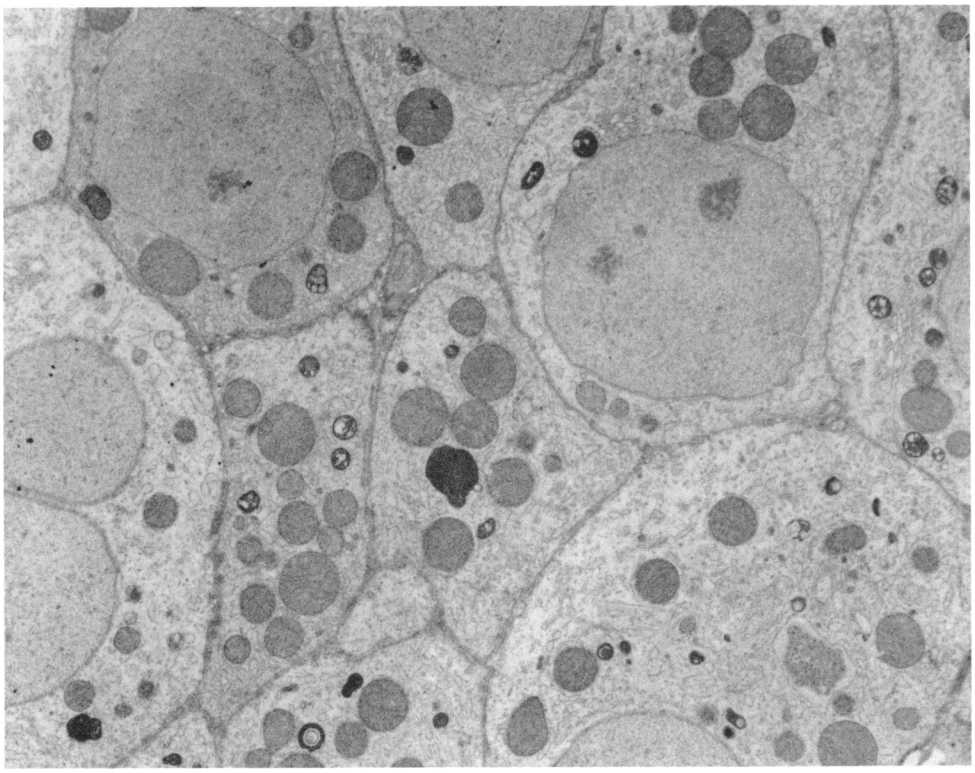

FIGURE 5. Differentiated neoplasm seen in the animal lung shown in Fig. 3. Formation of the tubular lumen and microvilli is poor. OsO_4; 6500×.

neoplastic and hyperplastic cells with confidence was not feasible at the level of light microscopy.

Electron Microscopy. Figure 4 is derived from neoplastic tissue of the tubulo-papillary form. Ultrastructural characteristics of the neoplastic cell included microvilli, large, round, or rod-shaped mitochondria, well-developed Golgi complexes, and osmiophilic lamellar bodies. Junctional structures (arrows in Fig. 4) between adjacent neoplastic cells and a basement membrane (B) were usually observed. Figure 5 was derived from an adenomatous area of the tumor. Neoplastic cells had poorly formed tubular lumens and microvilli and were smaller than those shown in Figure 4. However, other ultrastructural characteristics, such as mitochondria, Golgi complexes, and osmiophilic lamellar bodies, were almost identical in the two. Irregular arrangements of mitochondrial cristae were fairly common, and mitochondria were often wrapped by well-developed, smooth-surfaced endoplasmic reticulum (Fig. 6). Some of the neoplastic cells contained cytoplasmic compartments formed by membrane structures (Fig. 7). The occurrence of such compartments has been reported by Svoboda (*21*), who made electron microscopic observations on the neoplastic cells in mouse pulmonary tumors induced spontaneously or by urethane. Occasionally, crystalloid structures were observed in the cytoplasm of the neoplastic cells (Fig. 8). The above described neoplastic cells were quite similar in ultrastructure to type II alveolar epithelium. Capillaries in the neoplastic tissue consisted of single layers of nonfenestrated endothelium as seen in the normal alveolar capillary. In addition to well-differentiated neoplastic cells, poorly differentiated ones were also recognized (Fig. 9). As seen in Figure 9, the cells were cuboidal or cylindrical in shape and lacked formation of osmiophilic lamellar bodies. Mitochondria were small in size, although the cells were relatively rich in rough-surfaced endoplasmic reticulum. These cells seemed to correspond to the basophilic ones observed by light microscopy. Except for the lack of a large amount of glycogen, these cells resembled immature alveolar epithelium, as observed in fetal lung in late gestation. Neither cilia nor mucinous secretory granules were

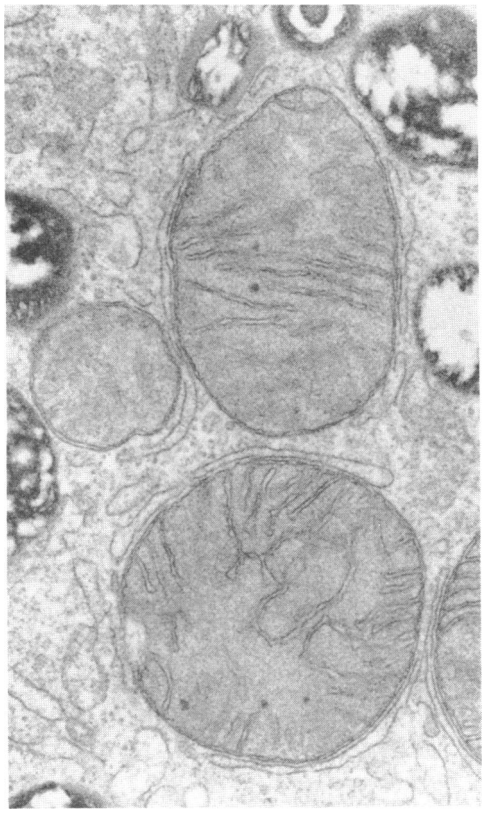

FIGURE 6. Part of the cell cytoplasm of a neoplastic cell. The arrow indicates irregular mitochrondrial cristae (2500 ppm in Group III). OsO_4; 29, 400×.

FIGURE 7. Intracytoplasmic compartments formed by membrane structures (2500 ppm in group III). OsO_4; 20, 000×.

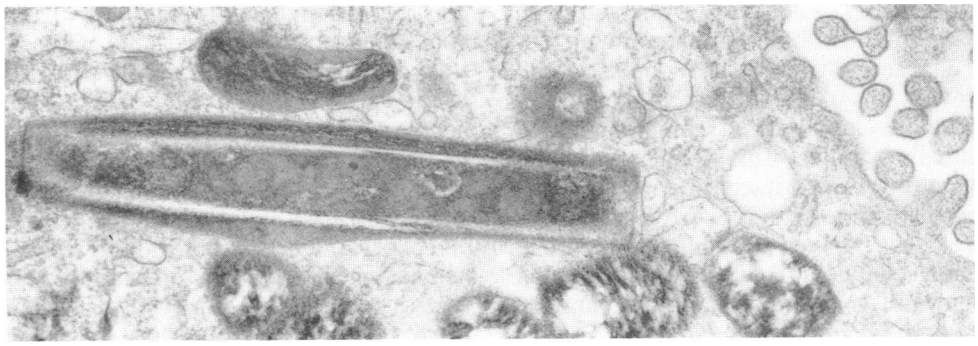

FIGURE 8. Crystalloid structure seen in the cytoplasm of a neoplastic cell (2500 ppm in group III). OsO_4; 30,000×.

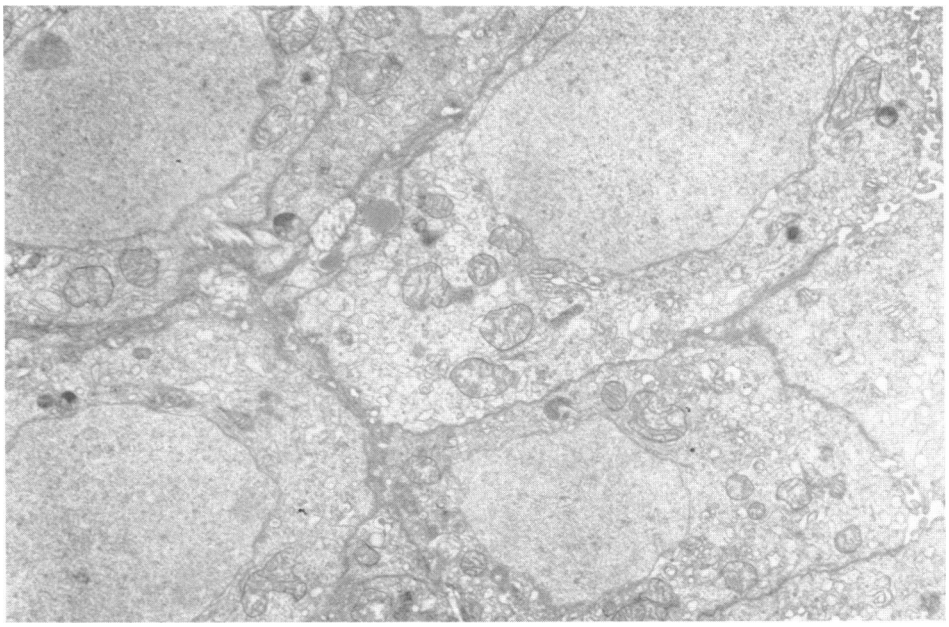

FIGURE 9. Poorly differentiated neoplastic cells. No osmiophilic lamellar bodies are observed (6000 ppm in group II). OsO_4; 6200 ×.

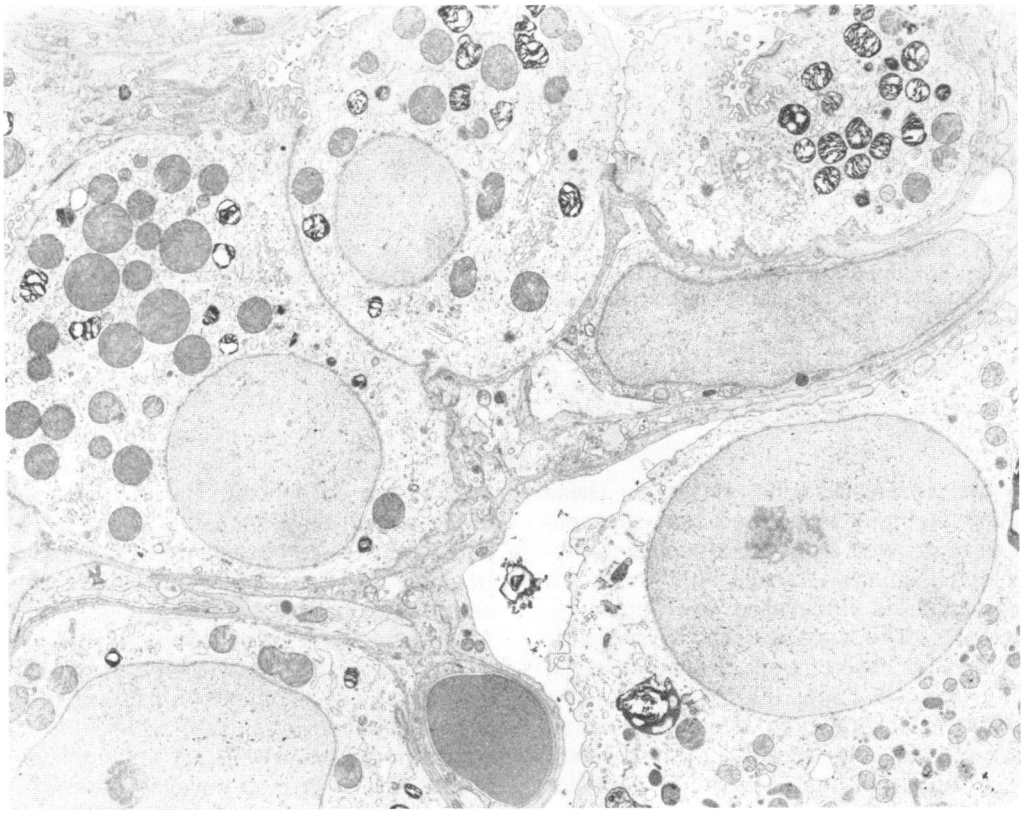

FIGURE 10. Hyperplastic type II cells are illustrated. Group 1; 6000 ppm; OsO_4; 5300 ×.

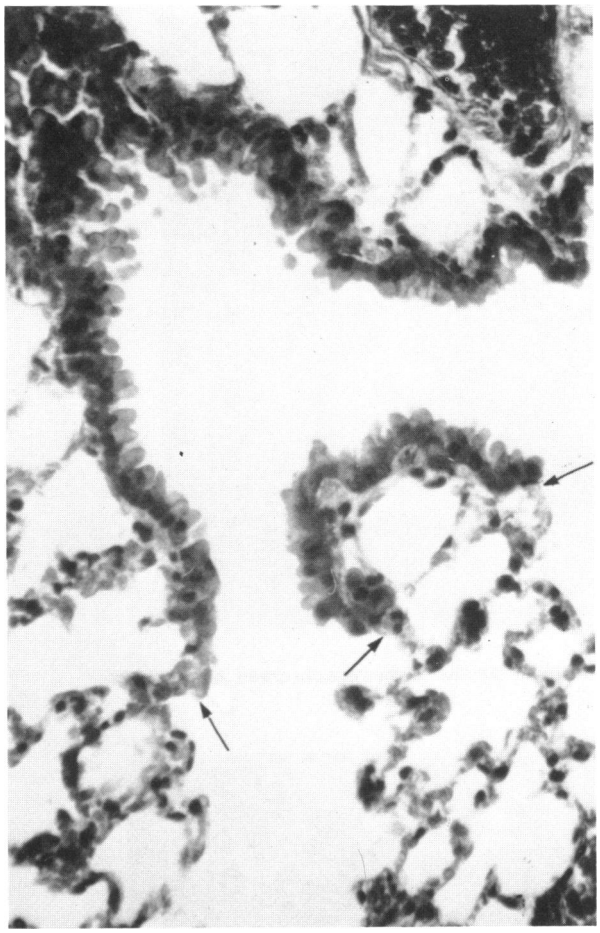

FIGURE 11. Light microscopy of a bronchiolo-alveolar area. Arrows indicate the site of transition between the respiratory bronchiole and the alveolus. Control mouse; Masson's trichrome staining; 420×.

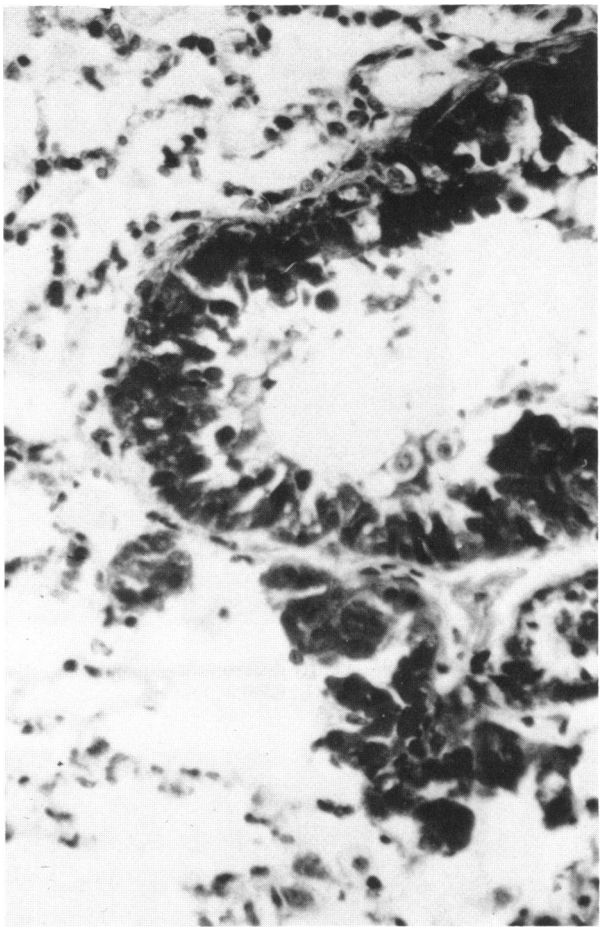

FIGURE 12. Proliferated and hypertrophic bronchioles. Desquamated bronchiolar epithelial areas are illustrated. Masson's trichrome staining; Group I; 2500 ppm, 420×.

observed in the neoplastic cells. Based on these findings, it was strongly suggested that the neoplastic cells were derived from the alveolar epithelium, particularly from type II cells. A hyperplastic pulmonary alveolus is illustrated in Figure 10. Electron microscopically, aspects of the hyperplastic cells were evidently those of type II alveolar cells, although they showed some differences in ultrastructure from the normal type II cell. Mitochondria were large in size and irregular in shape, and, occasionally, retention of huge osmiophilic lamellar bodies was noted in the cell cytoplasm. Cristae mitochrondriales were arranged irregularly, and well-developed endoplasmic reticulum was frequently seen in the cytoplasm. Early stages of the membrane formation responsible for "cytoplasmic compartments" were observed in the hyperplastic cell. In many respects, the hyperplastic type II cell is assumed to be the precursor of the neoplastic cell. An intermediate form between type I and II cells was frequently observed in the hyperplastic pulmonary alveoli. The arrow in Figure 10 indicates a part of the cell cytoplasm which may represent a transitional form between type I and II cells. Though the secretory granules were observed in the neoplastic cells, based on these findings, it was strongly suggested that the neoplastic cells were derived from the alveolar.

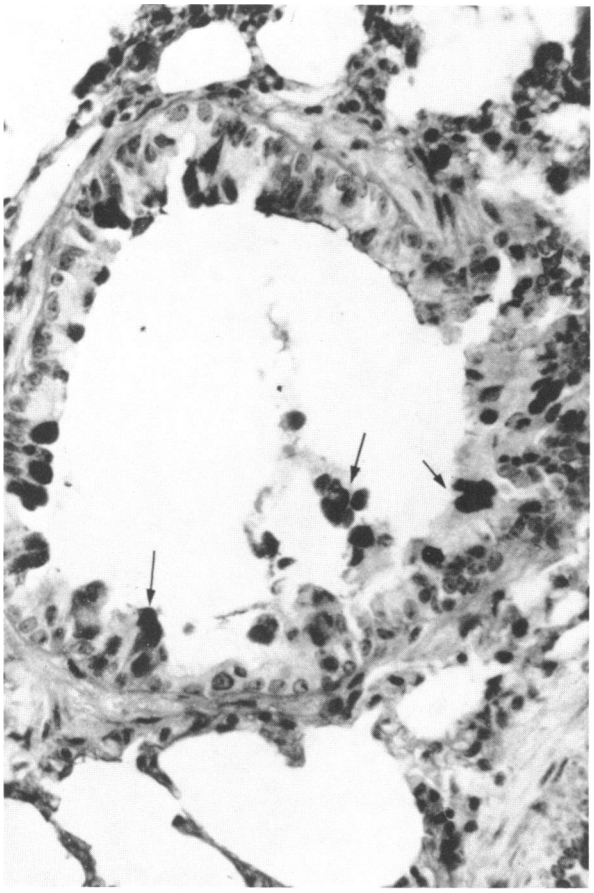

FIGURE 13. Hypersecretion of epithelial mucin in bronchial epithelium. Arrows indicate mucinous substance stained with PAS. Group III; 6000 ppm, 420×.

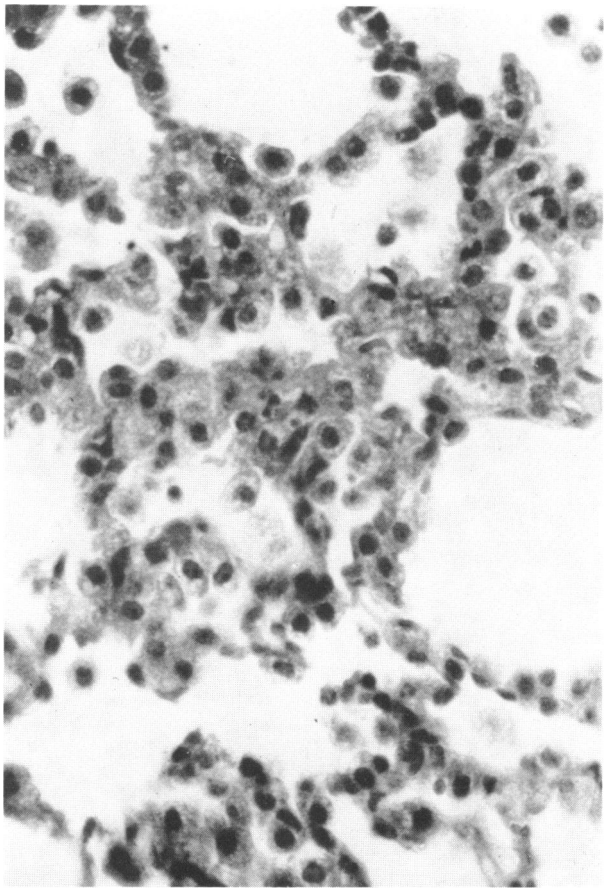

FIGURE 14. Hyperplasia of alveolar epithelium is shown. Hematoxylin-eosin: Group III: 2500 ppm; 670×.

Nonneoplastic Effects of Vinyl Chloride at Heavy Doses with Long-Term Exposure

Light Microscopy. In the bronchi and bronchioles, as a common finding in the treated animals, proliferation and hypertrophy of the bronchiolar epithelium were noted. As shown in Figure 11, the terminal and respiratory bronchioles of the control mice were relatively simple in structure and the transitional point (arrows) of the respiratory bronchiole into the alveolus was easily distinguished. To differentiate the two areas, we found that Masson's trichrome was a useful stain, since the cytoplasm of the bronchiolar cells was stained an intense brown red. The bronchioles of all the animals treated with vinyl chloride monomer showed proliferation, and cellular hypertrophy, through the degree varied among the animals (Fig. 12). The proliferated cells were irregular in arrangement (Fig. 12). Frequently, hypersecretion of epithelial mucin in goblet cells of the bronchi as well as the proximal bronchioles was observed (Fig. 13, arrows). It was noteworthy that those alterations were still found in the animals of group III, which had a recovery time of 37 days after vinyl chloride exposure. Chronic inflammatory changes represented by marked lymphocyte infiltration into the perivascular and peribronchiolar connective tissue were seen, particularly in group III.

The most significant finding in pulmonary alveoli was a high incidence of alveologenic tumors in the treated mice, as stated before. In addition to the neoplasm, multiple foci of hyperplastic alveolar epi-

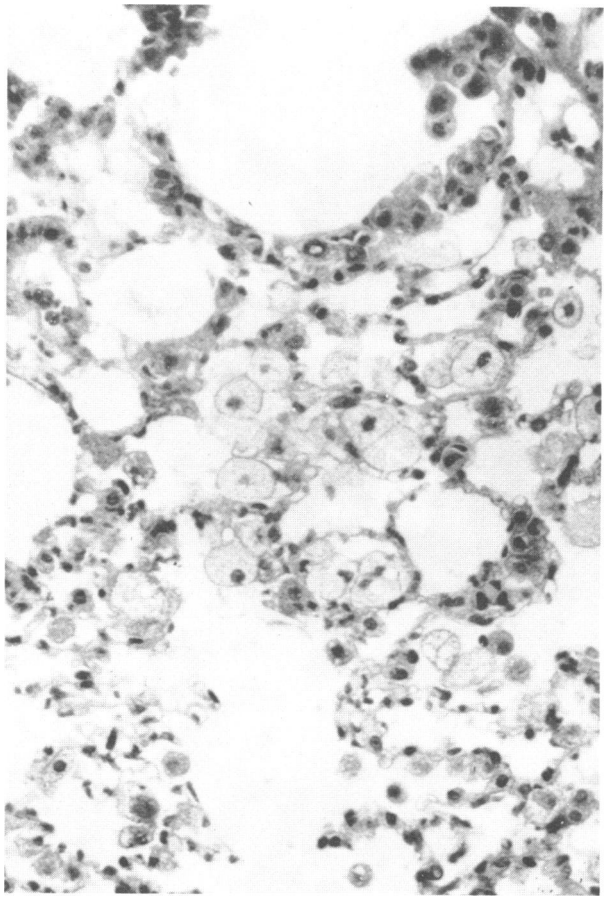

FIGURE 15. Large clear macrophages (foam cells) as well as small basophilic macrophages are seen in the alveolar air spaces. Hematoxylin-eosin; Group III: 2500 ppm; 420×.

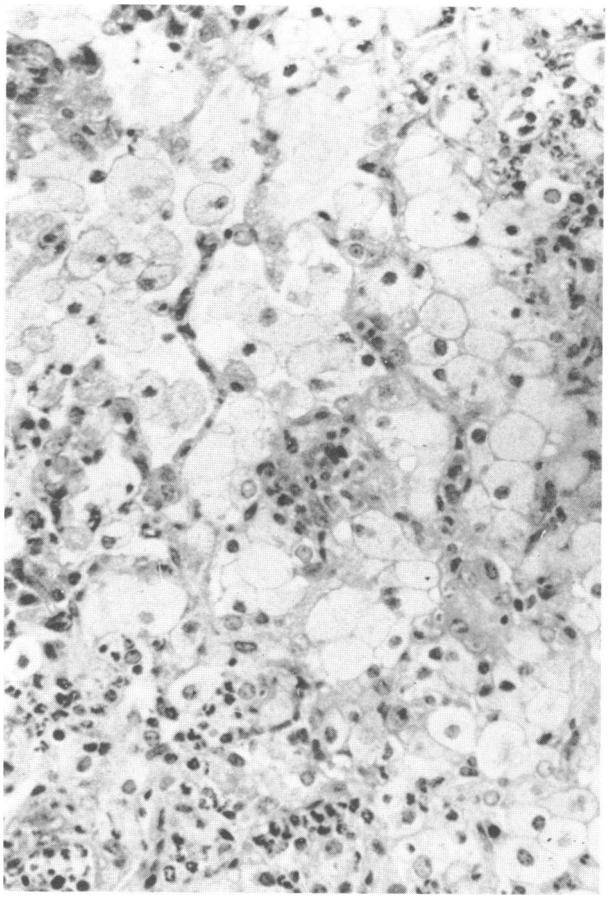

FIGURE 16. Striking accumulation of a large number of foam cells. Hematoxylin-eosin: Group III: 6000 ppm; 420×.

thelium (Fig. 14), which were strongly suggestive of being preneoplastic for alveologenic tumors (*22*), were frequently observed. Mobilization of alveolar macrophages in the alveolar space was fairly commonly seen in the three groups of animals (Fig. 15). In several cases, foam cells were markedly accumulated in alveolar space (Fig. 16). Two animals in group III showed bronchopneumonia-like changes. As shown in Figure 17, coexistence of the proliferated bronchioles with alveologenic tumors (arrow) was frequently observed.

Electron Microscopy. The epithelium of the terminal bronchiole consists of the Clara cell (nonciliated) and ciliated cells; it lacks mucous-producing cells in the mice. Both cell types are illustrated in Figure 18, obtained from a control mouse. Clara cells lack typical microvilli and their apical portion present a dome-like shape (Fig. 18). The smooth-surfaced endoplasmic reticulum and Golgi complex were well developed. Mitochondria were generally round in shape and their cristae were few in number (Fig. 18). Two distinct granules, a beadlike structure (electron-dense; the long axis was 1.6-0.2 μm) and a round phagolysosomal granule (electron-dense or opaque; 0.6 × 0.6 μm in size) were observed in the cells. It is noteworthy that the ultrastructure of the cell is not identical among animal species and, further different fixation methods result in different structural appearances of the endoplasmic reticulum in the cell.

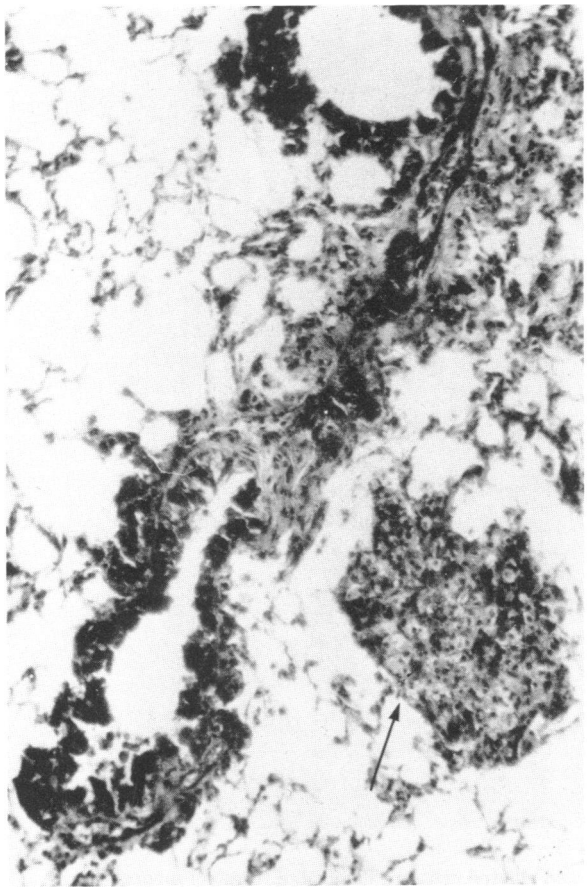

FIGURE 17. Part of lung tissue showing coexistence of the alveologenic tumor (arrow) with the proliferated bronchiole. Masson's trichrome staining; Group I: 6000 ppm; 170×.

The cytoplasm of the ciliated cell was relatively clear and it contained rod-shaped mitochondria with cristae (Fig. 18). Cilia and microvilli were seen in the cell surface (Fig. 18). The two distinct granules were also occasionally seen in the cell. Ultrastructural changes seen in those cell types of the treated mice are described below.

A low-power view of the proliferated bronchiole is illustrated in Figure 19. Hypertrophic Clara cells frequently included dark cells rich in rough-surfaced endoplasmic reticulum and free ribosomes. The cell was usually large and its shape was occasionally irregular. Deep interdigitation of the lateral cell membranes of two adjacent cells was occasionally observed. Golgi complexes were well developed, and the two distinct granules described above were increased in number in the cytoplasm. The dark round granules are shown in Figure 19. Although smooth-surfaced endoplasmic reticulum of the normal Clara cell was generally vesicular (with a single osmic acid fixation as used in this study, though this cell organoid is cisternal with double fixation by glutaraldehyde and osmic acid), the hypertrophic cells contained various forms of the organoid and the transformation of the rough surfaced endoplasmic reticulum into smooth-surfaced endoplasmic reticulum was easily observed (Fig. 20). Mitochondria of abnormal shapes and large size occasionally appeared. Cristae were rather clearly shown in such abnormal mitichondria (Fig. 21).

Ciliated cells were also involved in the proliferated alteration. The shape of the cells was occasionally irregular. Golgi complexes were sometimes well developed and phagolysosomal granules as well as round dense granules frequently appeared in the cytoplasm (Fig. 22). Large round mitochondria in which cristae were fewer in number were seen. In some ciliated cells, the rough and smooth surfaced endoplasmic reticulum were markedly developed (Fig. 22).

Although light microscopic observations failed to detect details of damages in the pulmonary alveolus, various ultrastructural alterations of the alveolar cells were revealed by electron microscopy.

Mobilized alveolar macrophages were rich in phagolysosomal granules, as shown in Figure 23. Other cell organelles were also well developed. Basophilic macrophages contained a large number of free ribosomes as well as the rough-surfaced endoplasmic reticulum, while clear macrophages were represented by intracytoplasmic osmiophilic lamellar bodies (Fig. 23) which seemed to be phagocytosed from the alveolar space. Occasionally, cholesterol crystalloids were found in the macrophages (Fig. 24, arrows).

As shown in Figure 10, hyperplastic alveolar epithelium consisted of type II cells, precursors of alveolar tumor (*15*). The evolutional process of the neoplastic transformation has been reported (*15*). Deformation of the cell shape, appearance of giant mitochondria with abnormal cristae, retention of large osmiophilic lamellar bodies, early introcytoplasmic "sequestration," and occasional huge lipid granules were observed. Microvilli of the cell surface were frequently decreased in number. These alterations were observed in almost all mice exposed to vinyl chloride, regardless of difference in dose and duration of recovery time.

Swelling of the cytoplasm and appearance of lysosomal granules were occasionally observed in type I cells. Transformation of the type I cells into the

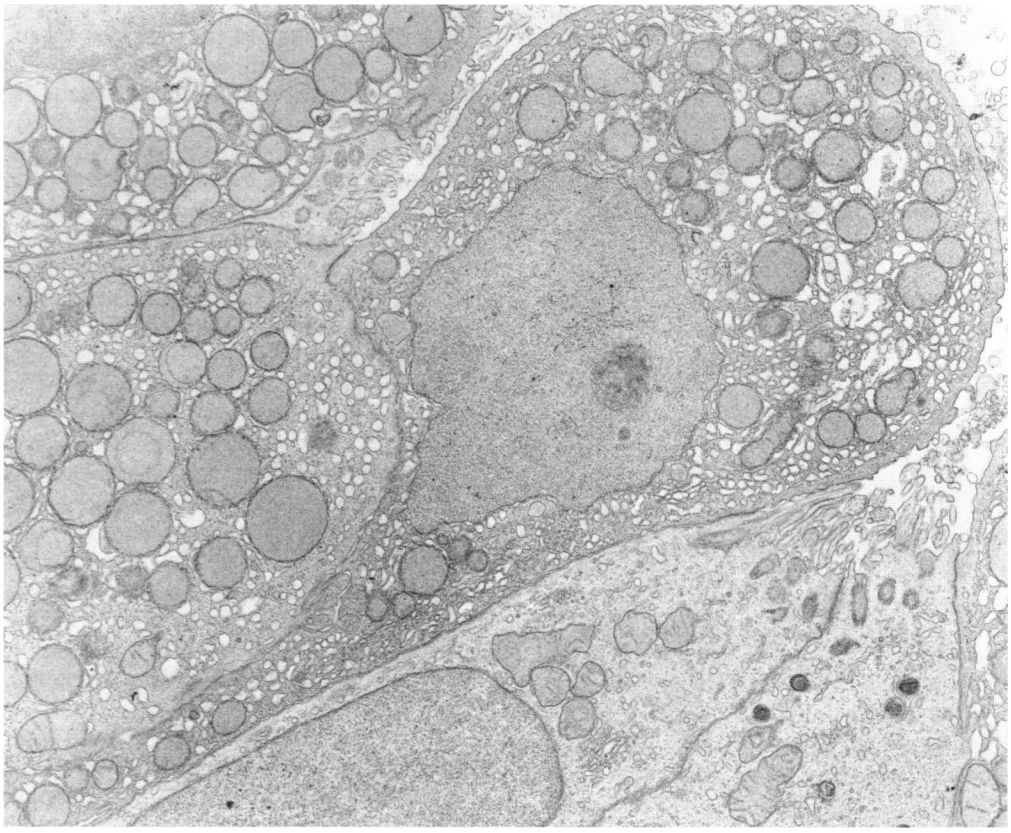

FIGURE 18. Part of the terminal bronchiole. Clara cells and ciliated cells are illustrated. Control mouse; OsO_4; 6700×.

type II cells was suggested, since intermediate cell types between the two were found on the alveolar lining.

Focal thickening of the basement membrane was commonly seen (Fig. 25). Sometimes, the thickened basement membrane showed a fibrillar appearance ("f" in Fig. 26) and contained cell debris (arrows in Fig. 26) which seemed to be derived from alveolar septal cells.

In addition to swelling of the cytoplasm, lysosomal granules and a large nucleus (Fig. 27), segmented or nonsegmented, were sometimes observed in the alveolar endothelium.

Alveolar septal cells frequently showed hypertrophy (h in Fig. 28) and degeneration (arrows in Fig. 28). In some cases, focal reticulosis was observed in the alveolar septum.

From these light and electron microscopic studies, mouse lungs exposed to vinyl chloride at 2500 and 6000 ppm for 5 and 6 months clearly showed nonneoplastic pulmonary changes in both bronchiolar and alveolar cells. Since these findings were not detected in control mice, they are considered related to vinyl chloride.

Neoplastic Effects of Vinyl Chloride at Smaller Doses with a Shorter Exposure

Detailed studies on pulmonary effects of vinyl chloride at smaller doses (1, 10 and 100 ppm) with a shorter exposure (4 weeks, 5 hr/day, 5 days/ week) are still in a process of analyses in 90 mice. However, as shown in Table 1, our preliminary study that involved gross anatomical and histological observations revealed that alveologenic tumors were induced in 5 of 9 (100 ppm), 2 of 9 (10 ppm) and 1 of 9 (1 ppm), while the tumor was not seen in 10 controls

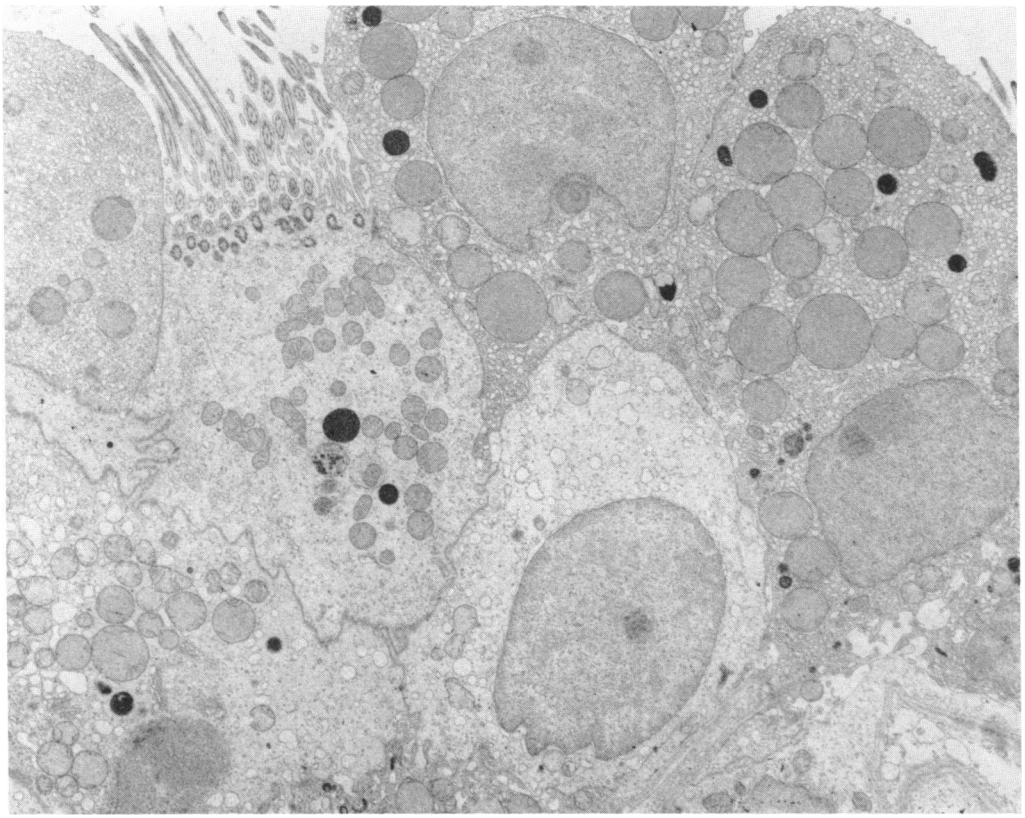

FIGURE 19. Proliferated bronchiolar epithelium. Group I: 6000 ppm; 3300×.

(0 ppm) at 40 weeks after vinyl chloride exposure. Size and number of the induced tumors were generally smaller than those of the tumors produced by the chemical of larger doses (2500 ppm and 6,000 ppm) and longer exposure (5 and 6 months).

A dose response relation was suggested in production of alveologenic tumor.

Discussion

Experimental studies (*10-17*) on the oncogenicity of vinyl chloride have revealed that the monomer can induce various neoplasms including hepatic hemangiosarcoma (rat, mice, hamsters), Zymbal gland carcinoma in the external auditory meatus (rats), breast cancer (mice), nephroblastoma (rats), "lung adenoma" (mice), skin trichoepithelioma (hamsters), lymphoma (hamsters) and forestomach papilloma (hamsters). Evidence of the pulmonary oncogenicity of vinyl chloride in animals has been obtained. Viola et al. (*16, 17*) have reported that rats exposed to vinyl chloride exhibited lung cancer (32%). Histological features of the cancers were stated to be those of adenocarcinoma, with the exception of a single epidermoid tumor. Maltoni and Lefemine (*13,14*), however, reviewed the histological slides of Viola et al. and stated that the lung cancers reported by the latter were not primary tumors of the lungs, but metastatic cancers from Zymbal glands. Maltoni and Lefemine (*13,14*) also have reported on the pulmonary oncogenicity of vinyl chloride on the basis of their own data. Though they could not find bronchogenic carcinoma in rats, rare pulmonary hemangiosarcomas and fibrosarcomas were induced in these animals. Unlike the case in rats, pulmonary tumors ("adenomas") were found in mice (89 of 471). Maltoni and Lefemine (*13,14*) noted that some of the adenomas underwent malignant transformation. Keplinger and associates (*11*) have found "alveologenic adenomas" in the lungs of mice exposed to vinyl chloride (44 of 49). Lee and associates (*12*) have stated that "bronchiolar ade-

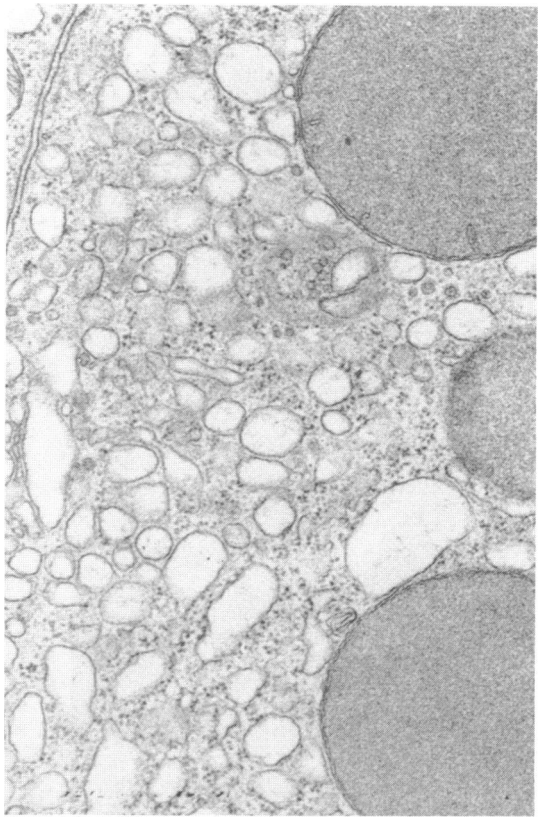

FIGURE 20. Part of the cytoplasm of a Clara cell. Various profiles of the endoplasmic reticulum are seen. Group I: 2500 ppm; 21,000 ×.

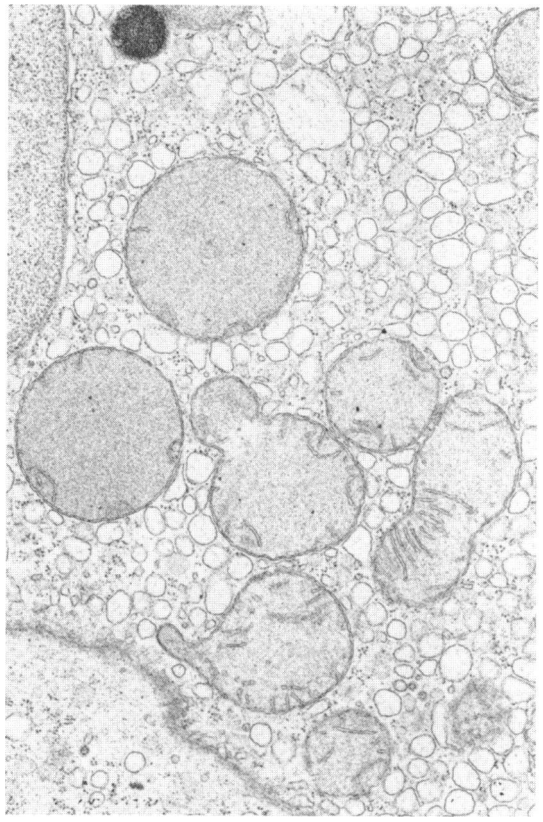

FIGURE 21. Irregular shaped mitochondria with cristae in the cytoplasm of a Clara cell. Group I: 6000 ppm; OsO_4; 12,600 ×.

noma" developed in mice 2 months after exposure to vinyl chloride at 50-1000 ppm. Holmberg and associates (*10*) found "alveologenic adenoma" in 13 of 24 mice exposed to vinyl chloride at 50 ppm for 24-52 weeks. Our present study has also confirmed that pulmonary tumors are induced by vinyl chloride of both the large doses (2,500 and 6,000 ppm) with long exposure (5 and 6 months) and the smaller doses (1, 10 and 100 ppm) with a short exposure (4 weeks).

Based on all the data available, it can be concluded that mouse lung is an extremely sensitive organ for demonstrating the oncogenicity of vinyl chloride. Gross anatomical and histological aspects of the tumors in our investigation corresponded to the "alveologenic tumor or cancer" of Steward et al. (*22-24*). The alveologenic tumor has been induced by various carcinogens (*22-28*), such as polycyclic hydrocarbons, urethane, nitrogen mustard, methylcholanthrene, and nitrofur derivatives and is known to occur spontaneously with aging (*6,29,30*). The cancer induced has been distinguished from that occurring spontaneously by multiple primary foci, occasional formation of huge tumors, and occurrence without any relation to aging. It is also known that in certain strains, such as A and DD, spontaneous tumors are quite common after 10 to 12 months of age. Spontaneous pulmonary tumors could be excluded in our experimental animals; in addition to the above-mentioned points, neoplastic changes in the lungs were absent in the controls.

Electron microscopically, alveolar epithelium, particularly the type II cell, was assumed to be the precursor of vinyl chloride-induced tumor in the mouse lung. This assumption was derived from ultrastructural similarities between the normal type II cell and the neoplastic cell. Similar suggestions have been made by other investigators (*21, 28, 31*) after studying pulmonary tumors induced by agents other than vinyl chloride.

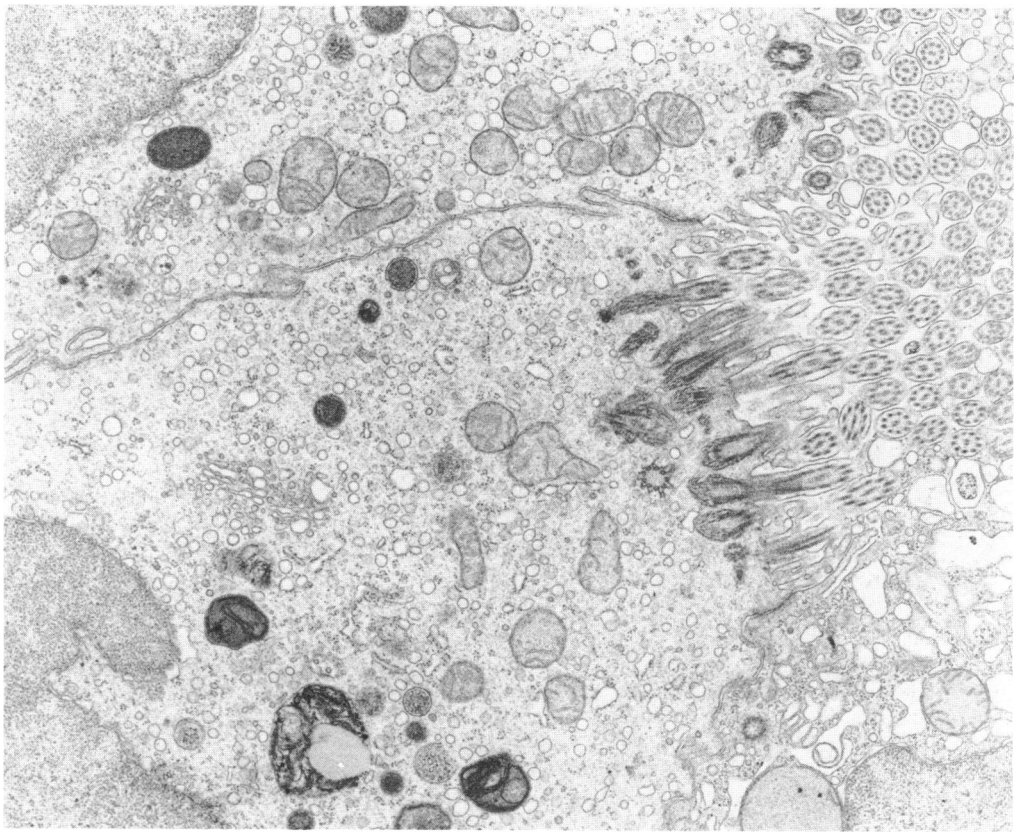

FIGURE 22. Two ciliated cells of a terminal bronchiole. Irregular shaped mitochondria, a well developed Golgi area, round dense granules and phagolysomes are shown. Group I: 6000 ppm; OsO_4; 9800×.

It was noteworthy that the processes of transformation of the normal alveolar epithelium into the neoplastic cell could be followed morphologically on the level of ultrastructure; the appearance of an intermediate form between type I and II cells in the alveolar lining, the disappearance of type II cell in the lining due to replacement by the hyperplastic type II cells, which were transformed from the intermediate form, and the neoplastic change of the type II cells were assumed to be a sequence of the process. The intermediate form appears in certain pathological conditions, prior to cuboidal metaplasia of the attenuated alveolar epithelium (*15*, *32*). Embryologically, both type I and II cells are of the same origin, the entodermal epithelum. Some of the neoplastic cells, distinguished as poorly differentiated, were similar in ultrastructure to the immature alveolar epithelium of fetal lung (*15*). From these perspectives, the process of neoplastic alteration observed in the epithelium may be interpreted as a retrograde process of the normal differentiations of the alveolar epithelium. Kaufman et al. (*33*) have reported that Clara cells of the mouse bronchioles developed into neoplasms which could occur in a malignant form, after transplacental exposure to ethylnitrosurea. However, such a Clara cell tumor was not produced in our material.

Waxweiler and associates reported an increased number of deaths due to lung cancer among vinyl chloride workers (*9*). They observed 12 cases compared to the 7.7 cases expected. Eight of the twelve were examined histologically and were classified as undifferentiated large-cell carcinoma (five cases) and adenocarcinoma (three cases). Since these human lung cancers are of bronchogenic origin, it may be that target pulmonary cells in vinyl chloride carcinogenesis are different in human and mouse lung.

Neoplastic invasion and metastases were not found in our material. However, it is known that sometimes both induced and spontaneous alveologenic

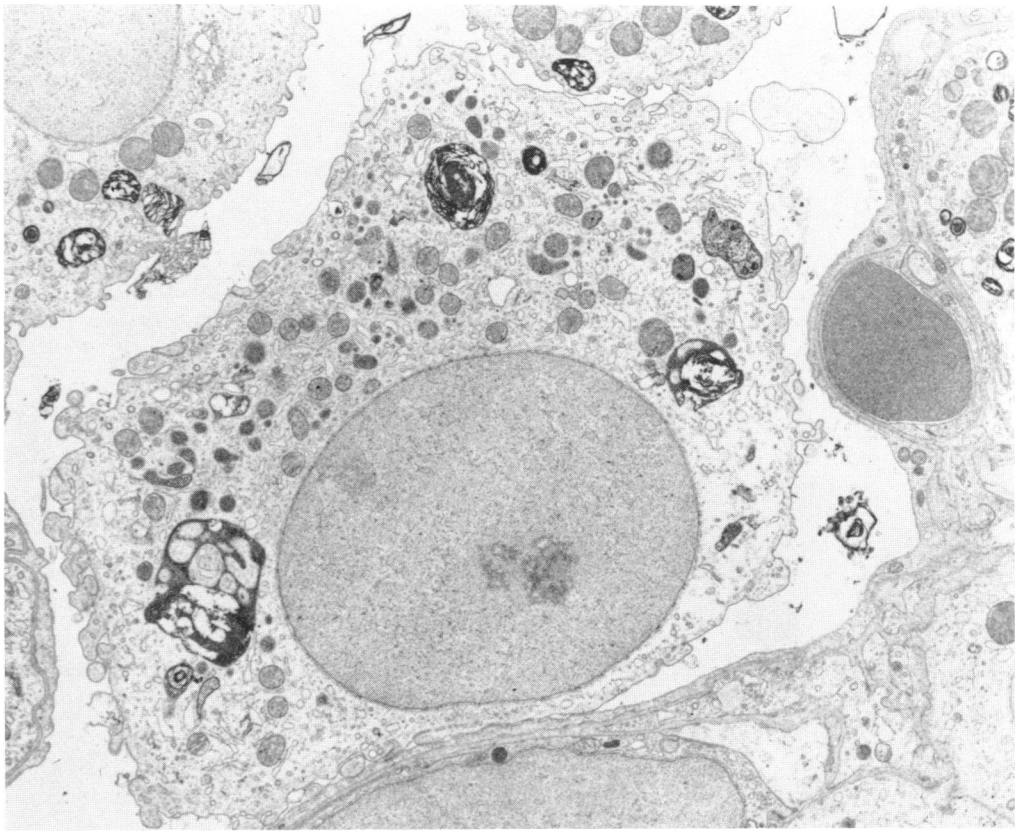

FIGURE 23. Alveolar macrophage including phagolysosomes and osmiophilic lamellar bodies. Group I: 2500 ppm; OsO_4; 5800×.

tumors (*22*, *34-37*) of mice show such changes and that the malignant transformation occurs with some delay after initiation of the tumor. In addition, transplantation of this tumor has been accomplished (*23*). Steward and associates (*22-24*) therefore dubbed it an "alveologenic tumor" or "alveologenic cancer." Maltoni and Lafemine (*13,14*) have found that some vinyl chloride-induced pulmonary tumors undergo transformation, although we did not observe this in our materials.

Alveologenic tumors may be considered unique in some ways, since it is possible to observe the process of malignant transformation sequentially from the precursor to the malignant cell via hyperplastic and benign neoplastic states.

Hepatic hemangiosarcoma is recognized as a characteristic malignant tumor related to vinyl chloride exposure. The tumor can be induced in a variety of experimental animals (mice, rats, and hamsters) (*13,14*), and histological features of the tumor are almost identical in humans and animals. In contrast, the intrapulmonary target cells of vinyl chloride oncogenesis may be different in humans and mice. Beyond these differences, moreover, the induction of alveologenic tumors in mice by vinyl chloride may be predictive or a risk of human bronchogenic cancer from the chemical. Consistent with this is the fact that various carcinogens, such as polycyclic aromatic hydrocarbons, nitrogen mustard and chromate compounds, are known to induce alveologenic tumors in mice, on one hand, and, on the other, to be associated with excess bronchogenic carcinoma among workers exposed to the carcinogens (*38*). It is noteworthy that a similar relation has been suggested for vinyl chloride.

Nonneoplastic pulmonary effects of vinyl chloride

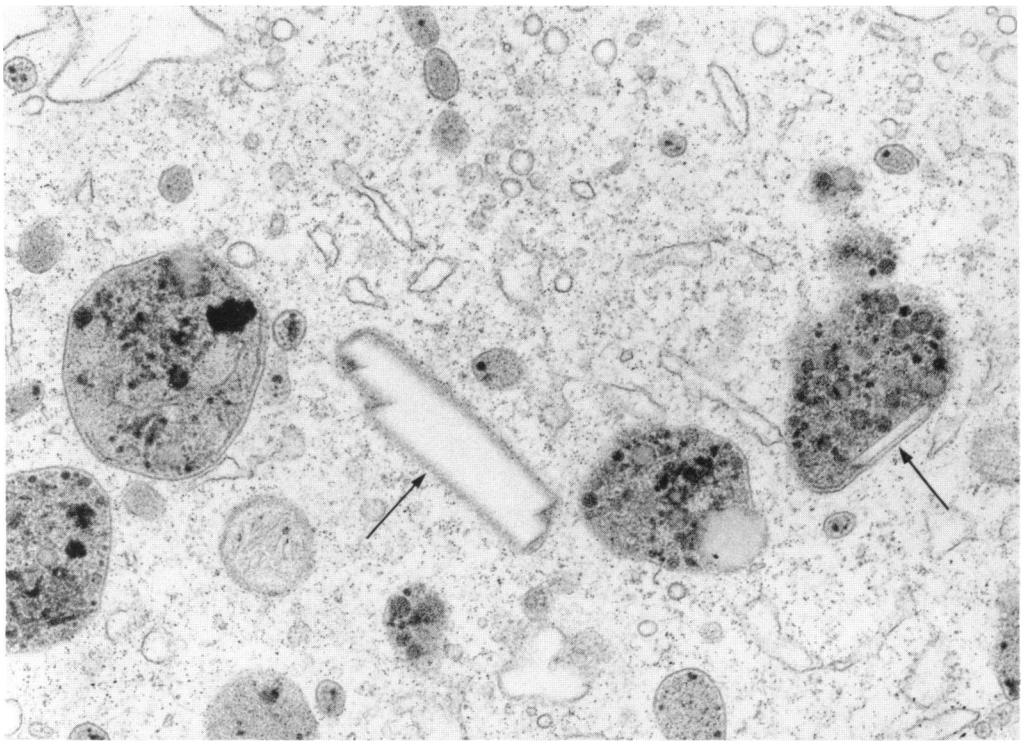

FIGURE 24. Part of a macrophage. Two cholesterol crystalloids are shown. Group III: 2500 ppm; OsO_4; 27,000×.

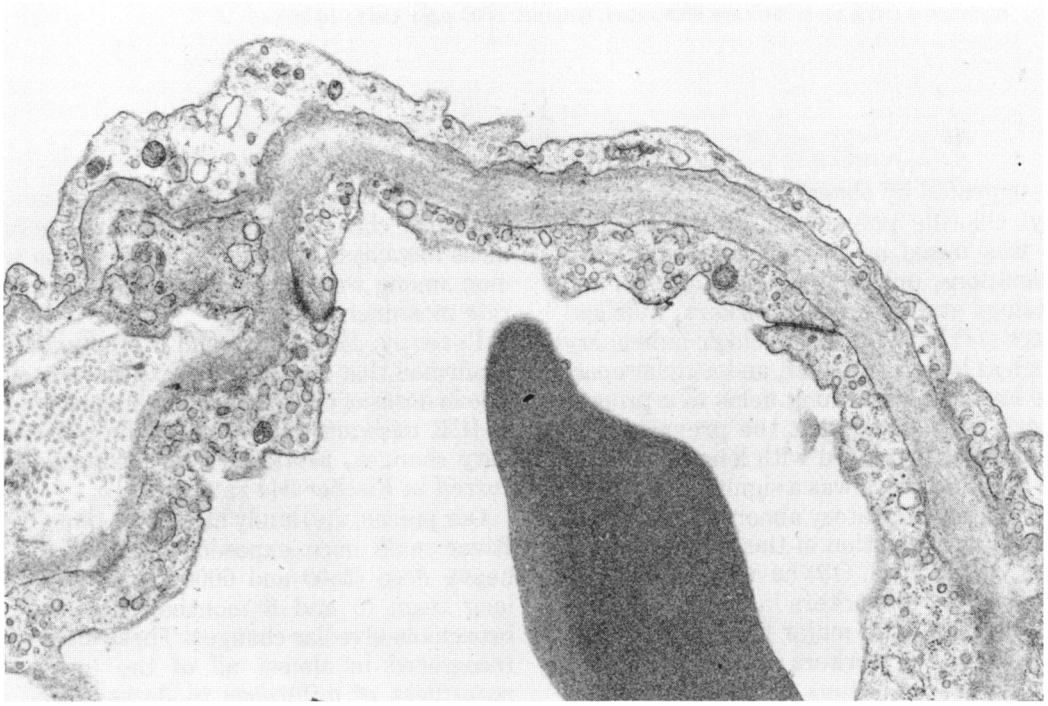

FIGURE 25. Thickened basement membrane of an alveolar capillary. Group I: 6000 ppm; OsO_4; 15,000×.

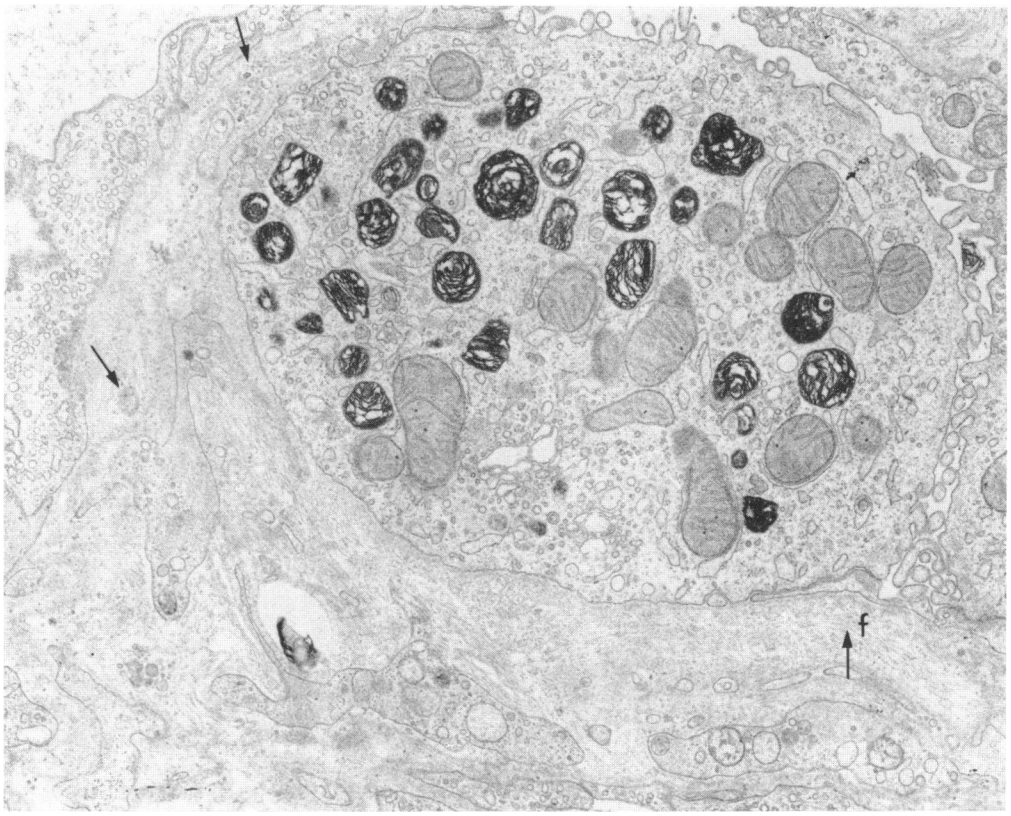

FIGURE 26. Cell debris of degenerated alveolar septal cells (arrows) and fibrillar appearance of a basement membrane (with an arrow) are illustrated. Group I: 6000 ppm; OsO_4; 10,300×.

have been suggested by observations among workers in vinyl chloride polymerization plants. This suggestion was based on data obtained by chest x-ray examinations, pulmonary function tests, and sputum cytology studies among workers. Lilis and her associates (*18*) have found radiologic pulmonary changes, such as linear, reticular, and nodular opacities, in the lower and mid lung fields in a proportion of cases. They found that the prevalence of pulmonary changes increased with longer duration of exposure and that there was a significant association with peripheral circulatory abnormalities. However, pathological evaluation of these changes was not available. Miller et al. (*19*) have examined pulmonary function of 348 workers in a vinyl chloride polymerization plant. The major finding was diminution of air flow in 200 workers (57.7%). Again, no physicopathological relations were established. Maltoni and Lefemine (*14*) reported cytological studies of sputum in vinyl chloride and poly(vinyl chloride) workers. They found a significant increase in cellular changes of the bronchial epithelium; squamous metaplasia and squamous dysplasia were common among workers heavily exposed to vinyl chloride monomer.

Recently, McNamara and McLaughlin (*39*) have confirmed that a single 1-hr exposure to vinyl chloride in doses of 500 ppm or more induced pneumonitis in ICR mice and that aggravation of latent pulmonary changes, particularly bronchopneumonia, occurred in Fischer 344 rats.

Our present (*40*) study has shown that CD1 Charles River male mice exposed to vinyl chloride at a heavy dose (2500 and 6000 ppm), over relatively long term (5 and 6 months), obviously showed bronchiolo-alveolar changes. These alterations were recognized in almost all of the treated animals regardless of difference in doses (2500 and 6000 ppm), duration of exposure (5 and 6 months) and recovery time (2, 6 and 37 days).

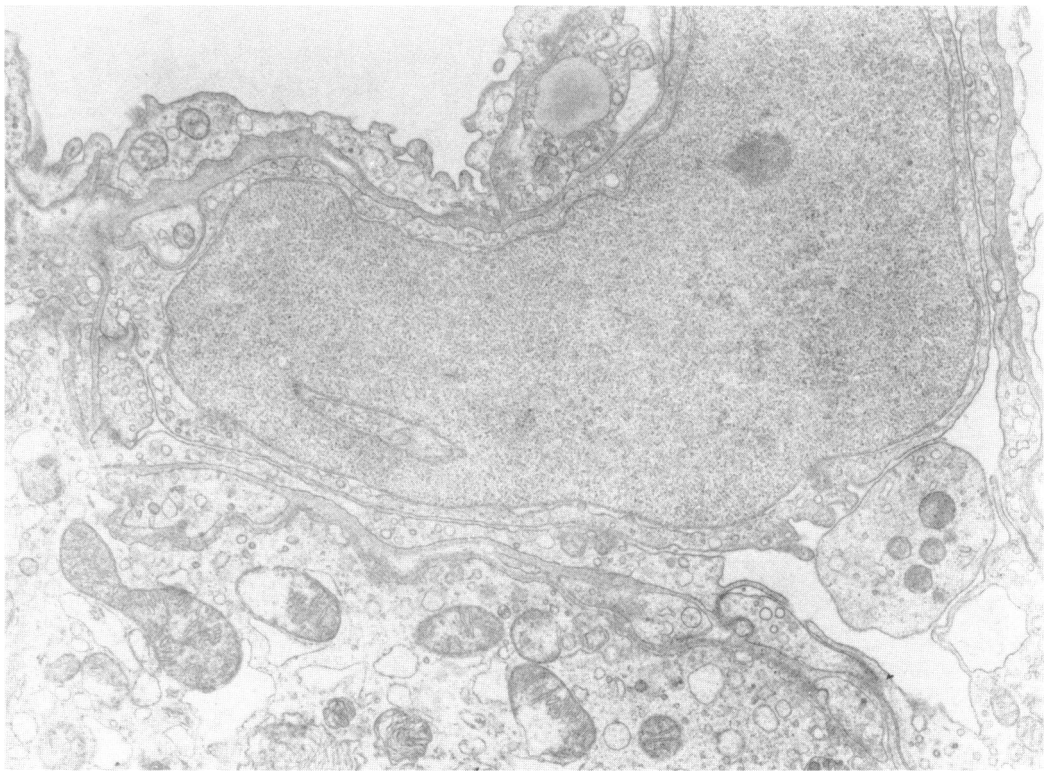

FIGURE 27. Large nucleus in the alveolar capillary endothelium. Group II: 2500 ppm; OsO_4; 7900×.

The types of pulmonary cells which were involved in the structural alterations varied. It was interesting that the ultrastructural changes seen in Clara cells and to some extent in the ciliated cells were similar to those of hepatic cells of animals exposed to vinyl chloride; cellular hypertrophy and proliferation of the endoplasmic reticulum were common responses, seen in both the bronchiolar epithelium and the hepatic cells. The endoplasmic reticulum of the hepatic cells has been suggested as the site where vinyl chloride is metabolized, to be transformed into a chemically reactive metabolite which is the ultimate carcinogen (*36*, *41-45*). Although it has not been shown that lung has the capacity to metabolize the chemical to produce the carcinogen; if it were so, the bronchiolar cells, particularly Clara cells, may provide this mechanism: the cells are normally equipped with well-developed smooth-surfaced endoplasmic reticula and the organelles have shown a proliferative response after mice are exposed to vinyl chloride.

The fact (*46*) that vinyl chloride has a tendency to be soluble in lipid substances suggests that lipid-rich pulmonary cells, such as type II cells (rich in osmiophilic lamellar bodies) and alveolar septal cells (containing lipid granules) may bind to vinyl chloride. If this assumption is correct, at least some of ultrastructural alterations seen in those cells might result from this mechanism. Both type II cells and Clara cells have been known as surfactant factor-producing cells (*47*). Hyperproduction of the surfactant factor was suggested, since hyperplasia of those cells was commonly seen in our material. Osmiophilic lamellar bodies and cholesterol crystalloids, which were seen in alveolar macrophages, may represent lipid substances bound to vinyl chloride. They may be removed from lung as part of the clearance mechanism for vinyl chloride. It is well accepted that mesenchymal elements such as bone, connective tissue, and blood vessels are involved in responses to vinyl chloride in various organs (*36*, *48-50*). Above all, malignant transformation of the blood capillary endothelium, induction of hemangioendothelioma in liver, and the subcutaneous con-

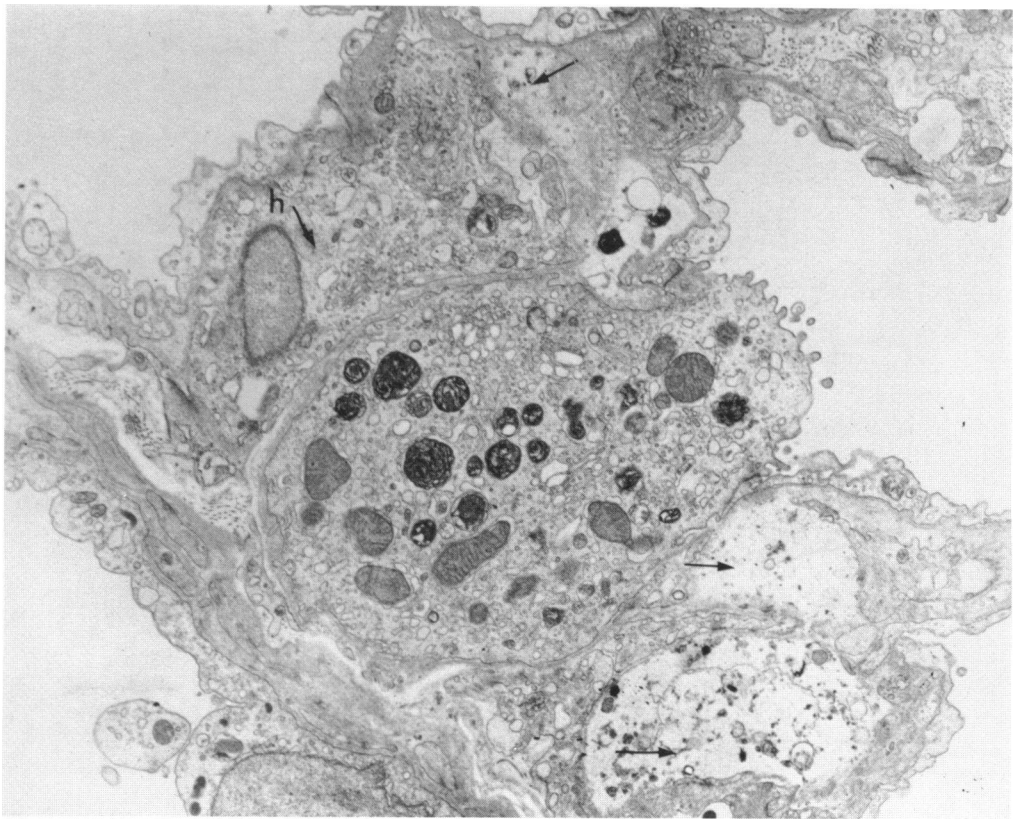

FIGURE 28. Degenerative alterations of the alveolar septal cells (arrows) and a hypertrophic septal cell (h with an arrow). Group I; 6000 ppm; OsO_4; 6300×.

nective tissue, lung, and adipose tissue have been well documented (*10*, *13*, *14*, *36*).

It is reasonable to assume that the alveolar capillary endothelium and the septal cell suffered toxic effects by vinyl chloride, since these cells are part of the mesenchymal elements in lung, sites of uptake and excretion of the chemical and its metabolites (*51*, *52*).

A dose-response relationship has been suggested in the production of alveolongenic tumors by vinyl chloride. The same relationship has been seen in occurrence of alveolitis (mouse) and bronchopneumonia (rats) with the chemical (*39*). A delayed appearance of these inflammatory changes after periods of recovery, following exposure to the chemical, has been postulated. A threshold dose for the induction of the nonneoplastic pulmonary lesions which are reported here has not been established.

This work was supported by Research Grant OH-00681 from the National Institute for Occupational Safety and Health, U.S. Department of Health, Education and Welfare.

REFERENCES

1. Block, J. B. Angiosarcoma of the liver following vinyl chloride exposure. J. Amer. Med. Ass. 229: 53-54 (1974).
2. Creech, J. L., Jr., and Johnson, M. N. Angiosarcoma of liver in the manufacture of polyvinyl chloride. J. Occup. Med. 16: 150-151 (1974).
3. Falk, H., Creech, J. L., Heath, C. W., Jr., Johnson, M. N., and Key M. M. Hepatic disease among workers at a vinyl chloride polymerization plant. J. Am. Med. Assoc. 230: 59-63 (1974).
4. Lange, C. E., Jühe, S., and Veltman, G. Über das Anftreten von Angiosarkomen der Leber von zwei Arbeitern der PVC-herstellender Industrie. Deut. Med. Wochenschr. 31: 1598-1599 (1974).

5. Lee, F. I., and Harry D. S. Angiosarcoma of the liver in a vinyl chloride worker. Lancet i: 1316-1319 (1974).
6. Nicholson, W. J., Hammond, E. C., Seidman, H., and Selikoff, I. J. Mortality experience of a cohort of vinyl chloride workers. Ann. N. Y. Acad. Sci. 246: 225-230 (1975).
7. Thomas, L. B., Popper, H., Berk, P. D., Selikoff, I. J., and Falk, H. Vinyl chloride-induced liver disease. N. Engl. J. Med. 292: 17-22 (1975).
8. Tabershaw, L. R., and Gaffey, W. R. Mortality study of workers in the manufacture of vinyl chloride and its polymer. J. Occup. Med. 16: 509-518 (1974).
9. Waxweiler, R. J., Stringer, W., Jones, J., Wagoner, J. K., Falk, H., and Carter, C. Neoplastic risk among workers exposed to vinyl chloride. Ann. N.Y. Acad. Sci. 271: 39-48 (1976).
10. Holmberg, B., Tronevi, T., and Winell, M. The pathology of vinyl chloride exposed mice. Acta Vet. Scand. 17: 328-342 (1976).
11. Keplinger, M. L., Goode, J. W., Gordon, D. E., and Calandra, J. C. Interim results of exposure of rats, hamsters and mice to vinyl chloride. Ann. N.Y. Acad. Sci. 246: 219-220 (1975).
12. Lee, C. C., Bhandari, J. C., Hause, W. B., Woods, J. B., and Dixon, R. L. Inhalation toxicity of vinyl chloride (VC) or vinylidine chloride (VDC) in rats and mice. Pharmacologist 18: 245 (1976).
13. Maltoni, C., and Lefemine, G. Carcinogenicity bioassays of vinyl chloride: current results. Ann. N. Y. Acad. Sci. 246: 195-218 (1975).
14. Maltoni, C., and Lefemine, G. Carcinogenicity bioassays of vinyl chloride. I. Research plan and early results. Environ. Res. 7: 387-405 (1974).
15. Suzuki, Y. Pulmonary tumors induced in mice by vinyl chloride monomer. Environ. Res. 16: 285-301 (1978).
16. Viola, P. L. Carcinogenic effects of vinyl chloride. Abstracts 10th International Cancer Conference, Houston, Texas, 1970.
17. Viola, P. L., Bigotti, A., and Caputo, A. Oncogenic response of rat skin, lungs and bones to vinyl chloride. Cancer Res. 31: 516-522 (1971).
18. Lilis, R., Anderson, H., Nicholson, W. J., Daum, S., Fischbein, A. S., and Selikoff, I. J. Prevalence of disease among vinyl chloride and polyvinyl chloride workers. Ann. N.Y. Acad. Sci. 246: 22-44 (1975).
19. Miller, A., Teirstein, A. S., Chuang, M., Selikoff, I. J., and Warshaw, R. Changes in pulmonary function in workers exposed to vinyl chloride and polyvinyl chloride. Ann. N.Y. Acad. Sci. 246: 42-52 (1975).
20. Buffer, A., Wood, S., Eifler, C., Suarez, L., and Kilian, D. J. Mortality experience of workers in a vinyl chloride monomer production plant. J. Occup. Med. 21: 195-202 (1979).
21. Svoboda, D. J. Ultrastructure of pulmonary adenoma in mice. Cancer Res. 22: 1197-1201 (1962).
22. Stewart, H. L., Dunn, T. B., and Snell, K. C. Pathology of tumors and non-neoplastic proliferative lesions of the lungs of mice. In: Morphology of Experimental Respiratory Carcinogenesis (P.N. Nettesheim, M. G. Hanna, and J. W. Deutherage, Eds., Atomic Energy Commission Symposium Series, No. 21, Oak Ridge, Tenn., 1970, pp. 161-168.
23. Stewart, H. L. Pulmonary tumors in mice. In: Physiopathology of Cancer, F. Homburger and W. Fishman, Eds., Hoeber and Harper, New York, 2nd ed., 1959, pp. 18-37.
24. Stewart, H. L., Grady, H. G., and Andervont, H. B. Development of sarcoma at site of serial transplantation of pulmonary tumors in inbred mice. J. Natl. Cancer Inst. 7: 207-225 (1974).
25. Heston, W. E. Induction of pulmonary tumors in strain A mice with methylbis(β-chloroethyl) amide hydrochloride. J. Natl. Cancer Inst. 10: 125-130 (1949).
26. Heston, W. E. Carcinogenic action of the mustards. Cancer Res. 10: 224 (1950).
27. Larson, C. D. Pulmonary tumor induction with alkylated urethranes. J. Natl. Cancer Inst. 9: 35-37 (1949).
28. Matsuzaki, O. Histogenesis and growing patterns of lung tumors induced by potassium 1-methyl-1,4-dihydro-7-[2-(5-nitrofuryl)vinyl]-4-oxo-1,8-naphthyridine-3-carboxylate in ICR mice. Gann 66: 259-267 (1975).
29. Gardner, M. B., Henderson, B. E., Rongey, R. W., Estes, J. D., and Huebner, R. J. Spontaneous tumors of aging wild house mice. Incidence, pathology and C-type virus expressions. J. Natl. Cancer Inst. 50: 719-734 (1973).
30. Rabstein, L. S., Peters, R. L., and Spahn, G. J. Spontaneous tumors and pathologic lesions in SNR/J mice. J. Natl. Cancer Inst. 50: 751-768 (1973).
31. Brooks, R. E. Ultrastructure of mouse pulmonary adenomas. In: Morphology of Experimental Respiratory Carcinogenesis, (P. N. Nettesheim, M. G. Hanna, and J. W. Deatherage, Eds. Atomic Energy Commission Symposium Series, No. 21, Oak Ridge, Tenn., 1970, pp. 185-202.
32. Madrazo, A., Suzuki, Y., and Churg, J. Radiation pneumonitis: Ultrastructural changes in the pulmonary alveoli following high doses of radiation. Arch. Pathol. 96: 262-268 (1973).
33. Kauffman, S. L., Alexander, L., and Sass, L. Histologic and ultrastructural features of the Clara cell adenoma of the mouse lung. Lab. Invest. 40: 708-716 (1979).
34. Amaral-Mendes, J. J. Histopathology of primary lung tumors in the mouse. J. Pathol. 97: 415-427 (1969).
35. Matsuyama, M., Suzuki, H., and Nakamura, T. Carcinogenesis in dd/1 mice injected during suckling period with urethane, nitrogen mustard N-oxide and nitrosourethane. Brit. J. Cancer 23: 167-171 (1969).
36. Schaffner, F. Effect of long term vinyl chloride exposure in mouse liver structure. In: Primary Liver Tumours, H. Remmer, Ed., MTP Press Limited, Falcon House, Lancaster, England. 1978. pp. 189-199.
37. Wells, H. G., Slye, M., and Holmes, H. F. The occurrence and pathology of spontaneous carcinoma of the lung in mice. Cancer Res. 1: 259-261 (1941).
38. Higginson, J. The role of the pathologist in environmental medicine and public health. A review. Am. J. Pathol. 86: 460-484 (1977).
39. McNamara, B. P. Personal communication.
40. Suzuki, Y. Nonneoplastic effects of vinyl chloride in mouse lung. Environ. Res. 21: 235-253 (1980).
41. Antweiler, H. Studies on the metabolism of vinyl chloride. Environ. Health Perspect. 17: 217-219 (1976).
42. Bartsch, H., Malaveille, C., Barbin, A., Bresil, H., Tomatis, L., and Montesano, R. Mutagenicity and metabolism of vinyl chloride and chloride and related compounds. Environ. Health Perspect. 17: 193-198 (1976).
43. Bolt, H. M., Kappus, H., Butchter, A., and Bolt, W. Disposition of 1,2-C-vinyl chloride in the rat. Arch. Toxicol. 35: 153-188 (1976).
44. Bolt, H. M., Laib, R. J., Kappus, H., and Buchter, A. Pharmacokinetics of vinyl chloride in the rat. Toxicology 7: 179-188 (1977).
45. Remmer, H. Metabolism of carcinogens: its significance for the initiation of liver tumors. In: Primary Liver Tumours, H. Remmer, Ed., MTP Press, Falcon House, Lancaster, England, 1978.
46. Wolff, M. S. Evidence for existence in human tissues of monomers for plastics and rubber manufacture. Environ. Health Perspect. 17: 183-187 (1976).

47. Smith, P., Heath, D., and Moosavi, H. The Clara cell. Thorax 29: 147-163 (1974).
48. Cook, W. A., Giever, P. M., Dinman, B. D., and Magnuson, H. J. Occupational acro-osteolysis II: An industrial hygiene study. Arch. Environ. Health 22: 74-82 (1971).
49. Popper, H., and Thomas, L. B. Alterations on liver and spleen among workers exposed to vinyl chloride. Ann. N.Y. Acad. Sci. 246: 172-194 (1975).
50. Veltman, G., Lange, C. E., Jühe, S., Stein, G., and Bachner, U. Clinical manifestation and course of vinyl chloride disease. Toxicity of vinyl chloride-polyvinyl chloride. Ann. N.Y. Acad. Sci. 246: 6-21 (1975).
51. Watanabe, P. G., McGowan, G. R., Madrid, E. O., and Gehring, P. J. Fate of [^{14}C] vinyl chloride following inhalation exposure in rats. Toxicol. Appl. Pharmacol. 37: 49-59 (1976).
52. Watanabe, P. G., and Gehring, P. J. Dose-dependent fate of vinyl chloride and its possible relation to oncogenicity in rats. Environ. Health Perspect. 17: 145-152 (1976).