Environmental Health Perspectives
Vol. 50, pp. 201-208, 1983

Human Liver Tumors in Relation to Steroidal Usage

by G. H. Barrows* and W. M. Christopherson*

Since 1973 a number of investigators have reported an association between liver neoplasia and steroid usage. Through referral material we have examined the histology of over 250 cases of hepatic neoplasia, most in patients receiving steroid medications. The majority have been benign, predominantly focal nodular hyperplasia (55%) and hepatocellular adenoma (39%). The average age was 31.4 years; 83% had significant steroid exposure with an average duration of 71 months for focal nodular hyperplasia and 79.6 months for hepatocellular adenoma. The type of estrogenic agent was predominantly mestranol; however, during the period mestranol was the most frequently used synthetic steroid. A distinct clinical entity of life threatening hemorrhage from the lesion occurred in 31% of patients with hepatocellular adenoma and 9% of patients with focal nodular hyperplasia. Recurrence of benign tumors has occurred in some patients who continued using steroids and regression has been observed in patients who had incomplete tumor removal but discontinued steroid medication. Medial and intimal vascular changes have been present in a large number of the benign tumors. The relationship of these vascular changes to oncogenesis is unclear, but similar lesions have been described in the peripheral vasculature associated with steroid administration. A number of hepatocellular carcinomas have also been seen. Of significance is the young age of these patients and lack of abnormal histology in adjacent nonneoplastic liver. A striking number of the malignant hepatocellular tumors have been of the uncommon type described as "eosinophillic hepatocellular carcinoma with lamellar fibrosis." The epidemiology of liver lesions within this series is difficult to assess, since the material has been referred from very diverse locations.

Introduction

Since 1973, an apparent association between benign liver tumors and steroid administration has been widely publicized. Although Baum (*1*) first drew widespread attention to the association with a report describing seven cases of "benign hepatomas," other authors had previously reported cases with steroid association (*2,3*). By 1977 over 500 reports associating liver tumors with steroid use had appeared in the literature, most by case reports and small series (*4*). The frequency of case reports has diminished over the past few years, since the association is now common knowledge, yet controversy continues regarding the type of tumors and their relationship to steroids. The infrequency with which these tumors occur has made it difficult for pathologists to develop a first-hand knowledge of the histology of these lesions (*5*). For this reason, histologic review of a large number of cases with reference to etiologic factors seemed worthwhile. We have had the opportunity to study in detail the histology of over 250 cases of hepatic tumors, most in patients receiving steroids. This presentation reviews the characteristic features of the lesions collected in this series and data regarding the first 201 cases (*6*).

*Department of Pathology, School of Medicine, University of Louisville and James Graham Brown Cancer Center, Louisville, Kentucky 40202.

Material and Methods

We have accessioned histologic material and case histories of liver neoplasms since 1973 and have organized this material into a small registry. Cases have been furnished by pathologists and clinicians over a wide geographic area. In addition to a histologic review with a uniform set of criteria, we have collected as many related data as possible including patient age, medications, clinical and laboratory findings and exposure to other known risk factors.

Results

It has been possible to categorize the tumors into three major types: focal nodular hyperplasia (FNH),

hepatocellular adenoma (HCA) and hepatocellular carcinoma (HCC). Focal nodular hyperplasia typically has a central scar and coarsely nodular appearance (Fig. 1). In most cases, FNH lacks encapsulation, although this is not a reliable gross characteristic. The lesions varied in size from 2 to 15 cm, and two distinct types are distinguishable. "Active lesions," which have a more varied gross appearance, often contain large regenerating nodules up to several centimeters in diameter. They frequently contain areas of necrosis and hemorrhage, and scarring is often minimal. Inactive lesions, more typical of the classical description of FNH, contain dense central scarring and fibrous trabeculae; hemorrhage and necrosis are absent. We believe such tumors represent involution or maturing of the more active lesions. They have at times been referred to as hamartomas (7).

The microscopic appearance of FNH is characteristic. Fibrosis with aggregates of bile duct epithelium intervenes between relatively normal hepatocytes (Fig. 2). There is no characteristic arrangement of the cells in relationship to venous or portal structures. The hepatocytes may contain glycogen or fat. Large nodules may be formed which are separated by fibrous septa. The presence of bile duct epithelium is a sine qua non of focal nodular hyperplasia. In large active examples of FNH, adequate sampling is essential, since the central portions of larger lesions may lack the characteristic areas of scarring with the adjacent exuberant proliferation of bile duct epithelium.

HCA (Fig. 3) is sufficiently characteristic that it can usually be distinguished from focal nodular hyperplasia by its gross characteristics. HCA tends to be of soft consistency and is yellow to dark brown. The lesions vary in size from 1 cm to 22 cm. On sectioning, the tumor at times has a variegated appearance due to necrosis, hemorrhage, and at times, bile staining. The fibrous trabeculae and scarring, so characteristic of FNH is absent. While HCA has usually been described as encapsulated, it often is not in steroid users. This suggests that in some cases of HCA may represent monomorphic hyperplasia. In some cases, intrahepatic hemorrhage is present (Fig. 4). The cells of HCA also resemble normal hepatocytes but usually have more nuclear variation. Nucleoli are usually present and are small and

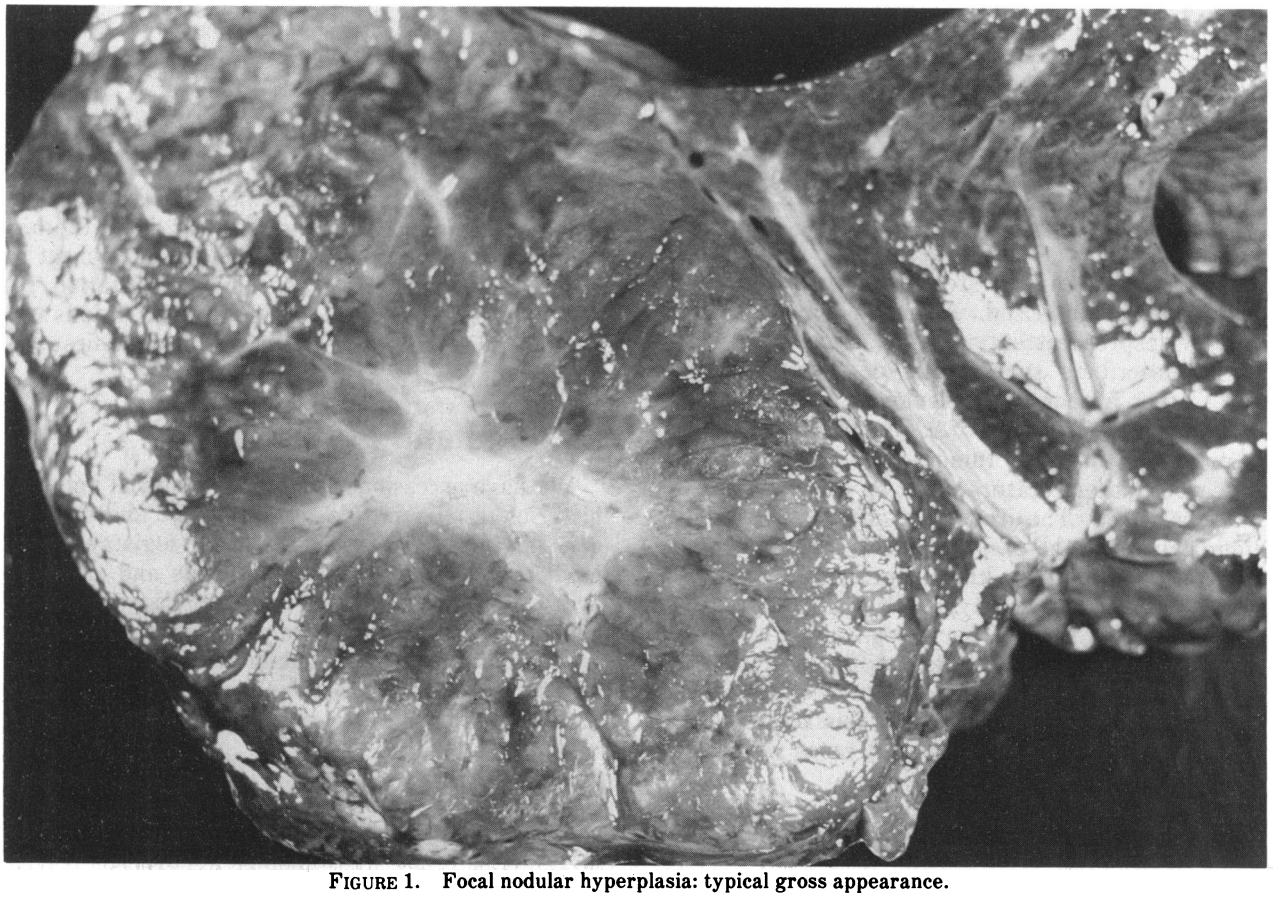

FIGURE 1. Focal nodular hyperplasia: typical gross appearance.

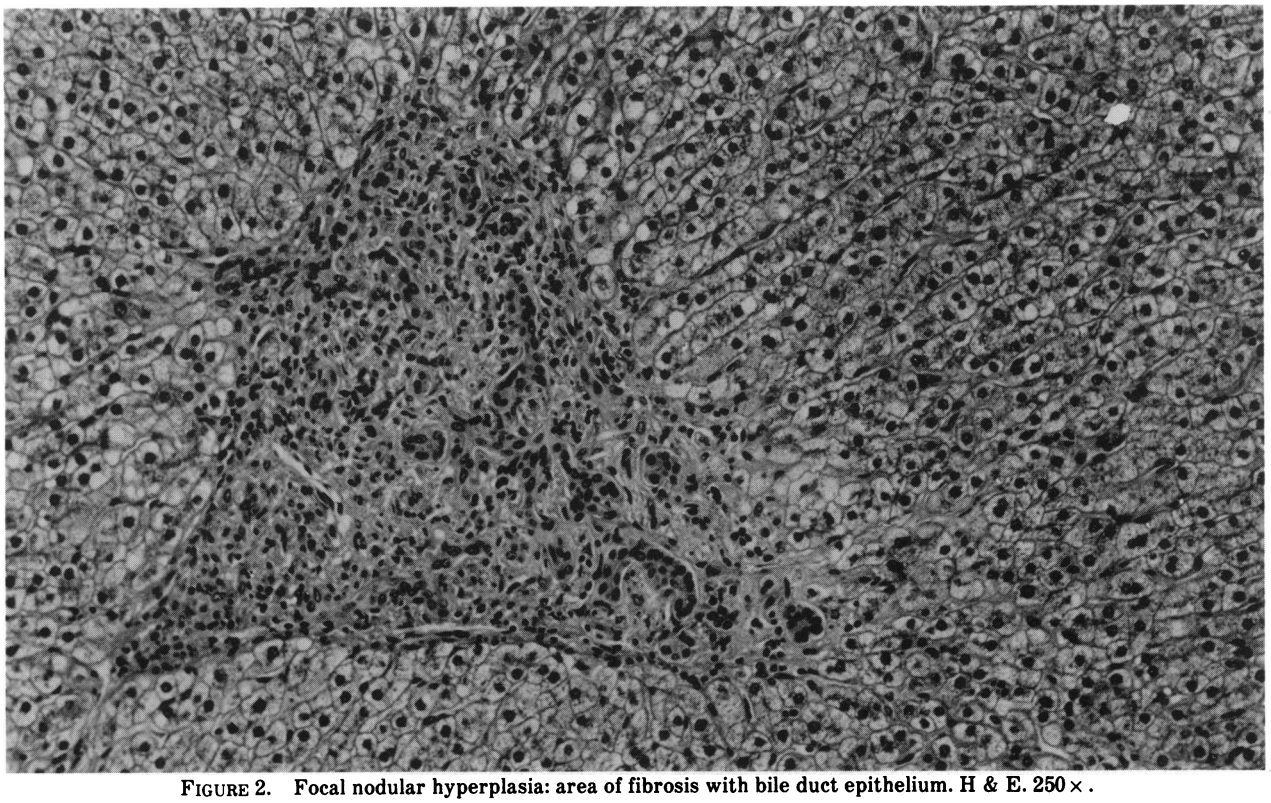

FIGURE 2. Focal nodular hyperplasia: area of fibrosis with bile duct epithelium. H & E. 250×.

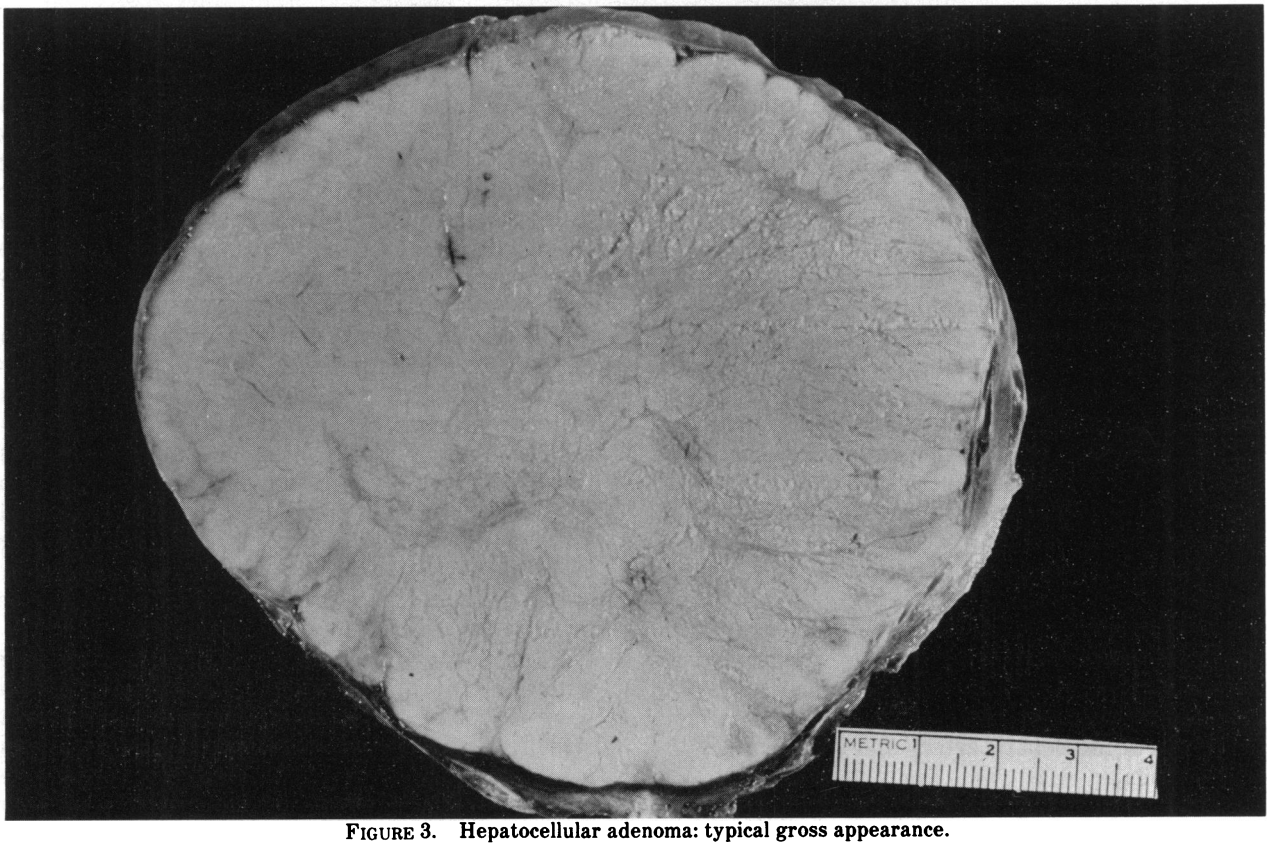

FIGURE 3. Hepatocellular adenoma: typical gross appearance.

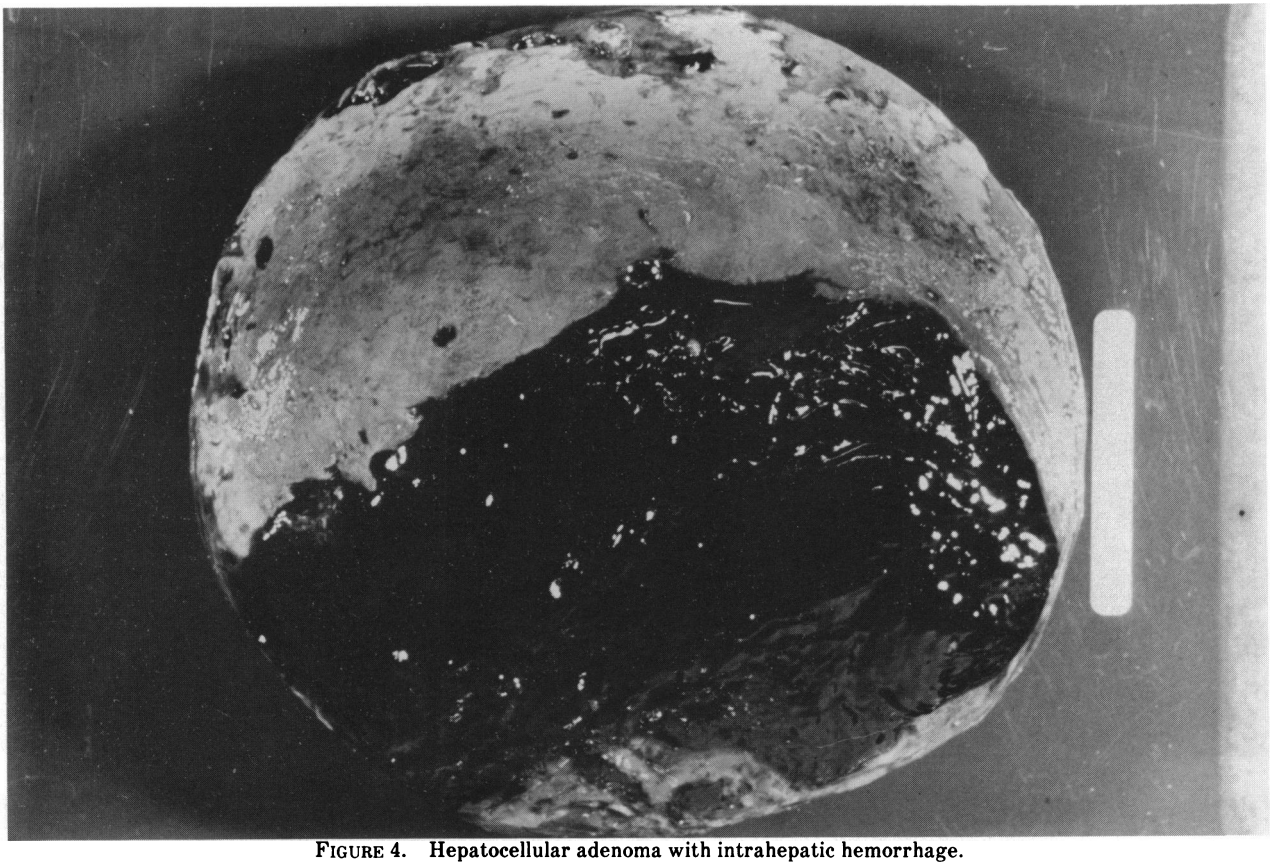

FIGURE 4. Hepatocellular adenoma with intrahepatic hemorrhage.

regular. Most tumors have spare mitotic activity but binucleate cells are present. The cells are arrayed in rather disorganized sheets, or in an acinic pattern. In contrast to FNH, there are usually numerous turn walled vascular channels, and most importantly no bile duct epithelium (Fig. 5).

HCC varies extensively in its gross appearance. All have been predominantly hepatocellular although two examples also contained cholangiolar elements. A distinctive subtype "eosinophilic hepatocellular carcinoma" accounted for 10 of the 23 cases (Fig. 6). This subtype has been uncommon in other reported series of hepatocellular carcinoma (*8,9*). Of significance is the lack of abnormal histology in the adjacent liver in the steroid related malignancies. Although 17 of the 23 cases were moderately well differentiated, there were no long-term survivors.

Characteristic vascular changes are found within some benign tumors, particularly FNH (Fig. 7). Smooth muscle proliferation and intimal thickening at times with occlusive thrombosis occurred in branches of the hepatic artery and tributaries of the portal vein.

A striking finding in both benign and malignant hepatocellular tumors is the presence of small, eosinophilic inclusions. They are PAS-positive, diastase-resistant and by immunoperoxidase technique have been shown to contain α_1 antitrypsin (*10*). Electron microscopy reveals them to be granular material within the endoplasmic reticulum. Small deposits are nonmembrane-bound, whereas large deposits are membrane-bound and found associated with smooth endoplasmic reticulum.

The age distribution of patients (Table 1) was similar in both FNH, and HCA with an average of 31.4 years and a range from 14 to 57 years (Table 2). The majority of patients took oral contraceptives (83%) with an average of 74.7 months exposure. An additional 3% were exposed to equine conjugated estrogens (Premarin) and 3% were pregnant or immediately post partum. Thus, a total of 89% of patients had significant steroid exposure, endogenous or exogenous. As in other studies, the predominant agent used among contraceptive users was mestranol.

Tumors were multiple in over 20% of women with benign tumors (Table 3). In most cases, there were only two or three separate tumors, but occasionally livers contained a large number. At times, inaccessibility of some of the multiple lesions precluded surgical resection. Those which have been unresectable have provided valuable insight of the

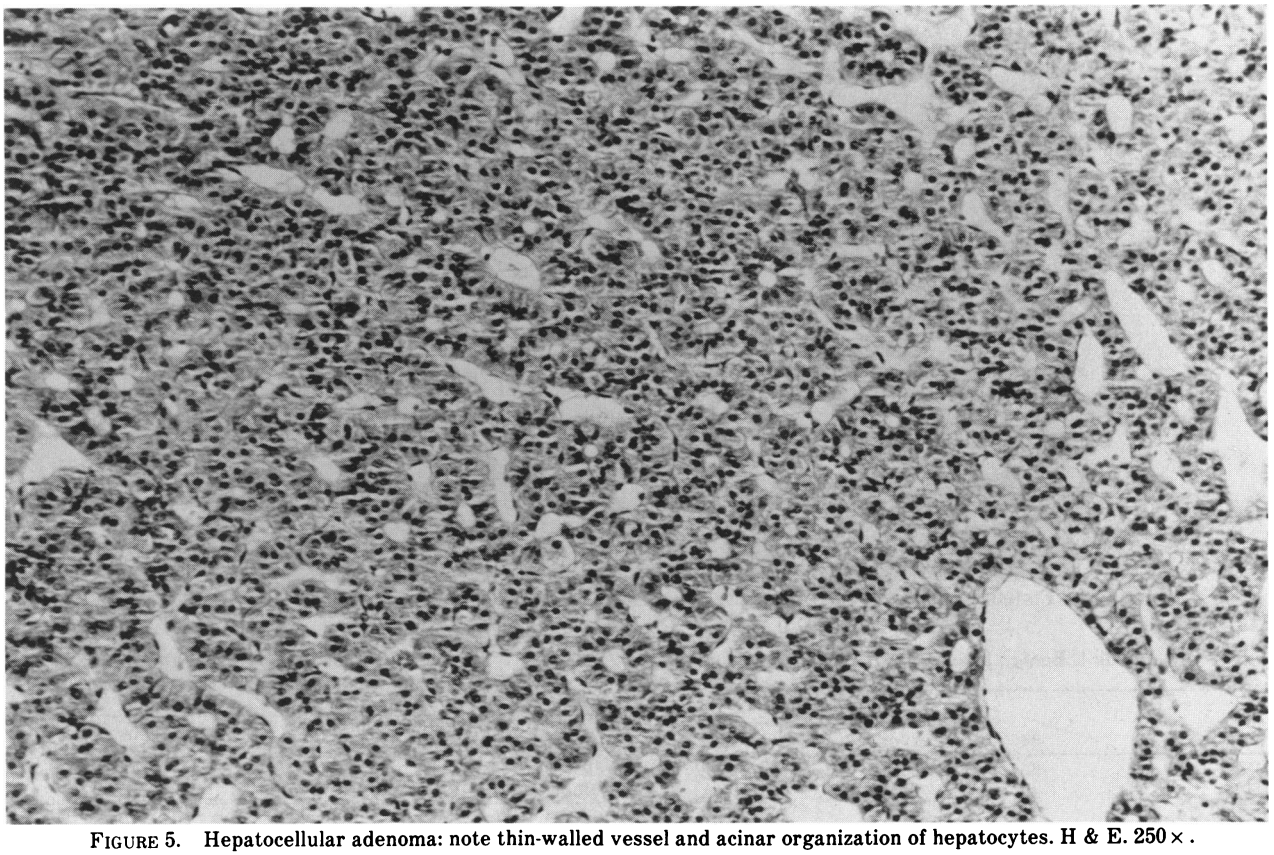

FIGURE 5. Hepatocellular adenoma: note thin-walled vessel and acinar organization of hepatocytes. H & E. 250×.

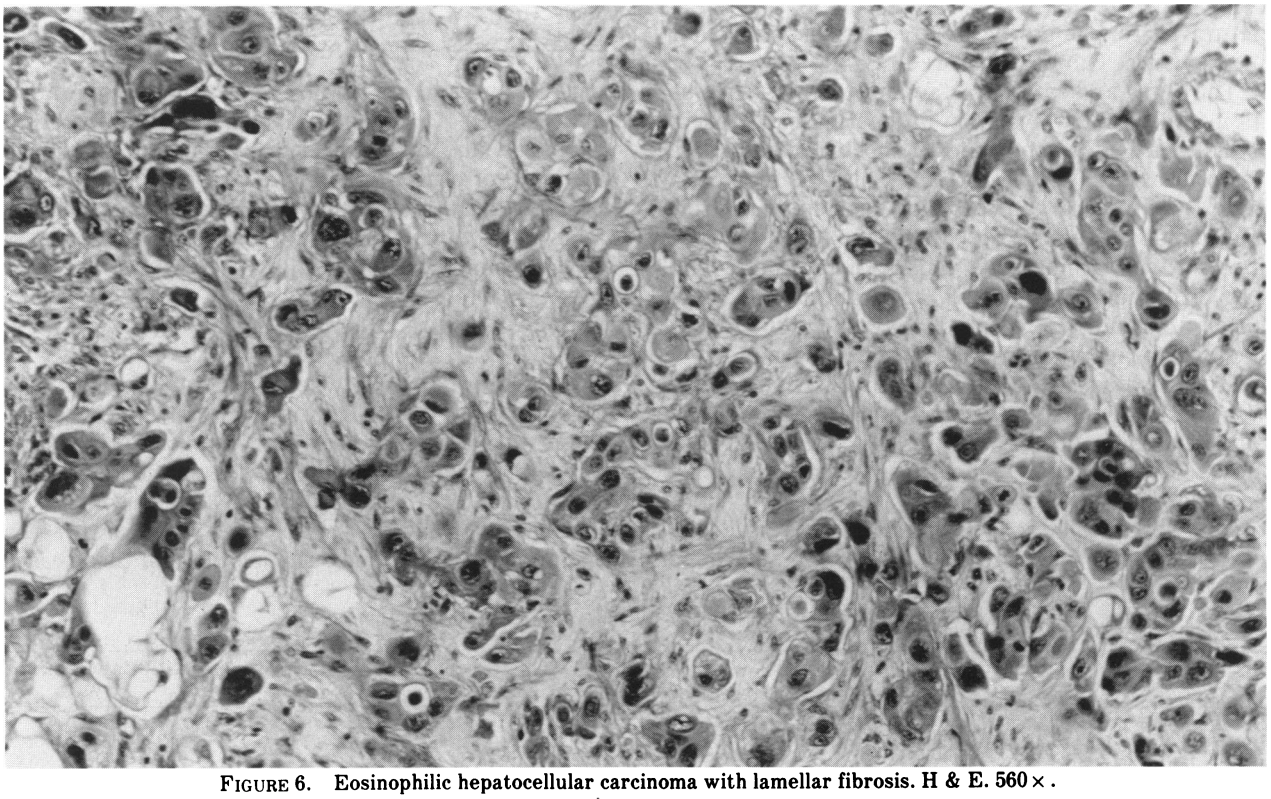

FIGURE 6. Eosinophilic hepatocellular carcinoma with lamellar fibrosis. H & E. 560×.

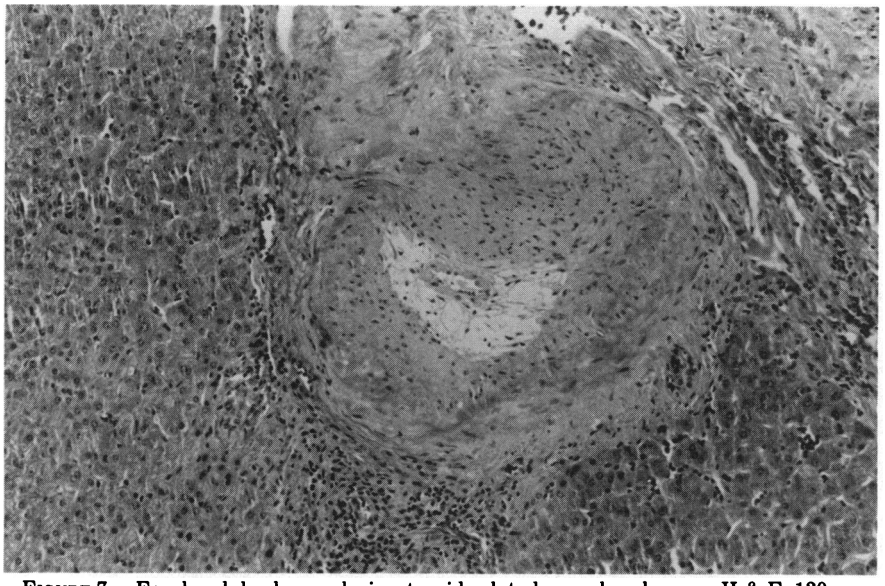

FIGURE 7. Focal nodular hyperplasia: steroid-related vascular changes. H & E. 130×.

Table 1. Benign liver tumors (n = 178).

	%	Age, yr Average	Range
FNH	55	32.3	19-52
HCA	40	30.2	14-55
Unclassified	5	30.3	27-47

natural history of steroid related lesions, since their future course can be monitored.

The signs and symptoms among patients with benign tumors were available in most cases (Table 4). A distinct clinical syndrome of shock and abdominal pain occurred in some patients. This was associated with intratumoral hemorrhage or tumor rupture and hemoperitoneum. The syndrome occurred more frequently in women with HCA. An additional number of patients presented with abdominal mass. Nearly one-half the cases of FNH were found incidentally during an unrelated surgical procedure.

Mortality associated with both FNH and HCA was confined to patients with tumor rupture and hemoperitoneum (Table 5). Despite incomplete removal of tumors, in some cases serious sequellae have not yet been reported.

The hepatocellular carcinomas in this series occurred almost exclusively among young women with an average age of 30.6 years, and an age range of 17-57. Of 23 patients, 20 had significant steroid exposure, and there was no historical or histologic evidence of other known risk factors (Table 6). The prognosis has been poor. Of 21 patients who have follow-up available, 20 died with metastases and the other patient is terminally ill.

Table 3. Incidence of multiple tumors in steroid-associated lesions.

Number of tumors	Percent of cases FNH (n = 98)	HCA (n = 71)
2-3	15.3	16.9
4-5	3.1	2.8
Many	2.0	4.2
Total	20.4	22.5

Discussion

The association between liver tumors and steroids does not prove the steroids to be causative. Some recent studies have been useful in establishing perspective. Klatskin (*11*) compiled signs and symptoms from case reports of 234 patients with FNH and 138 patients with HCA, not known to be receiving steroids. Since the majority of these cases

Table 2. Benign liver tumors: steroid association (n = 169).

	Contraceptive steroids, %	Conjugated estrogen, %	Pregnancy, %	None, %	Unknown, %
Focal nodular hyperplasia	82.7	4.1	1.0	5.1	8.2
Hepatocellular adenoma	83.1	1.4	5.6	7.0	2.8
Total	82.8	3.0	3.0	5.3	5.9

Table 4. Benign liver tumors signs and symptoms.

	Pain, %	Hemoperitis, %	Mass, %	Incidental, %
FNH (n = 98)	24.5	9.2	16.3	46.9
HCA (n = 71)	24.0	31.0	36.6	5.6
χ^2	0.006	13.1	9.1	33.7
p	0.93	<0.001	<0.001	<0.001

Table 5. Mortality in benign liver tumors.

	Mortality, %	No./total
HCA	7.0	(5/ 17)
FNH	2.0	(2/ 98)
Both	4.2	(7/169)

occurred before synthetic steroids were used for contraception, it is probably safe to assume that most did not receive exogenous steroids (*11*). Sixty percent occurred in women of child-bearing age. Although this documents that tumors may arise without exogenous steroids, it also suggests that they are related to natural hormonal variations. In further support of this observation is the occurrence of tumors during pregnancy or in the immediate postpartum period (*12,13*). Additional case reports have associated liver neoplasms with androgenic-anabolic steroids (*14,15*) and adrenal carcinoma (*7*).

The behavior of tumors incompletely resected also supports their dependency on steroids. Recurrence and enlargement of the tumors have been reported in cases where steroids have been continued (*16*). Regression of unresected tumors has also been documented when steroid therapy has been discontinued (*6,11,16-18*).

There is no clear implication of any specific type of steroid. While contraceptive steroids have been closely associated with these tumors, it should be remembered they are also by far the most commonly prescribed agents. As in other studies, mestranol was the most common estrogen in this series. Edmondson and associates have interpreted this to imply increased risk with this agent (*19*). As Sturtevant points out, however, if Edmondson's data are corrected for patterns of contraceptive product use at the time of occurrence, the observed association of mestranol use is probably related to marketing patterns of various contraceptive agents (*20*).

The frequent occurrence of tumor rupture and intra-abdominal hemorrhage in the patients receiving steroids also suggests a hormonal relationship. Comparing the two compiled historical series from Klatskin with the cases presented here, there is highly significant increase ($p < 0.001$) in the occurrence of hemoperitoneum in steroid users compared to nonusers (Table 7). The question of bias in reporting only steroid liver tumors was examined by Rooks et al in a case controlled study based on the patients accessioned in the AFIP Registry (*21*). These authors demonstrated the increased risk associated with steroid usage was the same before and after 1972 when the association between liver tumors and contraceptive steroids became widely known. They estimated the magnitude of risk of HCA to be 3.4/100,000 in women receiving contraceptive steroids and 1.0 to 1.3/million in nonsteroid users (*21*).

Table 6. Hepatocellular carcinoma associated with steroids (n = 23).

Medication	Number	Average duration of use
Oral contraceptives	17	56.6 months
Conjugated estrogen	1	Long-term
Postpartum	2	–
None	3	–

Table 7. Comparison of clinical signs: steroid-associated tumors compared to reported case without steroid usage.

Sign	Steroids[a]	No steroids[b]	χ^2	p
HCA Hemoperitoneum	31.0%	15.2%	13.0	<0.001
Mass or hepatomegaly	36.6	37.0	0.06	0.80
Pain	24.0	19.6	0.21	0.64
FNH Hemoperitoneum	9.2%	0.4%	18.1	<0.001
Mass or hepatomegaly	6.3	12.4	0.91	0.34
Pain	24.4	7.3	18.6	<0.001

[a] Adapted from Christopherson et al. (*6*). HCA, n = 71; FNH, n = 98.
[b] Adapted from Klatskin (*11*). HCA, n = 138; FNH, n = 234.

No predisposing factors for the development of benign liver tumors has yet been identified. The presence of α_1-antitrypsin inclusions in these lesions initially raised concern of a possible association with α_1-antitrypsin deficiency. However, Palmer in a small series of cases did not find any significant phenotype of α_1-antitrypsin deficiency (*10*).

The vascular changes associated with benign liver tumors in steroid users, particularly FNH, appear to be characteristic for these lesions (*12,22*). While there is no proof that these are primary, they are similar to lesions appearing in experimental animals receiving steroids. These vascular lesions also bear a striking resemblance to lesions reported in patients with reproductive steroid exposure (*23*).

Liver function tests and α-fetoprotein studies have been nondiagnostic when available in this series and also in the cases reported by Klatskin (*11*).

The hepatocellular carcinomas pose an area of great concern. Since malignant tumors of the liver

are much more common than benign lesions, the association between hepatocellular carcinoma and steroids is more tenuous. Of interest is the absence of hepatic fibrosis, a lack of cirrhoses and the young age in these patients. This is in marked contrast to reported series, where hepatocellular carcinoma is more frequent in males, occurs in middle-aged patients and is associated with cirrhoses in up to 90% of cases. Patients with HCC in this series had a dismal prognosis despite the prevalence of a reported favorable subtype (*8,9*). This subtype appears to have a less frequent association with cirrhosis than other carcinomas (*9*), which is in keeping with the absence of associated liver pathology in this series. Unlike the reported cases of HCC in males receiving anabolic steroids, most of these cases developed distant metastases (*22*).

REFERENCES

1. Baum, J. K., Bookstein, J. J., Holtz, F., and Klein, E. W. Possible association between hepatomas and oral contraceptives. Lancet ii: 926-929 (1973).
2. Caroli, J., Paraf, A., Charbonnier, A., and Vallin, J. Implantations d'oestrogénes apparement suivies d'un cancer primitif du foie. Rev. Intern. Hepatol. 3: 497-509 (1953).
3. Horvath, E., Kovacs, K., and Ross, R. C.: Ultrastructural findings in a well-differentiated hepatoma. Digestion 7: 74-82 (1972).
4. Sturtevant, F. M. Oral contraceptives and liver tumors. In: Controversies in Contraception (K. S. Moghissi, (Ed.), Williams and Wilkins, Baltimore, 1979, Chapter 7.
5. Edmondson, H. A. Tumors of the liver and intrahepatic bile ducts. Atlas of Tumor Pathology, Sec. 7, Fasc, 25. Armed Forces Institute of Pathology, Washington, DC, 1958.
6. Christopher, W. M., Mays, E. T., and Barrows, G. H. Liver tumors in young women: A clinical pathologic study of 201 cases in the Louisville Registry. Masson Publishing USA, New York. In: Progress in Surgical Pathology, Vol. II, Chap. 8 (C. M. Fenoglio and M. Wolff, Eds.), Masson Publishing, New York, 1980, pp. 187-205.
7. O'Sullivan, J. P., and Wilding, R. P. Liver hamartomas in patients on oral contraceptives. Brit. Med. J. 3: 7-10 (1974).
8. Berman, M. M., Libbey, N. P., and Foster, J. H. Hepatocellular carcinoma: polygonal cell type with fibrous stroma—an atypical variant with a favorable prognosis. Cancer 46: 1448-1455 (1980).
9. Okuda, K., and Peters, R. L. Hepatocellular carcinoma. Wiley and Sons, New York, 1976.
10. Palmer, P. E., Christopherson, W. M., and Wolfe, H. J. α_1-antitrypsin, protein marker in oral contraceptive-associated hepatic tumors. Am. J. Clin. Pathol. 68: 736-739 (1977).
11. Klatskin, G. Hepatic tumors: possible relationship to use of oral contraceptives. Gastroenterology 73: 386-394 (1977).
12. Malt, R. A., Hershberg, R. A., and Miller, W. L. Experience with benign tumors of the liver. Surg. Gynecol. Obstet. 130: 285-291 (1970).
13. Motsay, G. J., and Gamble, W. G.: Clinical experience with hepatic adenomas. Surg. Gynecol. Obstet. 134: 415-418 (1972).
14. Mulvilhill, J. J., Ridolfi, R. L., Schultz, F. R., Borzy, M. S., and Haughton, P. B. T. Hepatic adenoma in Fanconi anemia treated with oxymethalone. J. Pediat. 87: 122-124 (1975).
15. Sweeney, E. C., and Evans, D. J. Liver lesions and androgenic steroid therapy. Lancet 2: 1042 (1975).
16. Christopherson, W. M., Mays, E. T., and Barrows, G. H. Liver tumors in women on contraceptive steroids. J. Obstet. Gynec. 46: 221-223 (1975).
17. Edmondson, H. A., Reynolds, T. B., and Henderson, B. Regression of liver cell adenomas associated with oral contraceptives. Ann. Intern. Med. 86: 180-182 (1977).
18. Ross, D., Pina, J., Mirza, M., Galvan, A., and Ponce, L. Regression of focal nodular hyperplasia after discontinuation of oral contraceptives. Ann. Intern. Med. 85: 203-204 (1976).
19. Edmondson, H. A., Henderson, B., and Benton, B. Liver-cell adenomas associated with use of oral contraceptives. N. Engl. J. Med. 294: 470-472 (1976).
20. Sturtevant, F. M. Liver tumors and oral contraceptives. Paper presented at Pan-American Conference on Fertility and Sterility, Dorado Beach, Puerto Rico, Feb. 4-12, 1977.
21. Rooks, J. B., Ory, H. W., Ishak, K. G., Strauss, L. T., Greenspan, J. R., Hill, A. P., and Tyler, C. W. Epidemiology of hepatocellular adenoma: The role of contraceptive use. J. Am. Med. Assoc. 242: 644-648 (1979).
22. Christopherson, W. M., Mays, E. T., and Barrows, G. H. Hepatocellular carcinoma in young women on oral contraceptives. Lancet ii: 38-39 (1978).
23. Irey, N. S., and Norris, H. J. Intimal vascular lesions associated with female reproductive steroids. Arch. Pathol. 96: 227-234 (1973).