Environmental Health Perspectives
Vol. 54, pp. 153–161, 1984

Histopathology of Early Effects of Oral Cadmium in the Rat Kidney

by E. Aughey,* G. S. Fell,† R. Scott† and M. Black‡

Adult male Wistar rats were given 50 ppm Cd in drinking water over a period of 1–24 weeks. The rats were killed and the cadmium concentration of whole blood, blood plasma red cells, liver and kidneys estimated. The plasma metallothionein concentration was measured by radioimmunoassay. Kidney samples were taken for light, transmission and scanning electron microscopic examination. The accumulation of cadmium in the tissues was shown by a linear increase with time, after exposure for 12 weeks. Plasma Cd concentrations showed a clear increase after 3 weeks and preliminary investigation suggests that most is present as Cd-thionein. Early pathological changes in the rat kidney were seen around the 4–6 week period which coincided with the distinct rise in plasma Cd.

At 12 weeks, signs of tubular necrosis, interstitial fibrosis and glomerular epithelial cell hypertrophy were present in small areas of the cortex. By 24 weeks, the renal cortex showed clear evidence of tubulo-interstitial nephritis at a Cd concentration of 60 μg Cd/g wet weight.

Introduction

The mammalian kidney is a target organ for a wide variety of toxic agents due to its prime function as a blood filter during the excretory process. Cadmium (Cd) is a toxic heavy metal increasingly being recognized as a potential environmental pollutant. Renal tubular damage occurs with long-term exposure and the accumulation of Cd in the kidney after the "critical tissue level" is reached (*1–3*). Some of the Cd carried to the kidney in the blood plasma is bound to a low molecular weight protein metallothionein that is cleared through the glomerulus and absorbed by the proximal tubular cells (*4*). The injurious effect of Cd metallothionein has been demonstrated by the occurrence of renal tubular damage immediately following injection of this complex, in contrast to the lack of immediate response in the kidney to a similar injection of Cd chloride (*5*). It has been shown that the renal tubular necrosis is, however, related to the Cd content of the metallothionein (*6*). Secondary to the renal tubular necrosis is an increase in connective tissue and interstitial fibrosis. In the experiments by Cherian, Suzuki and others, Cd chloride and Cd metallothionein were given by injection. To study long-term effects of Cd exposure, it is necessary to subject the experimental animal to low doses of cadmium over an extended period of time. The results of several experiments where rats were given Cd chloride orally have not shown much evidence of nephropathy, although proteinuria was reported (*7–10*).

We have shown previously (*11*) that when rats were fed 50 ppm Cd in drinking water over a period of 1–24 weeks, microscopic examination of the kidneys showed small lesions developing as early as 4 weeks with easily discernable tubular damage and protein casts at 12 weeks when the cortical burden was 30 μg Cd/g wet weight; at 24 weeks the kidneys had obvious tubulo-interstitial nephritis. This animal model indicated that measureable kidney damage had occurred at renal cortical Cd concentrations well below the critical threshold proposed for man of 100–200 Cd μg/g. Therefore, this experiment has now been repeated, and by using sensitive biochemical and histological methods, the Cd uptake by blood, liver and kidney has been studied and the early histological changes related to the Cd concentration and the appearance of Cd as metallothionein in circulating blood plasma.

*University of Glasgow, Veterinary School, Bearsden Road, Glasgow, Scotland.
†Royal Infirmary, Glasgow, Scotland.
‡Strathclyde University, Glasgow, Scotland.

Materials and Methods

One group of 16 adult male Wistar rats was given 50 ppm Cd in drinking water, and a second group of 8 was given distilled water. The rats were offered standard diet and water *ad libitum*. Two rats from the Cd group and one control rat were killed at 1, 2, 3, 4, 8, 12, 18 and 24 weeks by intravenous Immobilon injection. Blood was taken from the abdominal aorta and the liver and kidneys removed. All blood and tissue samples were collected and stored in plasticware made free from Cd contamination.

Light Microscopy

Small blocks of tissue were taken from the lower pole of the right kidney and fixed in buffered neutral formalin. Sections of 3 μm thickness were cut and stained with hematoxylin and eosin.

Electron Microscopy

Small pieces of the above tissue were fixed in paraformaldehyde–gluteraldehyde, routinely processed and embedded in Epon. Sections of 1 μm were cut and stained with toluidine blue to allow area selection. Ultrathin sections were cut on an LKB ultratome, stained with uranyl acetate and lead citrate and examined at 50 kV in a Hitachi HS8 electron microscope. For scanning electron microscopy studies, slices of kidney 1 mm thick were fixed in paraformaldehyde–gluteraldehyde for a minimum of 24 hr. The slices were then washed in 0.1 M cacodylate buffer overnight and then dehydrated in a graded series of acetones. Tissues were then dried in a Polaron critical point dryer, mounted on stubs, and coated with gold in an Emscope sputter coater, before viewing in a Phillips 50 1B scanning electron microscope.

Cadmium Determination

Whole blood cadmium was measured by carbon furnace atomic absorption spectrophotometry (CFAAS) using prior dilution (1:5) and deproteinization with nitric acid (10% Aristar Grade). A 20 μL portion of the deproteinized supernatant acid solution was injected into the carbon furnace and after programmed drying, ashing and atomization, the cadmium absorbance at 228.8 nm was measured; optical background correction using a D_2 arc was required to compensate for matrix interferences. A Perkin-Elmer model 2280 spectrometer was used, with an HGA-500 furnace and AS-1 auto-sampler. Calibration was by comparison with cadmium added to whole human blood. The analytical conditions were based on those described by Stoeppler and Brandt (*12*). Plasma cadmium was measured in a similar manner.

Liver and kidney samples were prepared by wet-ashing a known weight of tissue (about 1 g) in nitric acid (Aristar Grade). The cooled acid solution was made up to 25 mL with water and cadmium determined by atomic spectrometry using an air/acetylene flame (PE model 403). Calibration standards were prepared in dilute nitric acid of similar strength to that in the test samples. The procedure was shown to be free from interference effects by comparison with an atomic fluorescence method (*13*). Accuracy was proven by satisfactory analysis of National Bureau of Standards dried bovine liver powder of certified cadmium content.

The radioimmunoassay to measure plasma metallothionein was carried out at the Rowett Research Insitute by Dr. Ian Bremner and Mr. R. K. Mehra by use of an antibody raised in sheep to thionein isolated from rat liver.

Results

Biochemical Observations

The accumulation of Cd in rat tissues is shown by the linear increase with time of exposure in both liver and kidney (Fig. 1). Whole blood Cd (which mainly reflects red cell Cd) also increased linearly with time, but after 12 weeks a steady state was reached with total blood levels remaining fairly constant at 30–33 μg Cd/L (Fig. 2). Plasma Cd concentrations are much lower than whole blood Cd (Fig. 2). A clear increase is detectable after 3 weeks and values increase gradually from less than 1 μg Cd/L to a fairly constant level of 8–9 μg Cd/L. Preliminary investigation of the nature of the Cd species in rat plasma suggests that most is present as Cd-thionein. The radioimmunoassay indicates a sharp increase in plasma metallothionein after 3–4 weeks oral dosage with Cd. The close relationship between plasma Cd concentration and the appearance of metallothionein in the plasma is shown in Figure 3.

Microscopic Observations

The renal cortex and medulla from all the experimental and control rats were examined with the light microscope. At least five fields from each section of cortex were assessed for the appearance of the glomerulus, the associated tubules and interstitial tissue and this was compared with control sections taken at the same time and processed by exactly the same method. The medulla was examined for histological change at the same time.

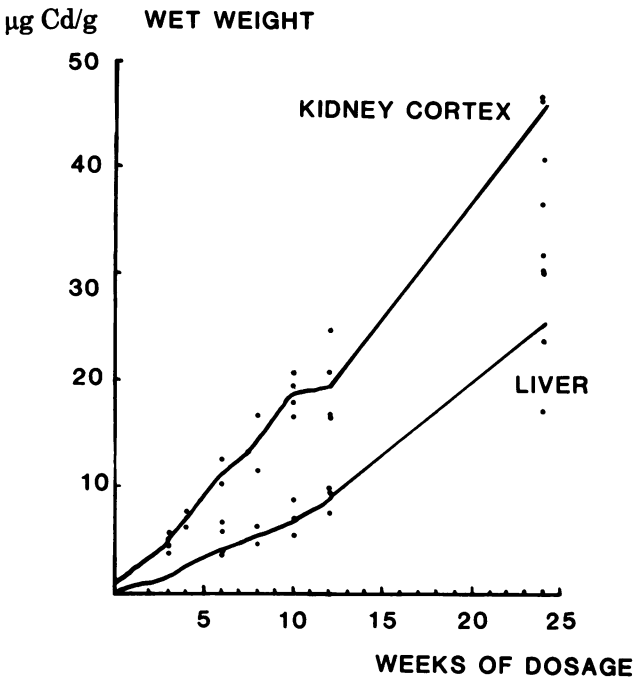

FIGURE 1. Cadmium concentration in the liver and kidneys of rats given 50 µg Cd/L in their drinking water *ad libitum* for 24 weeks.

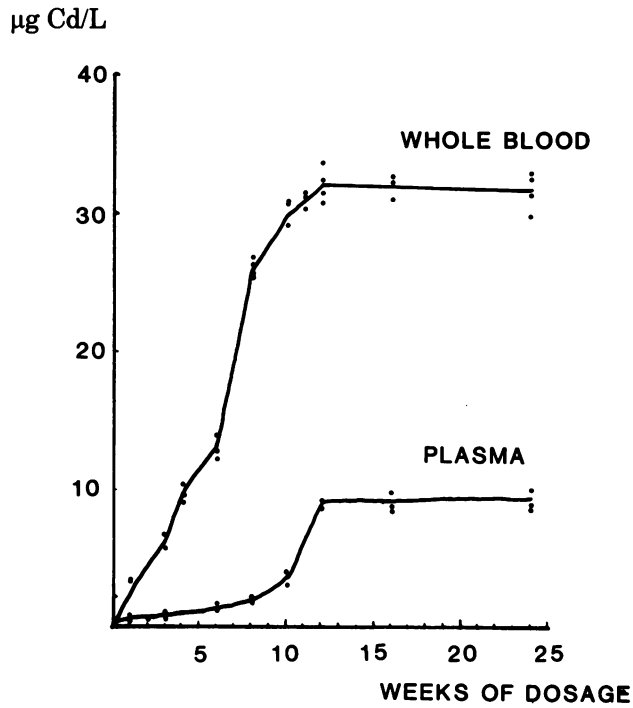

FIGURE 2. Cadmium concentration in whole blood and plasma samples from rats given 50 µg Cd/mL in their drinking water *ad libitum* for 24 weeks.

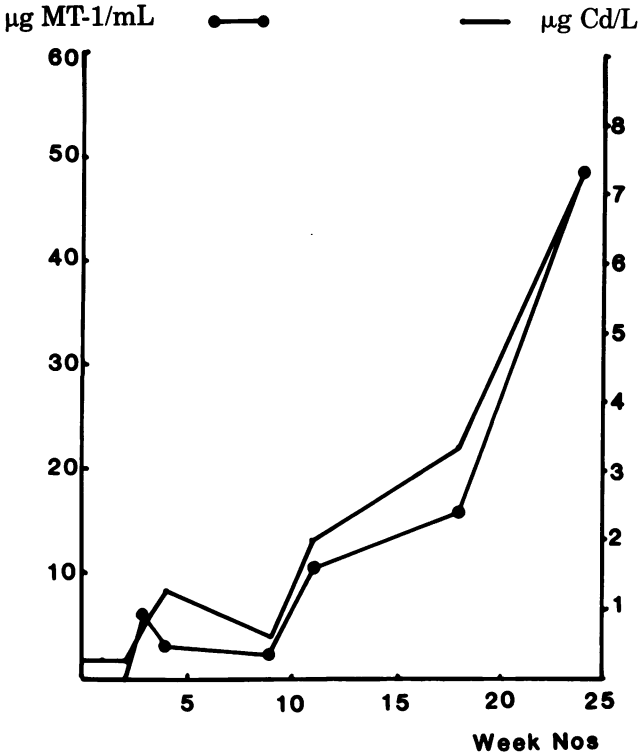

FIGURE 3. Relationship between plasma cadmium concentration and plasma metallothionein isoform 1 (MT-1) concentration in rats given 50 µg Cd/mL in their drinking water *ad libitum* for 24 weeks.

The results showed minor areas of tubular necrosis in the Cd rat after 8 weeks oral dosage, some glomeruli had an increased cellular appearance and the capsule space was absent (Fig. 4). Protein casts were present in the medulla (Fig. 5). In the 12-week Cd-dosed rat the tubular injury was more extensive and an increased number of lesions noted in addition to the glomerular changes already described (Fig. 6). Protein casts were again present in the medulla. In the 24-week Cd-dosed rat there were obvious areas of tubular necrosis, vascular changes with interstitial edema and glomerular fibrosis and cell hypertrophy (Fig. 7). The control kidneys showed no evidence of glomerular, tubular or interstitial injury and there were no protein casts in the medulla (Fig. 8).

Areas of the renal cortex containing a glomerulus and associated tubules were selected for examination with the electron microscope. In the 4-week Cd-dosed rat there appeared to be an increase in the dense bodies in the proximal convoluted tubule cells (PCT). In the 6-week Cd-dosed rat individual cells in the PCT were necrotic, and the surrounding interstitial tissue showed some collagen deposition and disrupted vascular endothelium (Figs. 9 and 10). By 12 weeks of Cd dosage, there was considerable tubular cell necrosis and interstitial fibrous tissue

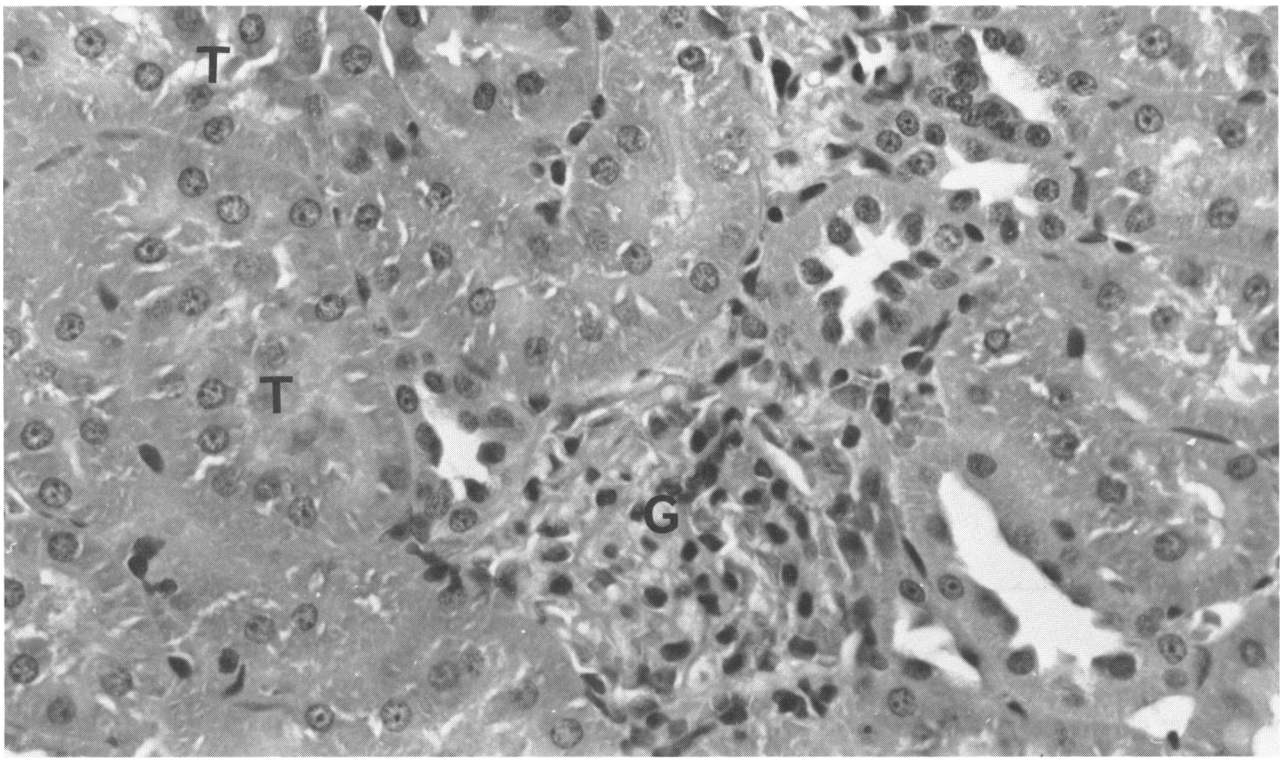

FIGURE 4. Light micrograph of the renal cortex from a rat after 8 weeks on oral Cd illustrates tubular necrosis (T) and glomerular swelling (G) H&G, × 250.

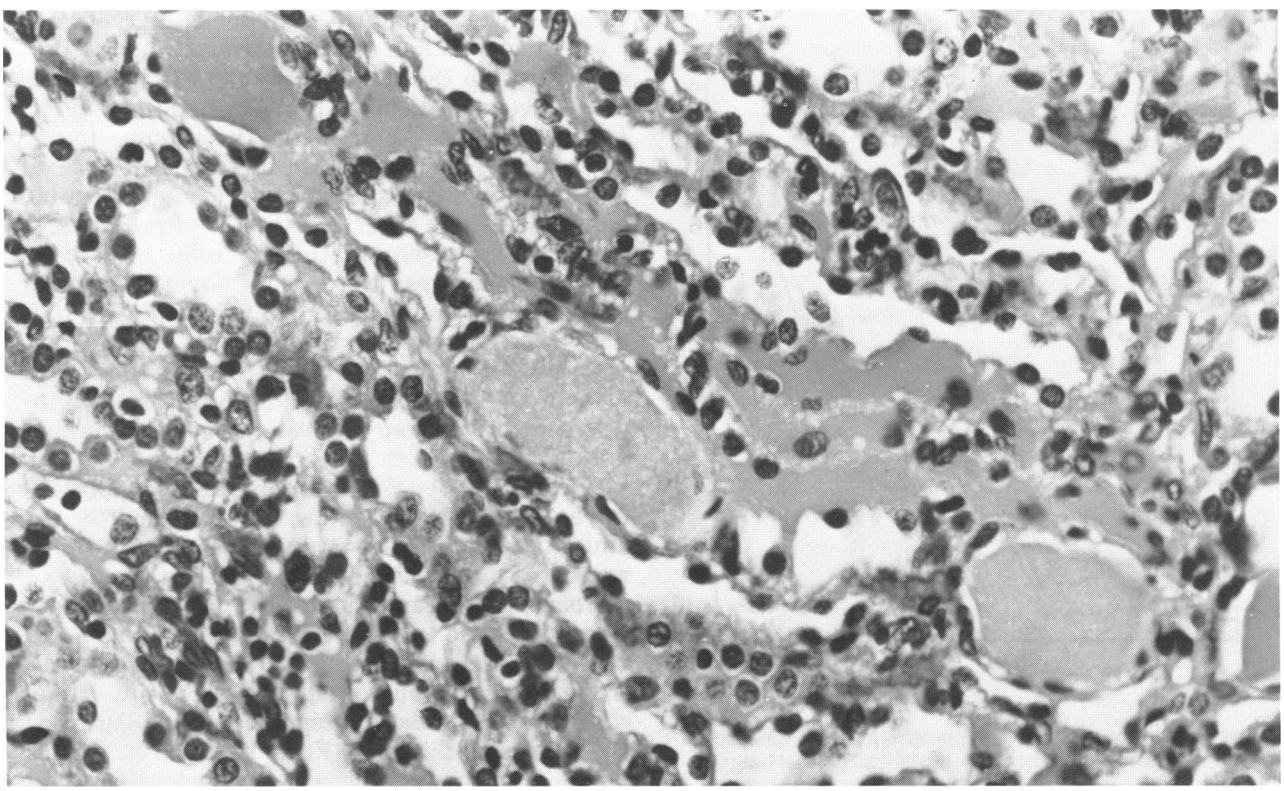

FIGURE 5. Light micrograph of the medulla from the same rat (Fig. 4) to show the protein in the collecting tubules. H&E, ×250.

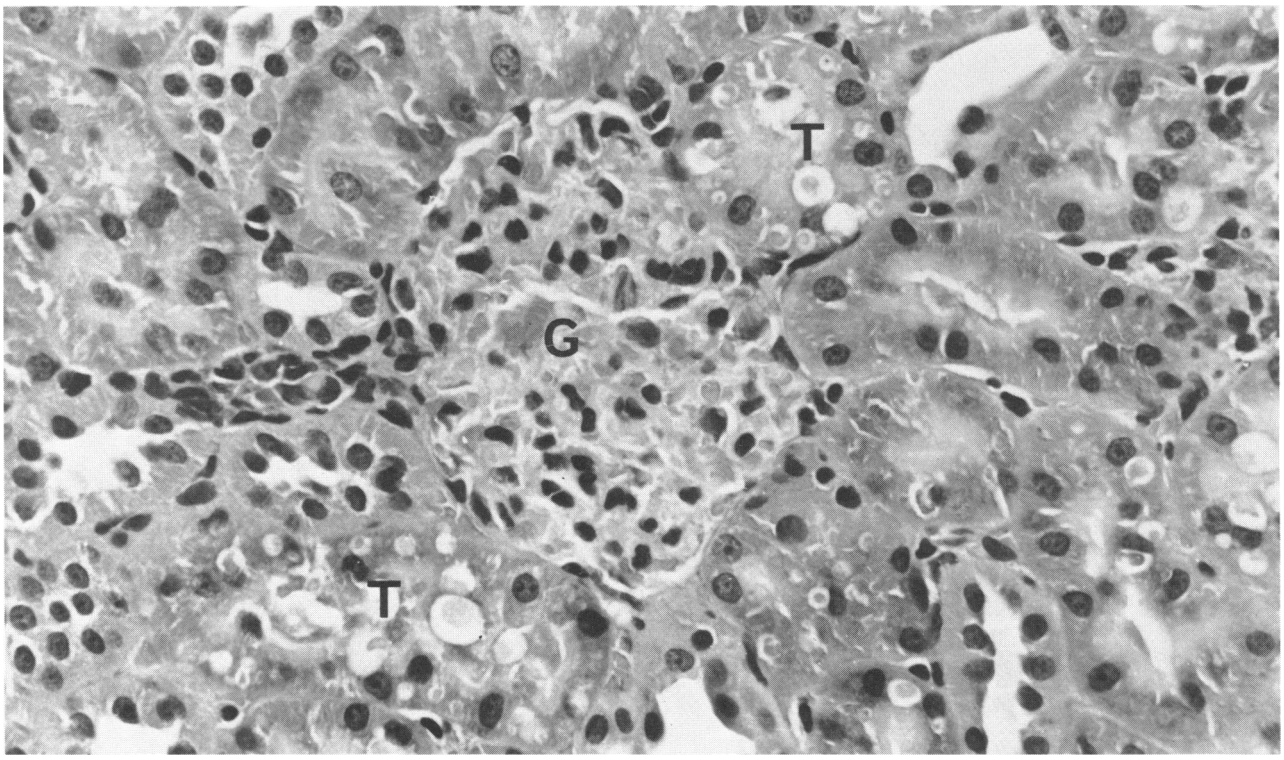

FIGURE 6. Light micrograph of the renal cortex from a 12-week oral Cd rat shows local areas of tubular necrosis (T) and glomerular swelling (G). H&E, ×250.

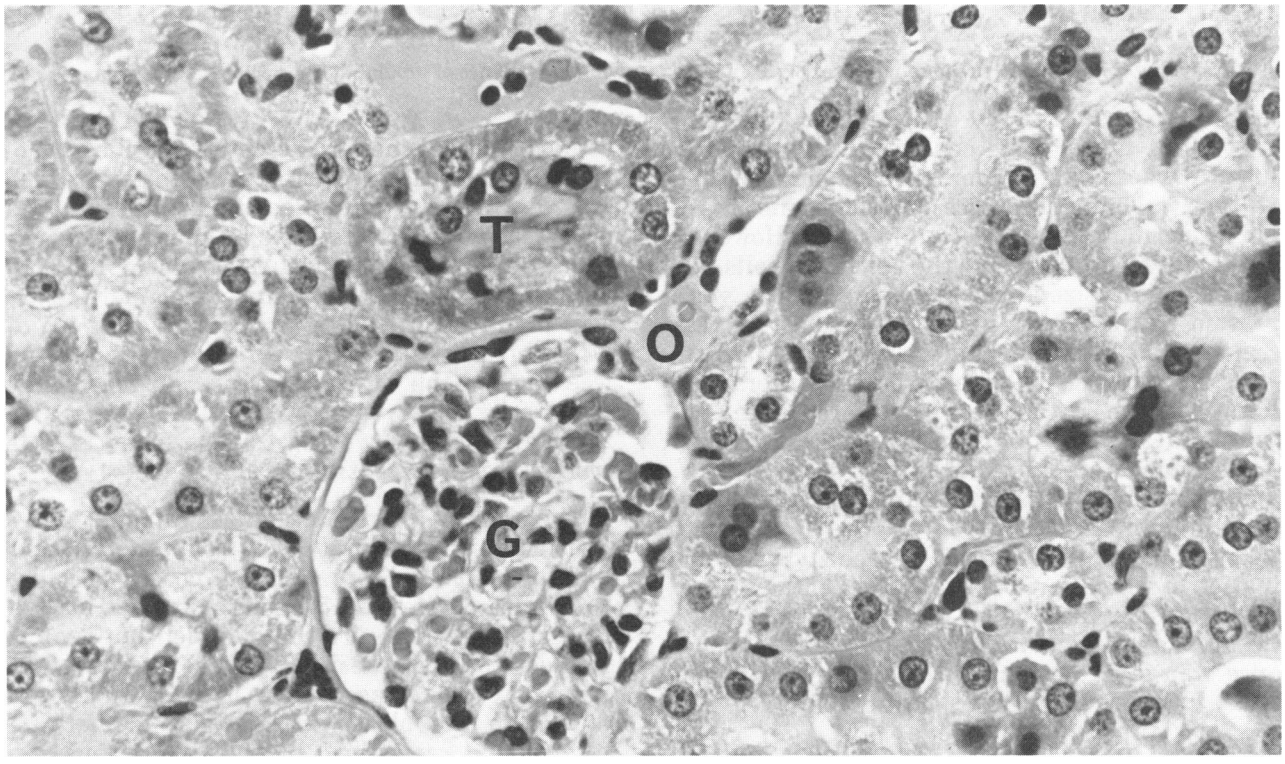

FIGURE 7. Light micrograph of the renal cortex from a 24 week-oral Cd rat shows local areas of quite severe tubular injury (T) associated with glomerulus (G) with a thickened capsule and a small area of edema (O). H&E, ×250.

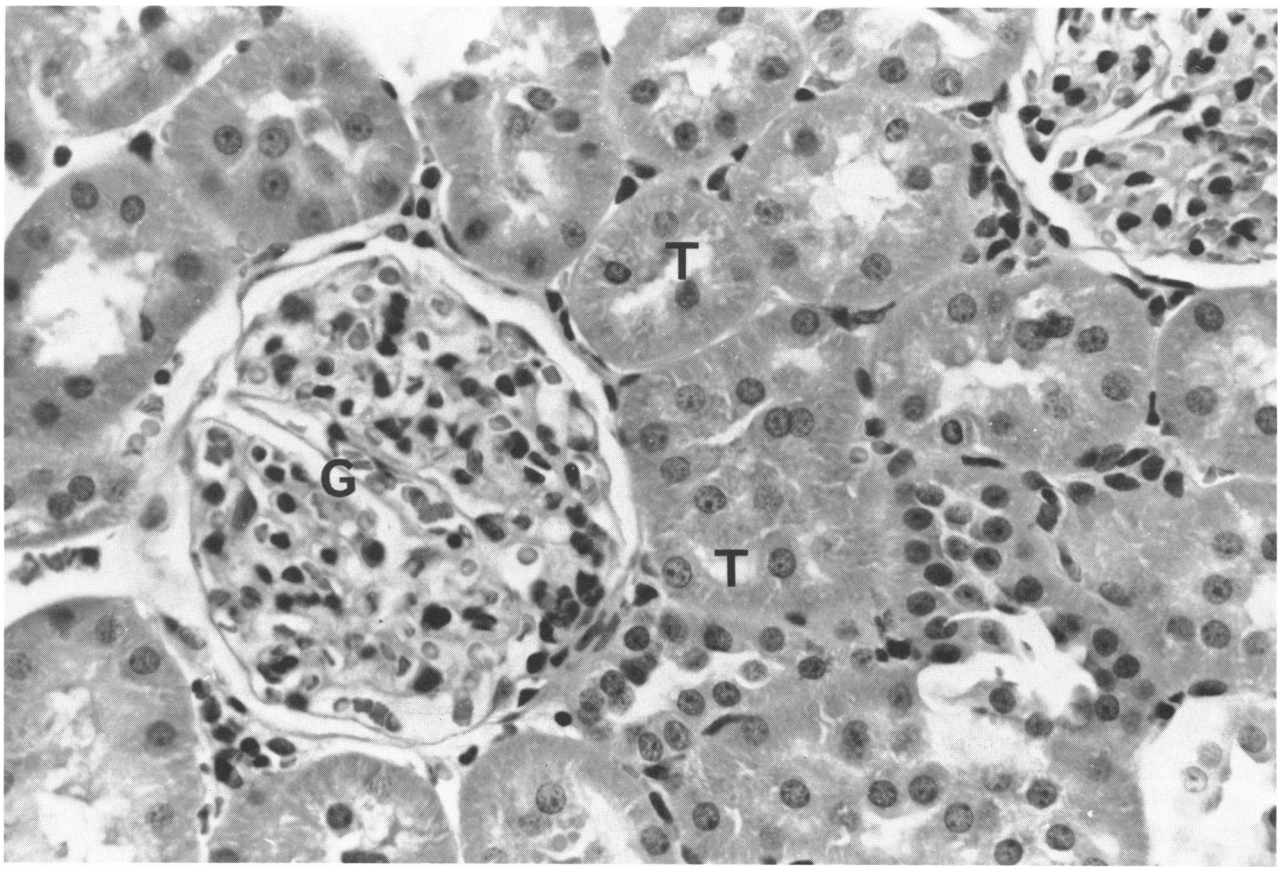

FIGURE 8. Light micrograph of the renal cortex of a control rat showing no evidence of tubular (T) or glomerular (G) lesions H&E, ×250.

deposition. Histological changes in the glomerulus at 6 weeks were minor, with some fusion and withdrawal of foot processes, but it was not possible to attribute this directly to the Cd. However, by 12 weeks of Cd dosage, the epithelial cells had increased in size and many organelles were present in the abundant cytoplasm; foot process fusion was a constant finding (Fig. 11). Platelets were a feature of the glomerular and interstitial blood vessels. By 24 weeks of Cd dosage, the tubulo-interstitial fibrosis was well established with considerable areas of foot process withdrawal and fusion and thickening of the capillary endothelium.

The scanning electron microscope allows examination of a large area of the surface of the cortex. Specimens confirmed the increase in connective tissue and the glomerular epithelial cell appearance was more obvious with foot process fusion and bulbous swelling of the extreme tips (Fig. 12).

Discussion

The histopathological lesions described above conform to the generally accepted classification of tubulo-interstitial nephritis. The pattern which emerges in the cadmium-exposed rat is that of a progressive nephrotic syndrome affecting first the tubules and surrounding blood vessels and connective tissue with secondarily a glomerular lesion involving the epithelial cells and the capillary loop. Slight changes were first noted at 4–6 weeks when the Cd concentration in the kidney was 6–8 μg Cd/g wet weight, well below the 100–200 μg Cd/g wet weight considered to be the critical organ concentration in man (*3,14*).

The early pathological changes coincide with a distinct rise in plasma Cd. Plasma metallothionein as measured by radioimmunoassay also becomes detectable after 3 weeks on oral Cd dosage. These findings require confirmation but tend to support the hypothesis (*2*) that excess Cd-thionein may be released from liver stores, transported in the blood to the renal glomerulus, filtered and reabsorbed by the PCT where it is catabolized, releasing Cd ions which cause renal damage.

FIGURE 9. Transmission electron micrograph of the basal area of a tubular cell after 6 weeks dosage with Cd showing the thickened basal lamina (BL) and myelin figures (M). The basal invaginations have been lost. Uranyl acetate-lead citrate, ×6500.

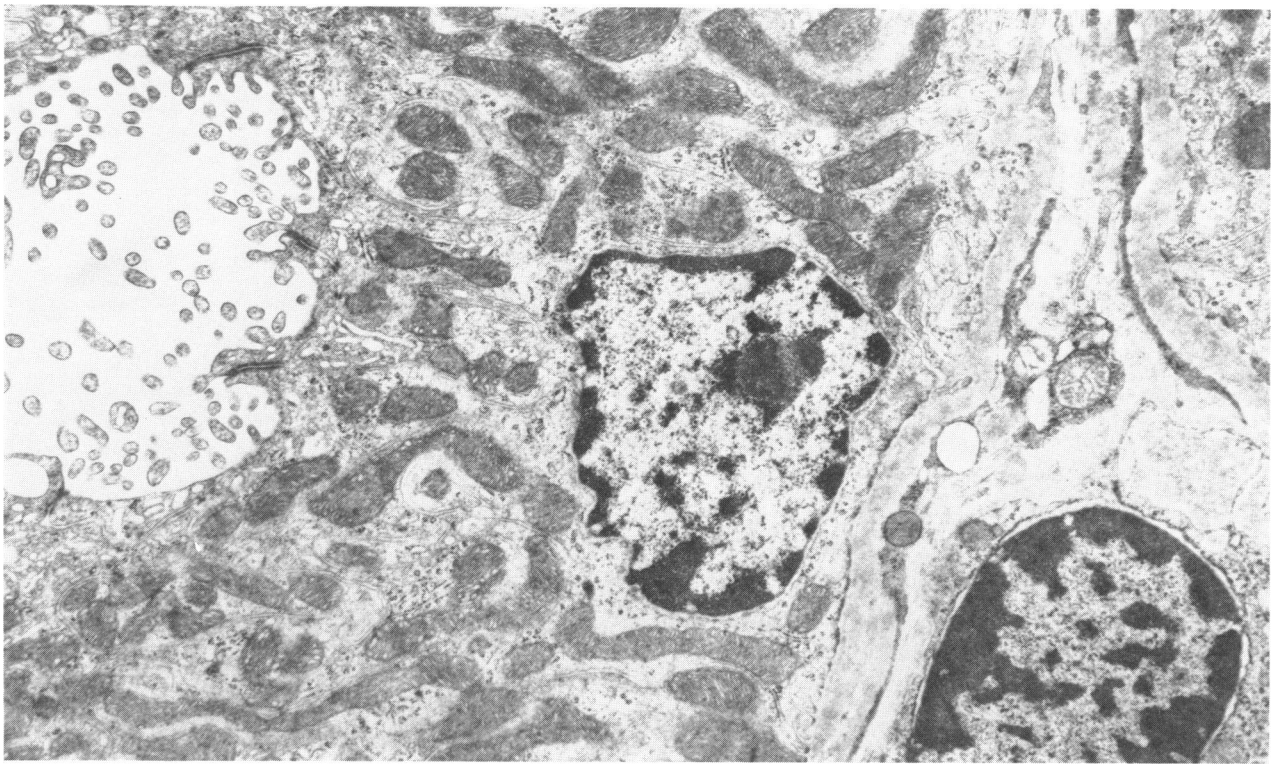

FIGURE 10. Low power transmission electron micrograph to show a control tubular cell. Uranyl acetate-lead citrate, ×4000.

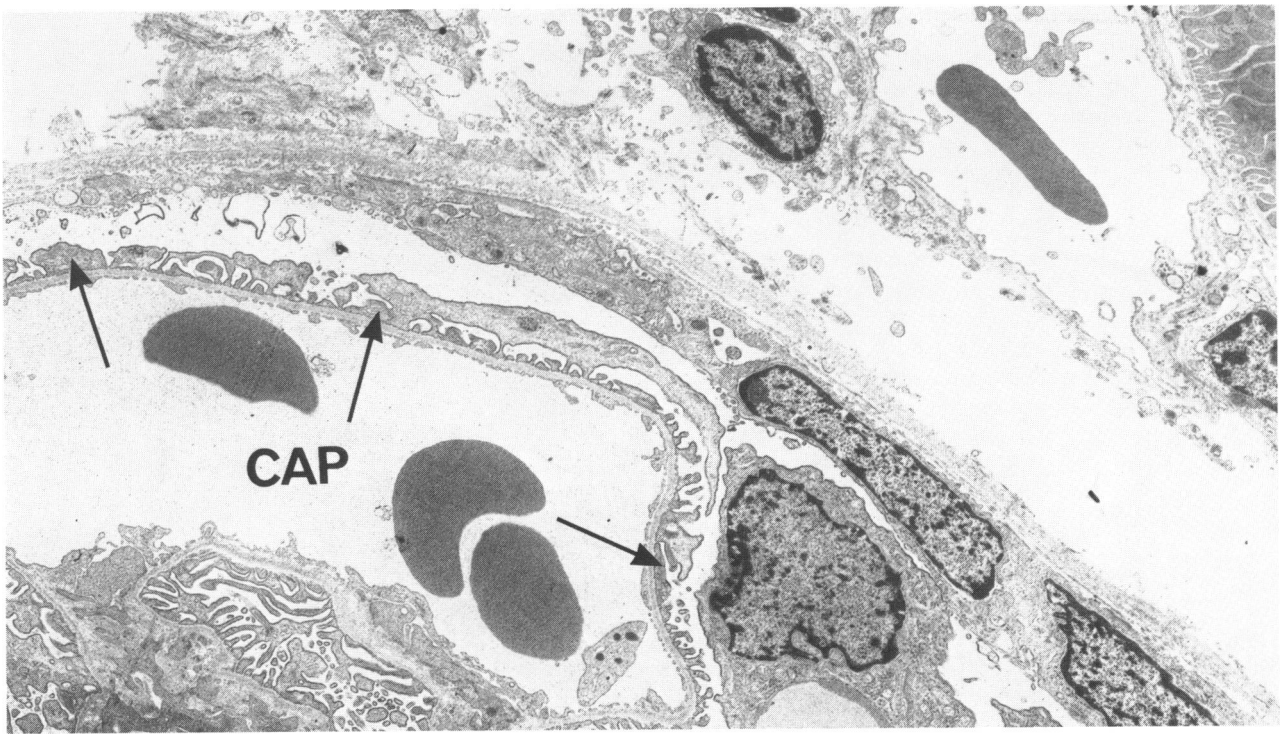

FIGURE 11. Low power transmission electron micrograph showing part of a glomerulus with small areas of foot process fusion (arrowed) and a platelet in a capillary (CAP). The adjoining connective tissue has collagen fibers (CT), and there are wide empty spaces close to the blood vessel (BV). A small area of the basal zone of the tubular cell (T) has a normal appearance. Uranyl acetate-lead citrate, ×3000.

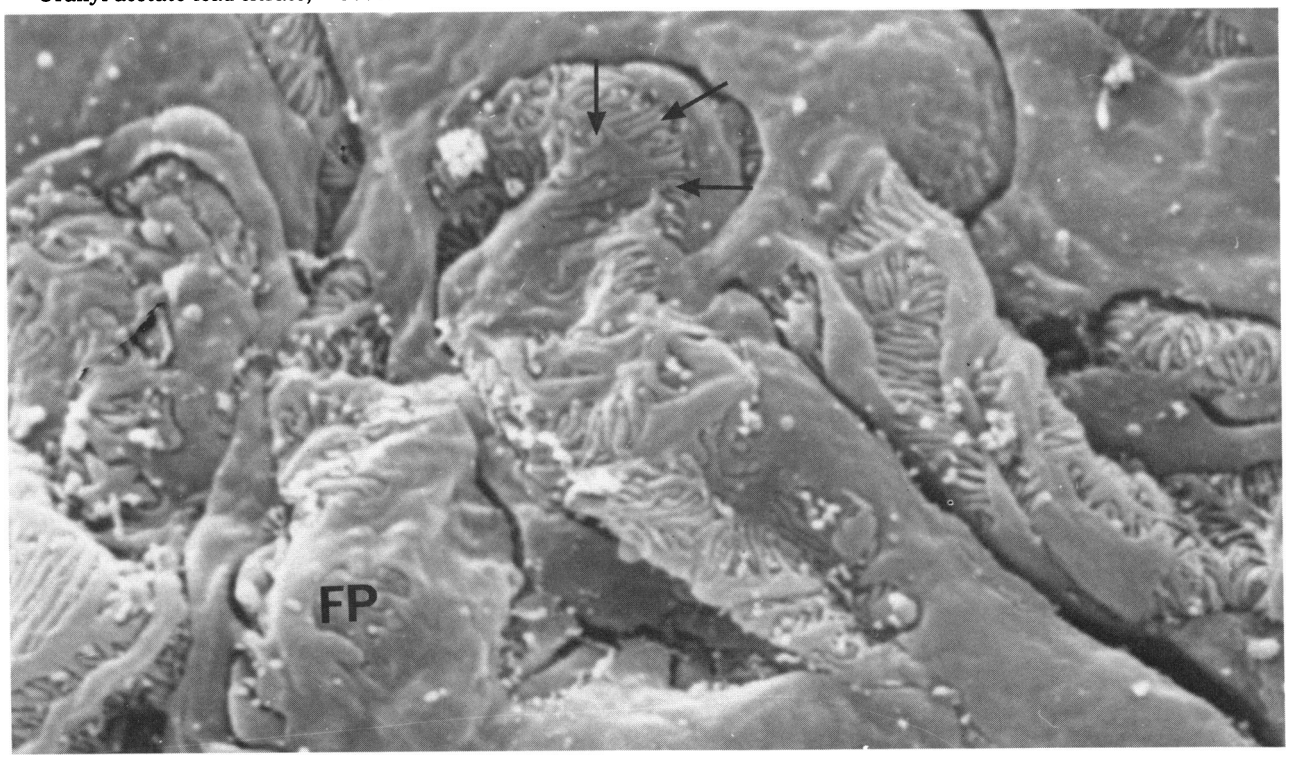

FIGURE 12. Scanning electron micrograph of part of a glomerulus illustrating fusion of foot processes (FP) associated with a bulbous swelling of the terminal parts of some of the foot processes (arrowed). ×2500.

Bernard et al. (*10*) fed 200 ppm Cd to rats in drinking water, and, after 8 months when the Cd concentration in the kidney was around 200 μg/g wet weight, they were able to demonstrate both high and low molecular weight proteinuria indicating both glomerular and tubular lesions.

Our study shows that reproducible lesions are observed in the renal cortex with the presence of protein casts in the medullary tubules at much lower Cd concentrations. While these early cellular injuries may be within the repair capacity of the kidney, the later more obvious lesions at 24 weeks with tubulo-interstitial nephritis may not be reversible. These observations were made in the experimental animal at a renal concentration of 60 μg Cd/g wet weight, which is of the same order as that found in humans who are heavy cigarette smokers (*15*).

The authors thank the Department of the Environment, London, and the Greater Glasgow Health Board (Eastern District), for financial support. The skilled technical assistance of Mrs. Mary Reilly and Mrs. Eileen Harrop in preparing tissue samples for histopathology and chemical analysis is gratefully acknowleded.

REFERENCES

1. Nordberg, G. F. Health hazards of environmental cadmium pollution. Ambio 3 (2): 55–66 (1974).
2. Friberg, L., Piscator, M., Nordberg, G. F., and Kellström, T. In: Cadmium in the Environment, 2nd ed. CRC Press, Cleveland, Ohio, 1974.
3. Task Group on Metal Toxicity. Effects and dose-response relationships of toxic metals. (G. F. Nordberg, Ed.), Elsevier, Amsterdam, 1976, p. 3.
4. Nordberg, M. Studies on metallothionein and cadmium. Environ. Res. 15: 381–404 (1978).
5. Cherian, M. G., Goyer, R. A., and Richardson, L. D. Cadmium-metallothionein-induced nephropathy. Toxicol. Appl. Pharmacol. 38: 399–408 (1976).
6. Suzuki, K. T., Takenaka, S., and Kubota, K. Fate and apparent toxicity of metallothioneins with differing cadmium-zinc ratios in rat kidney. Arch. Environ. Contam. Toxicol. 8: 85–95 (1979).
7. Decker, L. E., Byerrum, R. U., Decker, C. F., Hoppert, C. A., and Langham, R. F. Chronic toxicity studies I. Cadmium administered in drinking water to rats. Arch. Ind. Health, 18: 228–231 (1958).
8. Loeser, E., and Lorke, D. Semichronic oral toxicity of cadmium A. Studies on rats. Toxicology 7: 215–224 (1977).
9. Sabbioni, E., Marafante, E., Amantini, L., Ubertalli, L., and Pietra, R. Metabolic patterns in rats exposed to present environmental dietary levels of cadmium for two years. Sci. Total Environ. 10: 135–161 (1978).
10. Bernard, A., Lauwerys, R., and Gengoux, P. Characterization of the proteinuria induced by prolonged oral administration of cadmium in female rats. Toxicology 20: 345–357 (1981).
11. Aughey, E., Scott, R., Fell, G. S., and Cunningham, C. Rat blood cadmium levels and early renal lesions. In: Trace Element Metabolism in Man and Animals (J. McC. Howell, J. M. Gawthorne and C. L. White, Eds.), Australian Academy of Science, Canberra, 1981, pp. 453–456.
12. Stoeppler, M., and Brandt, K. Determination of lead and cadmium in whole blood by electrothermal atomic absorption spectroscopy. In: Diagnosis and Therapy of Porphyrins and Lead Intoxication (M. Doss, Ed.), Springer-Verlag, Heidelberg, 1978, pp. 185–187.
13. Michel, R. G., Hall, M. L., Ottoway, J. M., and Fell, G. S. Determination of Cd in blood and urine by F.A.F.S. Analyst 104: 491–504 (1977).
14. Roels, H., Bernard, A., Buchet, J. P., Garet, A., Lauwerys, R., Chetile, D. R., Harvey, T. C., and Al-Haddad, I. Critical concentration of cadmium in renal cortex and urine. Lancet i: 221 (1979).
15. Scott, R., Aughey, E., Reilly, M., Cunningham, C., McLelland, A., and Fell, G. S. The cadmium content of human kidneys. In: Trace Element Metabolism in Man and Animals. (J. McC. Howell, J. M. Gawthorne and C. L. White, Eds.), Australian Academy of Science, Canberra, 1981, pp. 4445–4449.