Environmental Health Perspectives
Vol. 65, pp. 279-291, 1986

Tumor-Initiating and Promoting Activities of Di(2-ethylhexyl) Phthalate *in Vivo* and *in Vitro*

by J. M. Ward,* B. A. Diwan,* M. Ohshima,* H. Hu,* H. M. Schuller,*† and J. M. Rice*

The carcinogenic effects of di(2-ethylhexyl) phthalate (DEHP), including its potential as an initiator and as a promoter of carcinogenesis, were studied in mouse liver and skin and in rat liver *in vivo*, and in mouse epidermis-derived JB6 cells *in vitro*. A mouse model for liver initiation and promotion involved initiation by injection of *N*-nitrosodiethylamine (DEN) intraperitoneally into male B6C3F$_1$ mice at 4 weeks of age, followed by exposure to either DEHP in the diet (3000, 6000, or 12,000 ppm) or phenobarbital in the drinking water (500 ppm), beginning 1 to 2 weeks later and continuing for periods of from 1 day to 18 months. Female F344/NCr rats were subjected to a similar protocol in which promotion continued for 14 weeks. DEHP promoted focal hepatocellular proliferative lesions (FHPL), including hyperplastic foci and neoplasms initiated by DEN in mice but not in rats. Skin-painting studies in female CD-1 or SENCAR mice involved initiation by a single topical exposure to 7,12-dimethylbenz[a]-anthracene (DMBA) applied to the dorsal skin, followed by repeated percutaneous exposure to a tumor promoter, either DEHP or 12-*O*-tetradecanoylphorbol-13-acetate (TPA). To test for two-stage skin tumor promotion, SENCAR mice were initiated with DMBA and then TPA was administered for only 2 weeks, after which DEHP was subsequently administered for 26 weeks. DEHP displayed very weak complete promoting activity and definite second stage promoting activity in SENCAR mouse skin, but was inactive under our conditions on CD-1 mouse skin. *In vitro* promoting activity of DEHP and its hydrolysis products, mono(2-ethylhexyl) phthalate (MEHP) and 2-ethylhexanol (EH), was studied by using promotable mouse epidermis-derived JB6 cells. DEHP and MEHP promoted JB6 cells to anchorage independence, while EH did not.

Introduction

Di(2-ethylhexyl) phthalate (DEHP), a plasticizer and hepatic peroxisome proliferator (*1–3*), was found to be carcinogenic in U.S. National Toxicology Program carcinogenesis bioassays (*4*), in which it increased the incidence of hepatocellular neoplasms in F344 rats and in B6C3F$_1$ mice. Because DEHP was demonstrated to have no genotoxic activity in bacterial mutagenesis assays or in other *in vitro* assays (*4,5*), the hypothesis was tenable that this compound achieved its biologic effects by acting as a tumor promoter, enhancing the development of naturally occurring or chemically induced hepatocellular tumors of rats or mice. We have used an *in vivo* model for liver tumor initiation and promotion in mice that utilizes *N*-nitrosodiethylamine (DEN) as an initiator in weanling B6C3F$_1$ males (*6,7*), and have adapted the same protocol to weanling female F344 rats. With these systems, we have tested DEHP as a potential initiator of and promoter for hepatocellular tumors *in vivo*.

At least in the mouse skin system, the promotion stage has empirically been subdivided into two distinct components, stage I and stage II, which are qualitatively different from initiation and from each other (*8–10*). Mezerein is only a weak complete promoter, but when given repeatedly (two times per week) after limited exposure to TPA, it induces a significant tumor response in a dose-dependent manner (*9*). To investigate whether DEHP acts as a tumor initiator or as a complete or second-stage tumor promoter in mouse skin, we used an *in vivo* assay utilizing CD-1 and SENCAR mice.

There are few *in vitro* assays for tumor promoters, and only one that is predictive of target cell specificity *in vivo*. This, one of the best characterized cell culture assays, was originally developed to study phorbol esters, and is based on induction by certain substances of transformation of mouse epidermis-derived JB6 cell lines to a neoplastic phenotype, characterized by anchorage inde-

*Laboratory of Comparative Carcinogenesis, Division of Cancer Etiology, and Laboratory of Experimental Therapeutics and Metabolism, Division of Cancer Treatment, National Cancer Institute, Frederick, MD 21701.

†Present address: Department of Veterinary Pathobiology, University of Tennessee, Knoxville, TN 37901.

pendence and tumorigenicity (*11*). Using this system, we tested the promoting abilities of DEHP and its major hydrolysis products, mono(2-ethylhexyl) phthalate (MEHP) and 2-ethylhexanol (EH).

We report that DEHP promotes but appears not to initiate neoplasia in mouse hepatocytes and mouse skin *in vivo* and promotes transformation of JB6 cells *in vitro*, and that MEHP but not EH promotes JB6 cells *in vitro*.

Materials and Methods

Chemicals

The following chemicals were purchased: DEN (Sigma Chemical Co., St. Louis, MO, USA), DEHP (Aldrich Chemical Co., Milwaukee, WI, USA), EH (Aldrich Chemical Co., Milwaukee, WI, USA), dimethylbenzanthracene (DMBA) (Eastman Kodak Co., Rochester, NY), and TPA (C.C.R. Inc., Eden Prarie, MN). DEHP was analyzed by GLC by Dr. Gary Muschik (Program Resources Inc., FCRF, Frederick, MD, USA) and found to be 99% pure. MEHP was synthesized by a slight modification of the method described by Kenyon and Platt (*12*), and was analyzed by FID/GLC and found to be 96% pure. For *in vitro* assays, DEHP was mixed with acetone, while MEHP and EH were dissolved in DMSO.

Tumor Initiation, Promotion, and Carcinogenicity in Mouse Liver

An initiation–promotion system for male $B6C3F_1$ mouse liver previously described by us was used (*6*). In brief, weanling male $B6C3F_1$ mice obtained from the NCI Division of Cancer Treatment, Animal Genetics and Production Program, Frederick, MD, were injected once intraperitoneally at 4 weeks of age with DEN in tricaprylin solution at a dose of 80 mg/kg body weight. Two weeks later mice were placed on diets containing DEHP at 12,000, 6000 or 3000 ppm or given water containing PB at 500 ppm. Appropriate controls were included (Tables 1 and 2). At 2, 4, 6, 8, 10, or 18 months, groups of mice were killed. At selected time periods, hepatic DNA synthesis and mitotic indices of hepatocytes were measured in groups of four to six mice. Tritiated thymidine was injected intraperitoneally (2 μCi/g body weight every 30 min for six injections) and mice were sacrificed 30 min after the last injection.

To test for initiating activity by DEHP, mice received one intragastric dose (25 or 50 g/kg) at 4 weeks of age followed by phenobarbital (PB) continuously from 6 weeks of age. Mice were killed at 6 and 18 months.

DEHP as a Tumor Promoter in Rat Liver

Female F344/NCr rats in groups of 10, 5 weeks of age, were injected intraperitoneally with *N*-nitrosodiethylamine in tricaprylin at a dose of 282 mg/kg. Two weeks later, rats were placed on diets containing 12,000 ppm DEHP or on drinking water containing PB at 500 ppm. After 14 weeks of exposure to the promoter, rats were sacrificed and eight liver sections (two per lobe) were fixed in formalin for histology or in cold 95% ethanol for gamma glutamyl transpeptidase (GGT) histochemistry.

Effectiveness of DEHP and PB as Liver Tumor Promoters after Short-Term Exposure in $B6C3F_1$ Mice

In a more recent experiment, DEHP was fed in the diet at 3000 ppm, or PB was given in the water at 500 ppm for 1, 7, 28, 84, or 168 days, beginning one week after DEN injection at 4 weeks of age (*7*). All mice were killed at 168 days. Additional groups received DEHP or PB for 168 days and were killed 84 days later to observe possible regression of hepatic proliferative lesions.

Pathology

A complete necropsy was performed on all mice. The liver was weighed and examined carefully for gross lesions. Two representative sections were prepared from each lobe (eight sections per mouse) and fixed in formalin for computerized image analysis of hepatic lesions. Focal hepatocellular proliferative lesions (FHPL) included hyperplastic foci, adenomas, and carcinomas and were classified by staining properties to distinguish those that had clear or eosinophilic cytoplasm from those with basophilic cytoplasm (*6,13*). Avidin–biotin peroxidase complex immunocytochemistry was used to localize mouse α-fetoprotein to hepatocytes (*6*). The mean number of FHPL per square or cubic centimeters of liver, and mean areas and volumes of FHPL were determined using an automated system (Videoplan, Zeiss, Inc., New York, NY) and Zeiss stereology software. Appropriate statistical analyses were performed (*6*). Portions of 23 liver nodules were transplanted to the mammary fat pad of weanling male $B6C3F_1$ mice. Quantitative electron microscopic analysis for cytoplasmic peroxisomes, mitochondria, and rough and smooth endoplasmic reticulum, cell and nuclear cross-sectional areas and nuclear/cytoplasmic ratios were performed on representative liver samples fixed in cold glutaraldehyde from normal untreated mice and from mice treated with DEHP or PB, and on liver tumors in mice given DEN followed by DEHP or PB (*14*).

Skin Initiation–Promotion Studies

CD-1 mice initiated by a single topical application of 50 μg DMBA to the dorsal skin received DEHP (98.1 μg in acetone, 0.2 mL total volume) or TPA (10 μg in 0.2 mL acetone) twice weekly for 40 weeks in a routine skin initiation–promotion protocol (*15*). Mice were killed at 40 weeks. To test for second-stage promoting activity, female SENCAR mice were given DMBA once (20 μg), and then TPA (2 μg, twice a week for 2 weeks), followed by DEHP (100 μg, twice weekly), or by TPA, mezerein or acetone weekly for up to 26 weeks (*15*). To test for complete promoting activity by DEHP in SENCAR mice,

Table 1. Promoting activity of DEHP and PB.[a]

Treatment				No. of mice with		
Initiator, mg/kg	Promoter, ppm	Effective no. of mice	Mean survival, months	FHPL, %	Hepatocellular carcinoma, %	Pulmonary metastases, %
DEN	None	10	>18	9 (90)*	3 (0)	0
DEN (80)	DEHP (3000)	10	>18	10 (100)*	10 (100)	2 (20)
DEN (80)	DEHP (6000)	20	>17	20 (100)*	18 (90)	5 (25)
DEN (80)	DEHP (12000)	20	8.7	20 (100)*	11 (55)	2 (10)
None	DEHP (3000)	10	>18	5 (50)*	1 (10)	0
None	DEHP (6000)	10	>18	3 (30)	1 (10)	0
None	DEHP (12000)	10	8.4	0	0	0
DEN (80)	PB (500)	20	>14.8	20 (100)*	15 (75)	3 (15)
None	PB (500)	17	>18	13 (76)*	3 (17)	0
None	None	10	>18	0	0	0

[a] Male $B6C3F_1$ mice, 4 weeks of age, were injected intraperitoneally with DEN in tricaprylin at a dosage of 80 mg/kg. Two weeks later, they were given the promoter for up to 18 months.

*$p < 0.05$ vs. mice receiving no initiator or promoter.

DEHP was given twice weekly after a single dose of DMBA (20 μg).

In Vitro Studies Using JB6 Mouse Epidermal Cells

JB6 cells lines Cl_{41}, Cl_{21}, and R_{219} were used to investigate the promoting ability of DEHP; the Cl_{41} cell line was utilized to determine the promoting ability of MEHP and EH. Cell cultures were grown in monolayer culture in Eagle's Minimum Essential Medium (EMEM) containing 8% fetal calf serum (FCS) and antibiotics as described earlier (*11*). Medium was replaced once a week. JB6 cells were passaged after dissociation with 0.06% trypsin solution, and cultures were always maintained below confluence. JB6 cells were suspended in culture medium containing 0.33% Difco agar at a temperature less than 40°C to which solvent alone, or stock solutions of DEHP ($1.3–51.2 \times 10^{-3}$ M in acetone), MEHP ($1–5 \times 10^{-5}$ M in DMSO), or EH ($4–77 \times 10^{-4}$ M in DMSO) had been added. Concentrations of MEHP were limited by the toxicity of this compound. The suspension of 1.5 mL, containing 10^4 cells and 1.5 μL of test solution per 60 mm Petri dish, was layered over 0.5% agar base. Assays were carried out in duplicate at 10% FCS concentrations. Colonies were counted at 14 days as described previously (*11*).

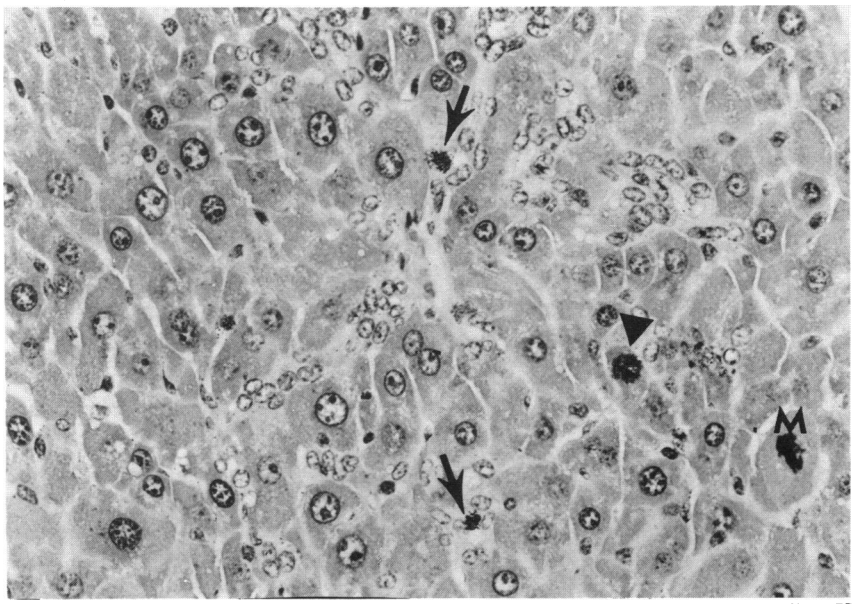

FIGURE 1. Liver of $B6C3F_1$ mouse given DEHP at 12,000 ppm for 4 months and after injection of tritiated thymidine. Hypertrophy of hepatocytes, nuclear pleomorphism, eosinophilia of hepatocyte cytoplasm, mitotic figure (m), labeling of hepatocyte nuclei (arrowhead) and oval cells (arrows). H&E, × 330.

Results

Toxicity of DEHP in Male B6C3F$_1$ Mice

Mice given DEHP suffered obvious toxicity, including a dose-related depression of body weight gain. Death within 3 days after dosing was seen in 4/50 (8%) to 5/20 (25%) of the mice that received one intragastric dose of DEHP at 50 g/kg, but not in those that received a dose of 25 g/kg (0/70). Lesions found by histologic examinations in dead mice included hepatic lipidosis. Mice that received DEHP at 12,000 ppm in the diet weighed only one-half as much as controls by 16 weeks (*6*). Mean body weight in mice that received 3000 and 6000 ppm DEHP was depressed 10% to 20% by 24 weeks. Death occurred from chronic DEHP ingestion only among mice that received 12,000 ppm (Table 1).

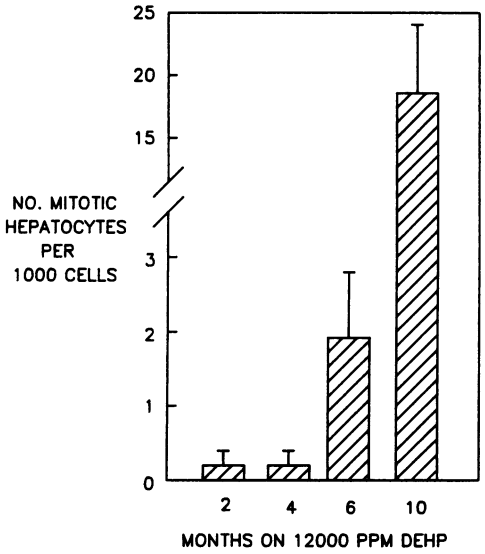

FIGURE 2. Influence of DEHP on hepatocyte replication in livers of male B6C3F$_1$ mice. Mean ± standard error.

Mice sacrificed at 2, 4, 6, 8, 10, or 18 months and those that died between 1 and 18 months had several types of hepatic lesions induced by DEHP. Severity of hepatic lesions was roughly proportional to increased liver weight as a percentage of body weight. Marked eosinophilia of hepatocyte cytoplasm, increased hepatocyte size, mitotic figures (Figs. 1 and 2), oval cell hyperplasia, and pigmented macrophages were seen in mice that received 12,000 ppm DEHP. Quantitative ultrastructural analysis of liver sections revealed differences in organelles between mice given DEHP and those given PB (Figs 3*a*, 3*b*). These included increased peroxisomes in hepatocytes of mice given DEHP, and increased smooth endoplasmic reticulum in nonneoplastic hepatocytes of mice given PB. Cell and cytoplasmic cross-sectional areas were significantly increased in mice that received DEHP (Table 2). The mitotic index was dose and time-associated (Fig. 2). After 4 months of DEHP exposure, hepatocyte labeling indices after injection of tritiated thymidine were as follows (labeled nuclei per 1,000 hepatocytes ± SE): control, 0; DEHP, 12,000, 2.4 ± 1.5; DEHP, 6,000, 0.4 ± 0.2; DEHP 3,000, 1.8 ± 1.1; PB, 0. Oval cells in areas of oval cell hyperplasia were also labeled (Fig. 1). Ne-

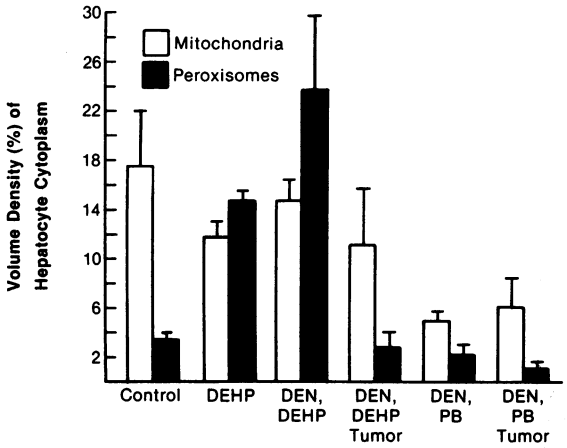

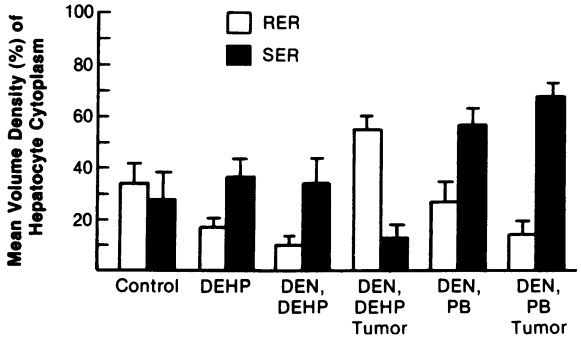

FIGURE 3. Quantitative ultrastructural analysis of cellular organelles in male B6C3F$_1$ mice injected with DEN (80 mg/kg) at 4 weeks of age and/or given either DEHP in the diet (12,000 ppm) for 6–8 months or PB in drinking water (500 ppm) for 8 months. For each lesion, 100–200 electron micrographs were evaluated using area analysis, point count analysis, and stereology. Mean ± standard deviation; RER, rough endoplasmic reticulum; SER, smooth endoplasmic reticulum.

Table 2. Image analysis of hepatocyte cell area, nuclear area, and nuclear/cytoplasmic ratio in B6C3F$_1$ mice exposed to DEHP for 8 months.

Group	Cell area, μm^2[a]	Nuclear area, μm^2[a]	Cytoplasmic area μm^2[a]	Nuclear/cytoplasmic ratio
Control	523.6 ± 198.5	79.0 ± 28.6	444.6 ± 169.9	0.18
DEHP (12,000 ppm)	1065.9 ± 280.9*	119.3 ± 36.2	946.7 ± 244.7*	0.13

[a] Mean ± standard deviation.
*p <0.01 compared with controls.

Table 3. Tumor-initiating activity of DEHP in male B6C3F1 mice.[a]

Treatment		6 months		18 months	
Initiator (g/kg)	Promoter (ppm)	FHPL (%)[b]	FHPL/cm^2	FHPL (%)[b]	Hepatocellular carcinoma (%)
DEHP (50)	None	1/10 (10)	0.04 ± 0.03	2/7 (28)	0/7 (0)
DEHP (50)	PB (500)	0/10 (0)	0	14/15 (93)	2/15 (13)
DEHP (25)	None	0/10 (0)	0	4/10 (40)	1/10 (10)
DEHP (25)	PB (500)	0/10 (0)	0	19/20 (95)	2/20 (10)
None	PB	0/10 (0)	0	13/17 (76)	3/17 (17)
None	None	0/10 (0)	0	0/10 (0)	0/10 (0)

[a] Male B6C3F1 mice, 4 weeks of age, were given one intragastric dose of DEHP at 50 or 25 g/kg. Two weeks later they were given PB at 500 ppm in drinking water, which was continued for 6 or 18 months.
[b] Number of mice with lesion/number of mice in group.

crosis of single hepatocytes was seen only after several months of exposure at the highest dosage level.

Renal lesions included tubular degeneration, necrosis and regeneration with cystic hyperplasia. Renal tubular lesions were dose- and time-related. They were severe enough in mice given 12,000 ppm to contribute to ill health and death after 6 months. In mice injected with tritiated thymidine, regenerative tubular cells were labeled. Degeneration of testicular seminiferous tubules was seen early in mice that received the highest dose, but only at 18 months in some mice that received 6000 ppm. No lesions were seen in thyroid or pituitary glands.

Liver Tumor Initiation and Carcinogenesis by DEHP in Mice

There was no evidence of liver tumor initiation by DEHP after 6 or 18 months of subsequent exposure to the liver tumor promoter, PB. A slight, but not significant, increased incidence of FHPL was seen at 18 months (Table 3). Focal hepatocellular proliferative lesions (FHPL) including tumors were, however, found in some mice after a single intragastric dose of DEHP or continuous dietary exposure for up to 18 months while no tumors or FHPL were found in untreated control mice (Table 3). PB, by itself, caused a high incidence of FHPL by 18 months. Among these FHPL, many foci were composed of clear cells while adenomas were composed of clear and eosinophilic hepatocytes.

Liver Tumor Promotion by DEHP and PB in Mice

Both DEHP and PB were effective tumor promoters (Table 1, Fig. 4). The FHPL in DEN-initiated mice that received DEHP at 12,000 ppm were significantly larger in mean focus volume at 6 months than those of mice in other groups (Fig. 4). Histologically, these FHPL had increased cell size and more numerous mitotic figures and appeared more potentially malignant than those in mice of other groups, especially the group that received DEN alone (Figs. 5–7). Hepatocellular carcinomas arose within adenomas (Fig. 8) and replaced much of the liver (Fig. 9). By 18 months, 25% of the mice given 6000 ppm

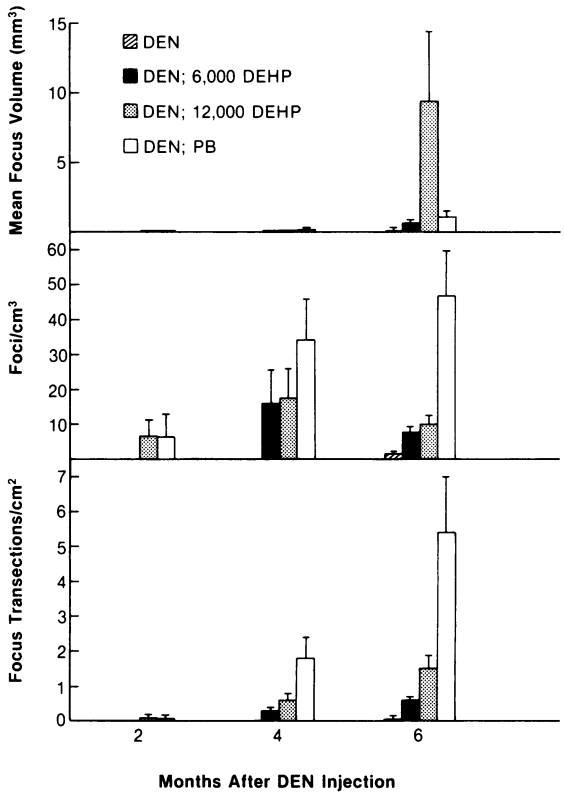

FIGURE 4. Focal hepatocellular proliferative lesions in groups of 10 male B6C3F1 mice injected at 4 weeks of age with DEN (80 mg/kg) and 2 weeks later given dietary DEHP (12,000 or 6000 ppm) or PB (500 ppm) in water for up to 6 months. Mean ± standard error.

DEHP had hepatocellular carcinoma metastatic to the lung. Promoted FHPL, most commonly adenomas and carcinomas, contained hepatocytes with immunoreactive α-fetoprotein (Fig. 10). Eleven of 23 hepatocellular neoplasms (8/12 adenomas, 3/11 carcinomas) in mice that received DEHP or PB after DEN injection were readily transplantable to the mammary fat pad of weanling B6C3F$_1$ mice, appearing at an average of 5.4 months after transplantation. FHPL promoted by DEHP were histologically basophilic (Fig. 4) and ultrastructurally had abundant cytoplasmic rough endoplasmic reticulum,

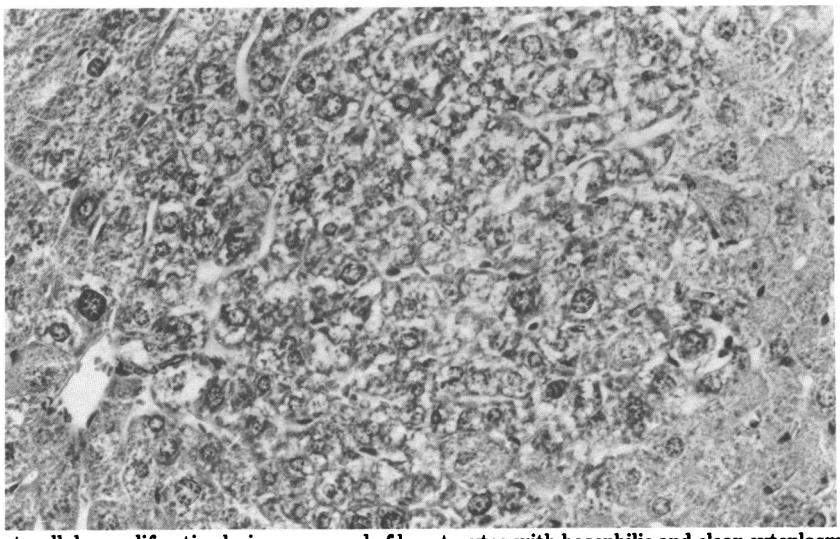

FIGURE 5. Small focal hepatocellular proliferative lesion composed of hepatocytes with basophilic and clear cytoplasm. Mouse injected with DEN and sacrificed at 6 months. H&E, ×330.

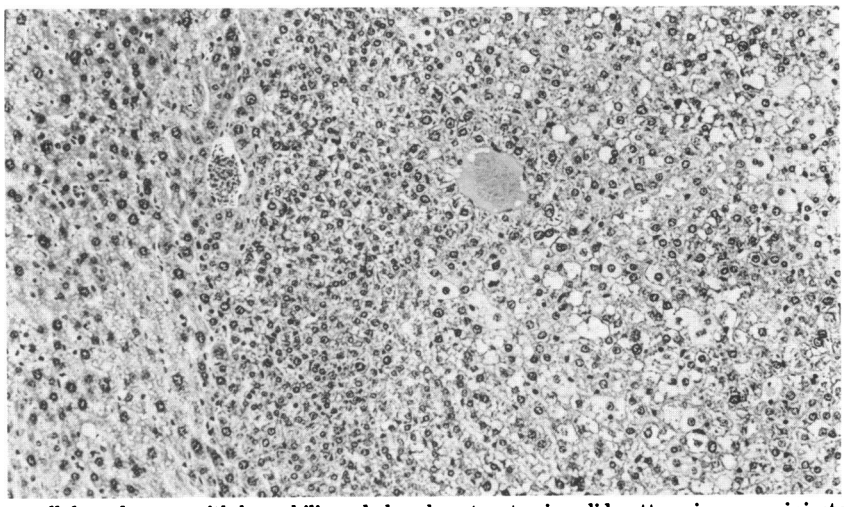

FIGURE 6. Portion of hepatocellular adenoma with basophilic and clear hepatocytes in solid pattern in mouse injected with DEN. H&E, ×130.

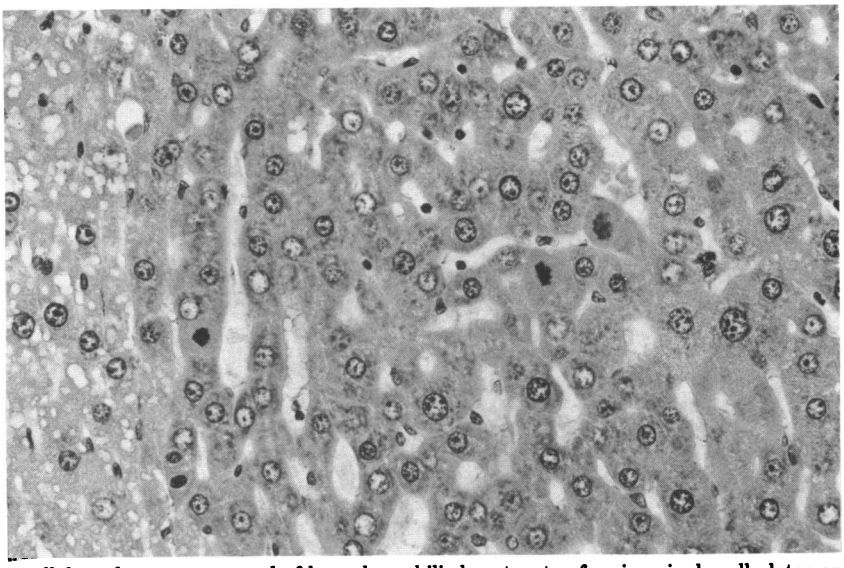

FIGURE 7. Portion of hepatocellular adenoma composed of large basophilic hepatocytes forming single cell plates and with mitotic figures, in a mouse given a single injection of DEN followed by DEHP (12,000 pm) for 10 months. H&E, × 54.

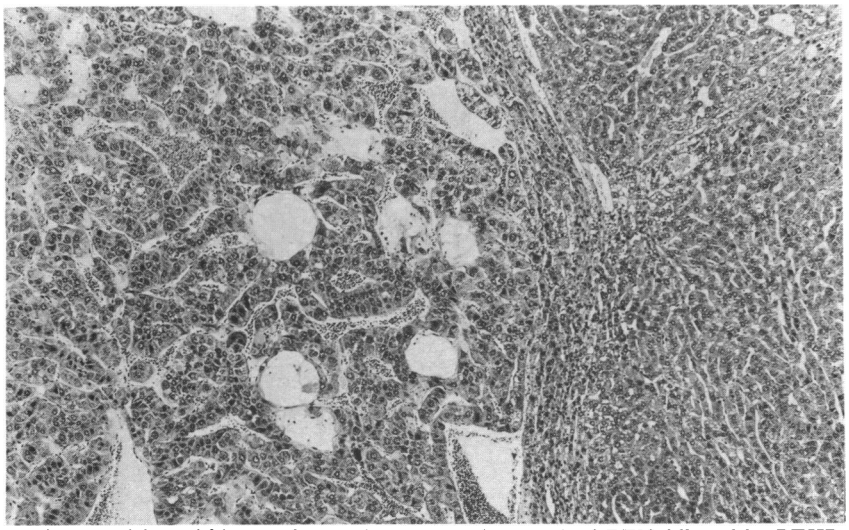

FIGURE 8. Hepatocellular carcinoma arising within an adenoma in a mouse that received DEN followed by DEHP (6000 ppm) for 18 months. H&E, ×54.

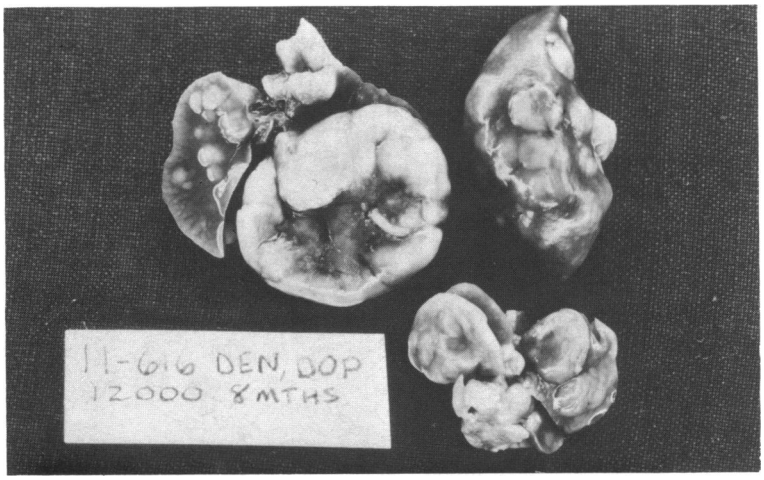

FIGURE 9. Hepatocellular adenomas and carcinomas in the liver of a mouse injected with DEN at 4 weeks of age and then fed diet containing DEHP for 8 months.

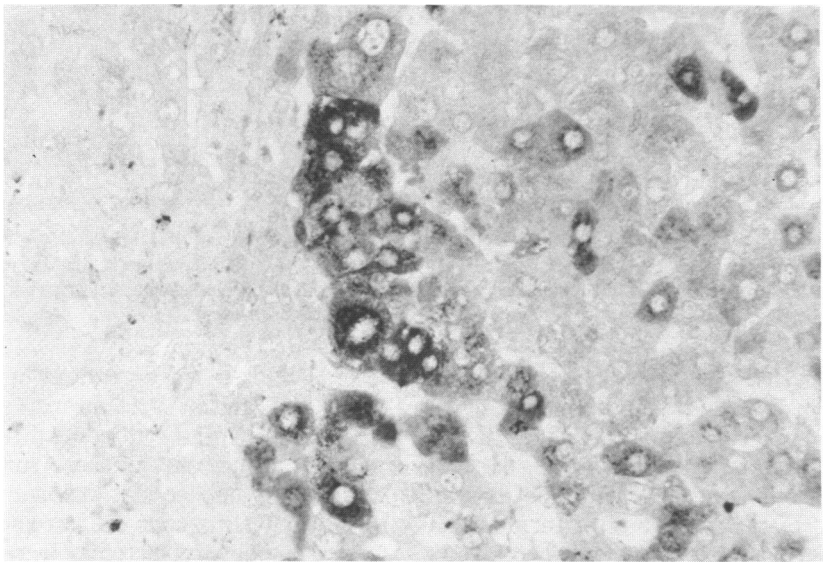

FIGURE 10. Avidin–biotin peroxidase complex immunocytochemistry showing α-fetoprotein in a hepatocellular adenoma of a mouse injected with DEN (80 mg/kg) at 4 weeks of age and then fed diet containing DEHP (12,000 ppm) for 10 months. Hematoxylin, ×330.

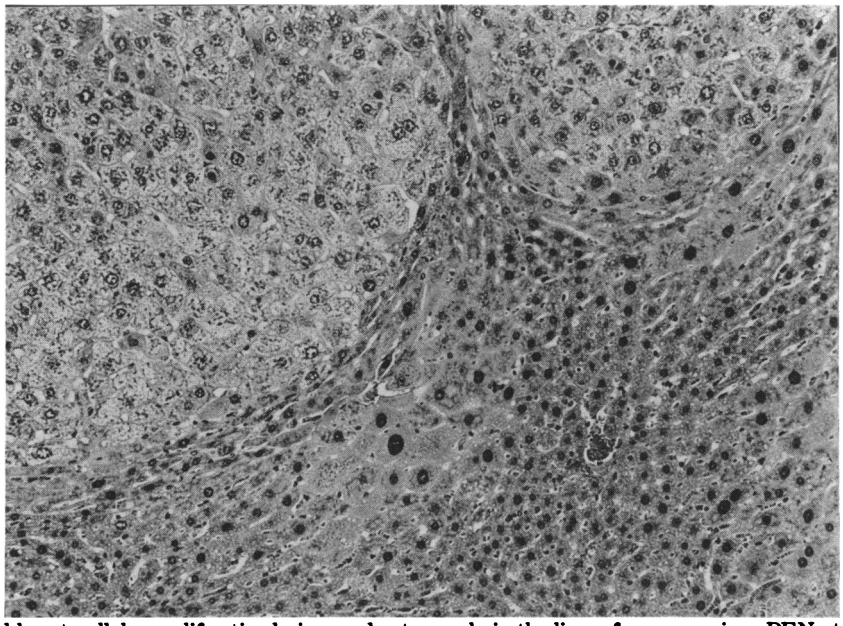

FIGURE 11. Eosinophilic focal hepatocellular proliferative lesions and cytomegaly in the liver of a mouse given DEN at 4 weeks and then dosed with PB, beginning 2 weeks later and continuing for 6 months. H&E, ×130.

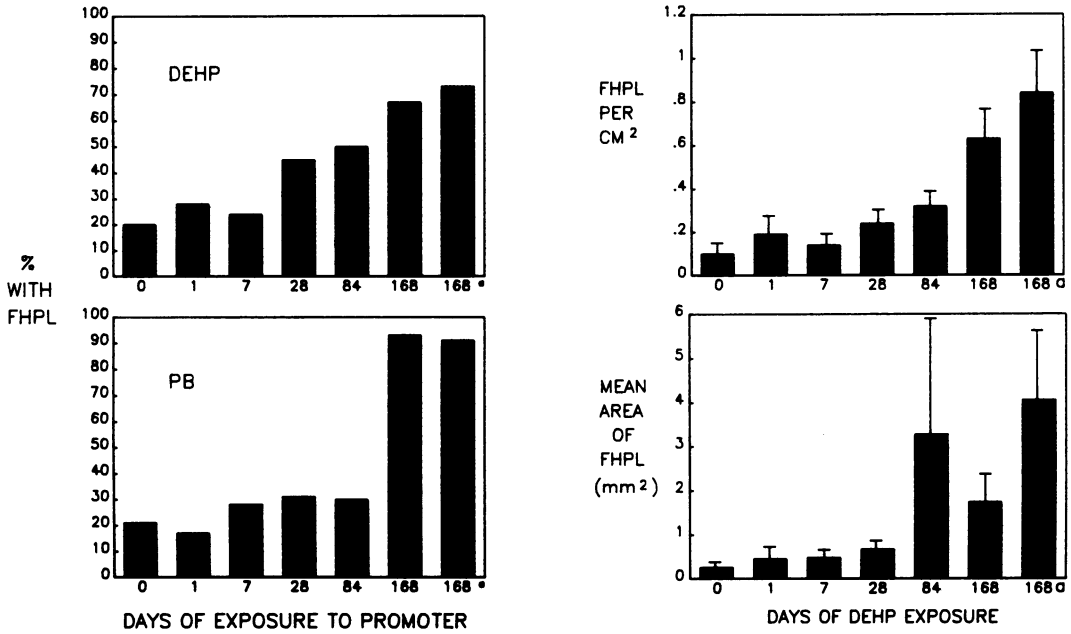

FIGURE 12. Focal hepatocellular proliferative lesions (FHPL) in male B6C3F1 mice injected at 4 weeks of age with DEN (80 mg/kg) and then given DEHP (3000 ppm) in the diet or PB (500 ppm) in the water for 1, 7, 28, 84 or 168 days. An additional group was maintained for an additional 84 days without exposure to DEHP or PB. Lesions include hyperplastic foci, adenomas and carcinomas: (*A*) Percentage with FHPL. (*B*) Lesions per cm^2 ± standard error and mean area of lesions ± standard error.

while those promoted by PB were composed of eosinophilic hepatocytes (Fig. 11) and had abundant cytoplasmic smooth endoplasmic reticulum (Fig. 3*b*). DEHP was an effective liver tumor promoter after 28, 84, and 168 days while PB was effective only after 168 days of exposure (Figs. 12*a*, 12*b*). At 84 days after termination of the most prolonged period of exposure (168 days), however, FHPL in mice given either PB or DEHP had not regressed and in fact had increased in size.

Lung tumors were induced by DEN in all groups of mice. The incidence of these tumors appeared not to be affected by subsequent exposure to either DEHP or PB (*7*). A few squamous cell carcinomas of the forestomach and a few hepatoblastomas were found in DEN-exposed

Table 4. Effectiveness of hepatocellular tumor promoters on unusual tumors of mice injected with DEN or given DEHP intragastrically 18 months previously.[a]

Treatment		Forestomach	
Initiator (mg/kg)	Promoter (ppm)	papilloma or carcinoma	Liver hepatoblastoma
DEN (80)	None	1/10	0/10
DEN (80)	DEHP (6000)	1/20	2/20
DEN (80)	DEHP (3000)	3/10	0/10
DEHP (50,000)	PB (500)	1/15	0/15
DEN (80)	PB (500)	0/20	5/20
None	PB (500)	0/17	0/17
None	None	0/10	0/10

[a] Male $B6C3F_1$ mice, 4 weeks of age, were injected intraperitoneally with DEN in tricaprylin at a dosage of 80 mg/kg. DEHP was given intragastrically at 50 g/kg. Two weeks later promoter exposure was started. Lesions were not seen in mice of other groups.

mice; neither of these neoplasms were significantly affected by DEHP or PB (Table 4).

Liver Tumor Promotion in F344/NCr Rats

Both standard hematoxylin/eosin histology and histochemical staining for gamma glutamyl transpeptidase were used to identify FHPL in liver sections from DEN-initiated rats. DEHP failed to increase the number or size of FHPL detected by either method in rat liver after 16 weeks, while PB was significantly effective at the same doses used in mice (Fig. 13). Liver weights were higher (6% of body weight) in rats that received DEHP than in controls (3.9%). The FHPL in DEN and DEN-DEHP rats were morphologically similar and composed of clear cells, while those that received PB were composed of hepatocytes with eosinophilic, clear and/or vacuolated cytoplasm. Hepatocytes in livers of rats treated with DEHP were enlarged and contained prominent eosinophilic cytoplasm, evidence of peroxisomal proliferation. Renal lesions were not seen in rats.

Skin Tumor Promotion in Mice

DEHP did not promote the development of skin tumors after DMBA initiation in CD-1 mice (Table 5) nor was it

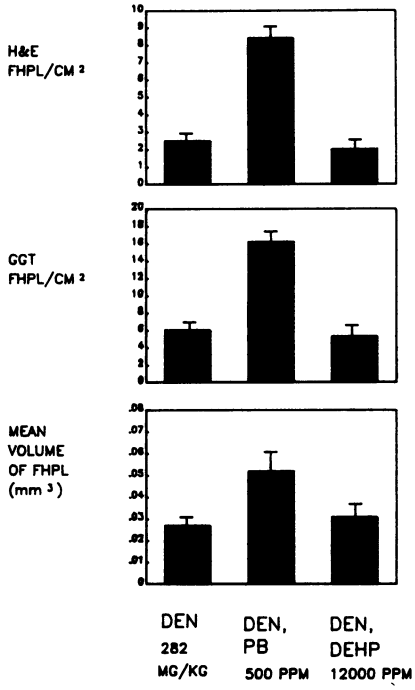

FIGURE 13. Focal hepatocellular proliferative lesions (FHPL) in female F344 rats after a single intraperitoneal injection of DEN (282 mg/kg) at 5 weeks of age followed by DEHP (12,000 ppm) or PB (500 ppm) beginning 2 weeks later and continuing for 14 weeks. Mean ± standard error.

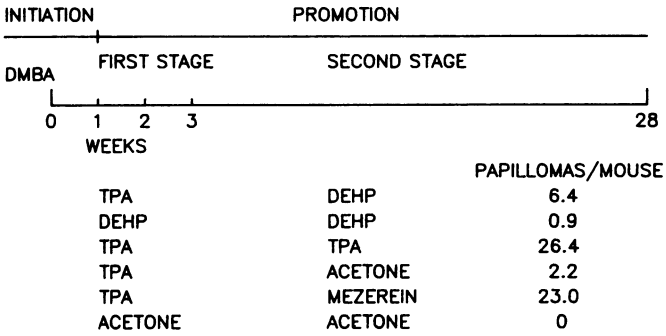

FIGURE 14. Skin tumor promoting activities of TPA, mezerein and DEHP in female SENCAR mice. Methods given by Diwan (*15*).

Table 5. Two-stage carcinogenesis in CD-1 mice.[a]

Groups (30 mice/group)	Treatment	Cumulative total no. of papillomas	Cumulative no. of papillomas per mouse	Cumulative no. of mice with one or more papillomas	Cumulative percentage of mice with papillomas	Cumulative no. of mice with carcinomas
1	DEHP, DEHP	0	0	0	0	0
2	DEHP, TPA	12	0.40	6	20	0
3	DMBA, DEHP	0	0	0	0	0
4	DMBA, TPA	616	20.50	29	97	1
5	DEHP, acetone	0	0	0	0	0
6	Acetone, TPA	10	0.34	6	20	0
7	DMBA, acetone	2	0.07	2	7	0
8	Acetone, acetone	0	0	0	0	0

[a] Experiment terminated at 40 weeks.

an initiator or complete skin carcinogen after 40 weeks (*15*). In female SENCAR mice, however, DEHP was a weak second-stage promoter and a weaker complete promoter of skin carcinogenesis (Fig. 14) (*15*). Mezerein was a considerably stronger second-stage promoter.

Anchorage Independence Induced in Mouse JB6 Cells

DEHP showed activity for promotion of transformation in three promotable (p+) JB6 clonal lines of mouse epidermis-derived cells (Table 6) (*15*). These lines of JB6 cells, including Cl_{41}, Cl_{21}, and R_{219}, have previously been shown to be promoted by anchorage independence and tumorigenicity by tumor promoting phorbol esters, and also by mezerein, benzoyl peroxide and epidermal growth factor (*11*). Of the three cell lines used, Cl_{41} showed the most pronounced maximum response to DEHP; nearly 32% of cells gave rise to colonies in 10% serum medium in the presence of DEHP at a final concentration of 2.6×10^{-7} M. MEHP, a major hydrolysis product of DEHP, was much more toxic than the parent compound and concentrations above 6×10^{-8} M were found toxic to JB6 cells. MEHP concentrations shown to be effective for promotion ranged from 2 to 5×10^{-8} M (Table 6). However, 2-ethylhexanol (EH), a second hydrolysis product of DEHP, failed to promote transformation (Table 6).

Table 6. Anchorage independence induced in mouse JB6-clone 41 cells.[a]

Chemical	Concentration in medium, moles/L[b]	Colonies per 10^4 cells seeded
DEHP (MW 390.5)	0	48
	1.3×10^{-6}	912
	2.6×10^{-6}	1,104
	13×10^{-6}	2,268
	26×10^{-6}	3,144
	51×10^{-6}	2,820
MEHP (MW 278.3)	1×10^{-8}	134
	2×10^{-8}	336
	3×10^{-8}	480
	4×10^{-8}	348
	5×10^{-8}	288
EH (MW 130.2)	4×10^{-7}	48
	8×10^{-7}	96
	38×10^{-7}	48
	77×10^{-7}	60

[a] Colony counts were performed 14 days after cultures in soft agar were prepared.
[b] Stock solutions of each compound in acetone (DEHP) or DMSO (MEHP, EH) were prepared at 1000 times the concentrations listed. A volume of 5 μL was added to 4.5 mL of cell suspension in soft agar medium, thus diluting the stock solution by a factor of 1000 to the final concentration listed in the table.

Discussion

In our studies, DEHP was shown to be a promoter of hepatocellular tumors initiated by DEN in mice; a second-stage skin tumor promoter and a weak complete skin tumor promoter in SENCAR mouse skin after DMBA initiation; and also an inducer of anchorage independence in promotable mouse epidermis-derived JB6 cells. No initiating activity was demonstrated in mouse liver although a single intragastric exposure and continuous dietary exposure to DEHP led to an increased incidence of liver tumors in mice at 18 months in comparison with untreated controls. Although the number of mice at 18 months was small, the findings are compatible with NTP carcinogenesis studies (*4*).

The possible mechanism(s) of tumor promotion by DEHP is (are) unknown. It has been suggested that peroxisome proliferators as a group may be carcinogenic by a nongenotoxic mechanism (*3,16*). The inhibition of hepatic tumorigenesis by the antioxidants ethoxyquin and 2(3)-*tert*-butyl-4-hydroxyanisole (*17*) and other recent studies have provided some evidence for the role of free oxygen radicals and lipid peroxidation in carcinogenesis by these compounds. Recent work, however, suggests that this mechanism does not apply to DEHP (*5*).

Tumor promotion may result from effects on cellular membranes and/or stimulation of proliferation of cells, including hepatocytes, after exposure to an initiating dose of carcinogen. DEHP has been shown by us and others to produce hepatomegaly, in part due to liver cell

Table 7. Detection of focal hepatocellular proliferative lesions in male $B6C3F_1$ mice.

Initiator	Promoter	% with FHPL (% with adenomas or carcinomas)		
		2 months	6 months	18 months
DEN × 1[a]	None	0	20(3)	90(80)
DEN × 1	DEHP × 1[b]	0	0	ND[c]
DEN × 1	DEHP × 28[b]	0	45(20)	ND
DEN × 1	DEHP continuous[d]	0	90(50)	100(100)
None	DEHP continuous[d]	0	10(10)	30(30)
DEHP × 1[e]	None	0	10(10)	28(0)
None	None	0	0	0
DEN × 1	PB continuous[f]	20 (0)	100(100)	100(100)
None	PB continuous[f]	0	0	76(58)

[a] DEN (80 mg/kg) was injected intraperitoneally once at 4 weeks of age.
[b] 3000 ppm in the diet for 1 or 28 days.
[c] Not done.
[d] 6000 ppm in the diet.
[e] 50 g/kg by gavage once at 4 weeks of age.
[f] 500 ppm in drinking water.

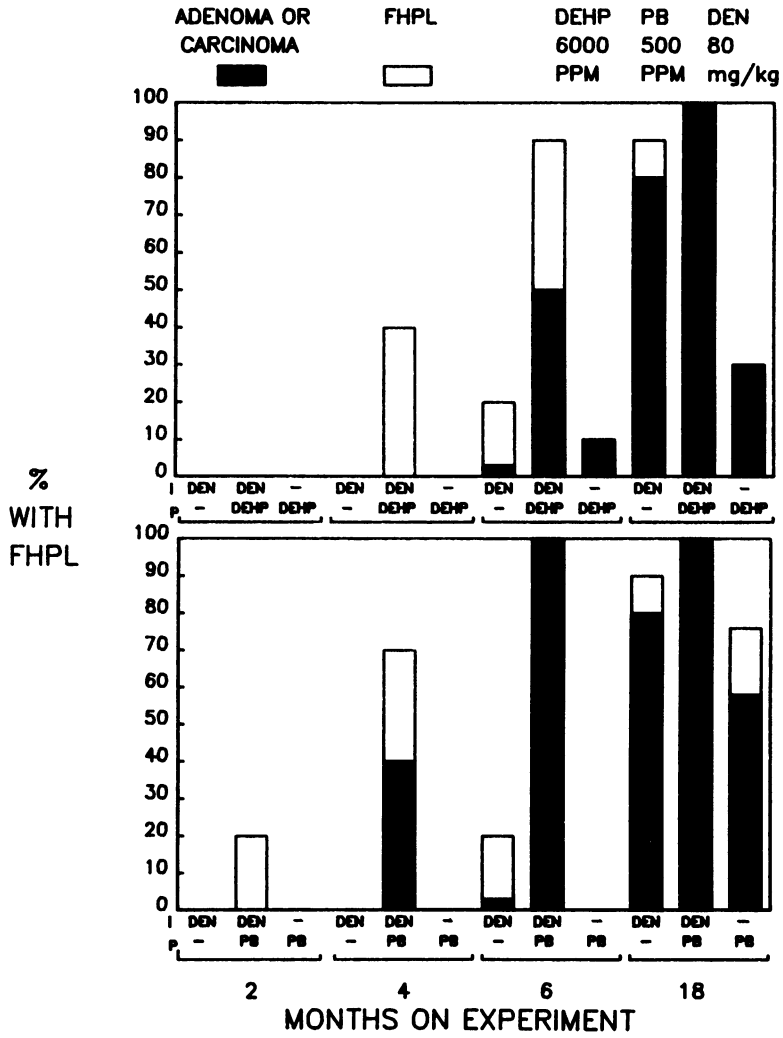

FIGURE 15. Incidence of focal hepatocellular proliferative lesions (FHPL), including hyperplastic foci, hepatocellular adenomas and carcinomas, as a function of duration of exposure to a tumor promoter. DEN (80 mg/kg) was given intraperitoneally at 4 weeks of age as an initiator. DEHP (6000 ppm) or PB (500 ppm) was then given, beginning 2 weeks later and continuing for up to 18 months. The fraction of mice with FHPL is dependent on the duration of exposure to the promoter. I, initiator; P, promoter.

hyperplasia (*3*). Cell proliferation often has been quoted as an important requirement for tumor promotion, although recent studies have demonstrated that liver cell replication per se is not a requirement for tumor promotion by at least some specific chemicals that promote, such as orotic acid (*18–20*). However, much of the hepatomegaly induced by DEHP and by other hepatic peroxisomal proliferators appears to be a consequence of increased size of parenchymal cells. Because DEHP and nafenopin cause peroxisome proliferation in rats but do not cause tumor promotion in rat liver (*21,22*) under conditions identical to those that in mice cause both peroxisome proliferation and tumor promotion, peroxisome proliferation may not be an important factor in liver tumor promotion by DEHP in mice. On the other hand, the demonstration of DEHP as a second-stage skin tumor promoter (*15*) and the increased hepatic focus growth rate and mitotic figure in FHPL in mice given DEHP suggest that liver cell replication can play some role in successful tumor promotion by DEHP. Although DEHP may share some biological effects with other mouse skin tumor promoters including TPA and mezerein, it has recently been shown (P. M. Blumberg, unpublished observations) that any transforming activity in JB6 mouse epidermal cells is not related to the phorbol ester receptor (*23*).

The morphology and biology of liver tumors initiated by DEN in mice were dependent on the subsequent promoter (*6*). DEHP promoted basophilic FHPL that appeared to grow faster and/or appear sooner in the experiment in mice given the highest dose of DEHP. Basophilic adenomas developed from these foci and trabecular carcinomas appeared within the adenomas. The carcinomas metastasized to the lungs in 10 to 25% of the mice. In contrast, eosinophilic FHPL developed in mice receiving PB after DEN. These foci enlarged slowly to form adenomas and finally carcinomas, some of which metastasized to the lungs. As noted previously, the promoter may have affected directly the morphology and

biology of tumor cells in induced tumors (*6*). The evidence for this included the early appearance of basophilic and clear-cell FHPL which resembled those in mice given DEN alone. After these typical foci appeared, DEHP seemed to affect the morphology and mitotic rate of the cells in the FHPL. It is suggested that DEHP increased replication of initiated hepatocytes that appeared morphologically normal and hepatocytes in FHPL that were already morphologically hyperplastic. Thus, the mitogenic effect of DEHP may play an important role in liver tumor promotion (*3,24*). The lack of similar effects on rat liver foci initiated by DEN remains unexplained. It is also possible that DEHP or PB promoted different initiated cell populations in mouse liver, and that as a consequence the morphological and biological properties of FHPL varied for these two liver promoters.

Tumor promotion has been defined by many authors as a reversible process caused by chronic exposure to certain agents, chemicals which are not genotoxic carcinogens but which enhance the appearance, growth, and development of initiated cells or tumors (*8–10*). These processes have been best described in skin and liver. More recent studies have shown that reversibility, in part, depends on the specific chemical and on the duration of exposure. Quantitative estimation of tumors or preneoplastic lesions in mice given initiators or promoters also varies with the dosage given and on the time of sacrifice, and depends on the method of evaluation (Table 7 and Fig. 15). Our recent studies with DEHP provide additional evidence that tumor promotion can be irreversible if exposure time is sufficient. Although classical promoters, themselves, lack genotoxic activity and strong carcinogenic potential, they almost always cause an increased incidence of tumors in a target organ of toxicity. PB and DEHP caused increased incidences of focal hepatocellular proliferative lesions including neoplasms in chronic studies that continued up to 2 years and in which chronic nonneoplastic hepatotoxicity was marked (*4*).

Additional studies are in process in our laboratory on the mechanism of tumor promotion by DEHP.

This study was supported in part by the U.S. PHS contracts N01-CO-12910 and NO1-CP-41014 to Program Resources, Inc., and Microbiological Associates. The skilled assistance of Kathy Breeze, Peter Lynch, Fred Argilan, Rosemary Riggs, Daniel L. Logsdon, Larry Ostby, Dr. Fred Spangler, Debbi Devor, Areitha Smith, Shawn Torboli, and Dan Decker is appreciated. We are grateful to Joyce Vincent for her excellent editorial assistance.

Supported in part by PHS Contracts N01-C0-23910 to Program Resources, Inc., and N01-C0-23912 to Information Management Services, Inc.

REFERENCES

1. Lake, B. G., Gray, T. J. B., Foster, J. R., Stubberfield, C. R., and Gangolli, S. D. Comparative studies on di(2-ethylhexyl) phthalate induced hepatic peroxisome proliferation in the rat and hamster. Toxicol. Appl. Pharmacol. 72: 46–60 (1984).
2. Lake, B. G., Rijcken, W. R. P., Gray, T. J. B., Foster, J. R., and Gangolli, S. D. Comparative studies of the hepatic effects of di- and mono-*n*-octyl phthalates, di-(2-ethylhexyl) phthalate and clofibrate in the rat. Acta Pharmacol. Toxicol. 54: 167–176 (1984).
3. Reddy, J. K., and Lalwani, N. D. Carcinogenesis by hepatic peroxisome proliferators: evaluation of the risk of hypolipidemic drugs and industrial plasticizers to humans. CRC Crit. Rev. Toxicol. 12: 1–58 (1983).
4. Kluwe, W. M., Haseman, J. K., Douglas, J. F., and Huff, J. E. The carcinogenicity of dietary di(2-ethylhexyl) phthalate (DEHP) in Fischer 344 rats and B6C3F1 mice. J. Toxicol. Environ. Health 10: 797–816 (1982).
5. Kornbrust, D. J., Barfknecht, T. R., Ingram, P., and Shelburne, J. D. Effect of di(2-ethylhexyl) phthalate on DNA repair and lipid peroxidation in rat hepatocytes and on metabolic cooperation in Chinese hamster V-79 cells. J. Toxicol. Environ. Health 13: 99–116 (1984).
6. Ward, J. M., Rice, J. M., Creasia, D., Lynch, P., and Riggs, C. Dissimilar patterns of promotion by di(2-ethylhexyl) phthalate and phenobarbital of hepatocellular neoplasia initiated by diethylnitrosamine in B6C3F1 mice. Carcinogenesis 4: 1021–1029 (1983).
7. Ward, J. M., Oshima, M., Lynch, P., and Riggs, C. Di(2-ethylhexyl) phthalate but not phenobarbital promotes *N*-nitrosodiethylamine-initiated hepatocellular proliferative lesions after short-term exposure in male B6C3F1 mice. Cancer Letters 24: 49–55 (1984).
8. Slaga, T. J. Overview of tumor promotion in animals. Environ. Health Perspect. 50: 3–14 (1983).
9. Slaga, T. J., Fischer, S. M., Nelson, K., and Gleason, G. L. Studies on the mechanism of skin tumor promotion: evidence for several stages in promotion. Proc. Natl. Acad. Sci. (U.S.) 77: 3659–3663 (1980).
10. Slaga, T. J., Fischer, S. M., Weeks, C. E., Nelson, K., Mamrack, M., Klein-Szanto, A. J. P. Specificity and mechanism(s) of promoter inhibitors in multistage promotion. In: Carcinogenesis, Vol. 7 (E. Hecker, N. E. Fusenig, W. Kunz, F. Marks, and H. W. Thielmann, Eds.) Raven Press, New York, 1982, pp. 19–32.
11. Colburn, N. H., Former, B. F., Nelson, K. A., and Yuspa, S. H. Tumor promoter induced anchorage independence irreversibly. Nature 281: 589–591 (1979).
12. Kenyon, J., and Platt, B. C. The optical rotatory powers of (+)-γ-methyl-*n*-heptane. J. Chem. Soc. 1939: 633–637.
13. Frith, C. H., and Ward, J. M. A morphologic classification of proliferative and neoplastic hepatic lesions in mice. J. Environ. Pathol. Toxicol. 3: 329–351 (1979).
14. Schuller, H. M., and Ward, J. M. Quantitative electron microscopic analysis of changes in peroxisomes and endoplasmic reticulum induced in mice during hepatocarcinogenesis by diethylnitrosamine promoted by di(2-ethylhexyl) phthalate or phenobarbital. J. Exptl. Pathol. 1: 287–294 (1984).
15. Diwan, B. A., Ward, J. M., Rice, J. M., Colburn, N. H., and Spangler, E. F. Tumor-promoting effects of di(2-ethylhexyl) phthalate in JB6 mouse epithelial cells and mouse skin. Carcinogenesis 6: 343–347 (1985).
16. Upton, A. C., Clayson, D. B., Jansen, J. D., Rosenkranz, H. S., and Williams, G. M. Report of ICPEMC task group 5 on the differentiation between genotoxic and non-genotoxic carcinogens. Mutat. Res. 133: 1–49 (1984).
17. Rao, M. S., Lalwani, N. D., Watanabe, T. K., and Reddy, J. K. Inhibitory effect of antioxidants ethoxyquin and 2(3)-*tert*-butyl-4-hydroxyanisole on hepatic tumorigenesis in rats fed ciprofibrate, a peroxisomal proliferator. Cancer Res. 44: 1072–1076 (1984).
18. Rao, P. M., Nagemine, K., Ho, R. K., Roomi, M. W., Laurier, C., Rajalakshmi, S., and Sarma, D. S. R. Dietary orotic acid enhances the incidence of γ-glutamyltransferase positive foci in rat liver induced by chemical carcinogenesis. Carcinogenesis 12: 1541–1545 (1983).
19. Schulte-Hermann, R., Timmermann-Trosiener, I., and Schuppler, J. Response of liver foci in rats to hepatic tumor promoters. J. Toxicol. Pathol. 10: 63–70 (1982).
20. Abanobi, S. E., Lombardi, B., and Shinozuka, H. Stimulation of DNA synthesis and cell proliferation in the liver of rats fed a choline-devoid diet and their suppression by phenobarbital. Cancer Res. 42: 412–415 (1982).
21. Deangelo, A. B., and Garrett, C. T. Inhibition of development of preneoplastic lesions in the livers of rats fed a weakly carcinogenic environmental contaminant. Cancer Letters 20: 199–205 (1983).
22. Staubi, W., Bentley, P., Bieri, F., Frohlich, E., and Waechter, F.

Inhibitory effect of nafenopin upon the development of diethylnitrosamine-induced enzyme-altered foci within the rat liver. Carcinogenesis 5: 41–46 (1984).
23. Blumberg, P. M., Dunn, J. A., Jaken, S., Jeng, A. Y., Leach, K. L., Sharkey, N. A., and Yeh, E. Specific receptors for phorbol ester tumor promoters and their involvement in biological responses. In: Mechanisms of Tumor Promotion, Volume III. Tumor Promotion and Carcinogenesis In Vitro (T. J. Slaga, Ed.), CRC Press, Boca Raton, FL, 1984, pp. 143–184.
24. Butterworth, B. E., Bermudez, E., Smith-Oliver, T., Earle, L., Cattley, R., Martin, J., Popp, J. A., Strom, S., Jirtle, R., and Michalapoulos, G. Lack of genotoxic activity of di(2-ethylhexyl) phthalate (DEHP) in rat and human hepatocytes. Carcinogenesis 5: 1329–1335 (1984).
25. Bohrman, J. S. Identification and assessment of tumor-promoting and carcinogenic agents: state-of-the-art in vitro methods. CRC Crit. Rev. Toxicol. 11: 121–167 (1982).
26. Pitot, H. C., and Sirica, A. E. The stages of initiation and promotion in hepatocarcinogenesis. Biochim. Biophys. Acta 605: 191–215 (1980).