Environmental Health Perspectives
Vol. 73, pp. 107-113, 1987

Mesovarian Leiomyomas in the Rat

by C. Gopinath* and W. A. Gibson*

Prolonged treatment with two chemically distinct β-stimulants, Salbutamol and Terbutaline, resulted in mesovarian leiomyomas in Sprague-Dawley rats. Development of these tumors induced by Salbutamol was prevented by concurrent administration of the β-blocker Propranolol. Mesovarian leiomyomas induced by Salbutomol did not show any regression or progression during a 44-week postdosing recovery period. This report also gives the first recorded incidence of spontaneous mesovarian leiomyomas in the rat.

Introduction

Primary leiomyomas of the ovaries are uncommon in man; one review recorded only five cases from a collection over a 36-year period (*1*). Smooth muscle cell tumors of the ovaries are likewise rare in all species of animals. We found no reported cases of spontaneous mesovarian leiomyomas in rats in the published literature. In contrast to spontaneously occurring smooth muscle cell tumors, mesovarian leiomyomas can be induced in rats by prolonged administration of β-stimulants.

This report describes the pathologic features and compares the incidence of mesovarian leiomyomas induced in female rats by two β-stimulants, Salbutamol sulfate and Terbutaline sulfate, and shows the effects on the incidence of Salbutamol-induced leiomyomas of concurrent administration of the β-blocker, Propranolol. In addition, results from an extensive review of ovaries from untreated rats are presented.

Materials and Methods

The test animals used were female Charles River CD (Sprague-Dawley derived) rats, and the compounds were administered orally in the diet. The study was divided into two parts. Experimental design for Part I is given in Table 1. Part II of the study consisted of 200 female rats that were given Salbutamol at a dose level of 20 mg/kg/day for 80 weeks. Fifty rats were killed at week 80, and the remaining survivors (98 rats) were held without treatment for a postdosing recovery period up to week 124. At this time all survivors were killed. All animals were given a complete postmortem examination and tissues were fixed in 10% neutral buffered formalin. Only the results of the mesovarian leiomyomas are included in this report. In addition, a retrospective review of ovary tissue diagnoses from 7748 untreated rats in the Huntingdon Research Centre database was conducted to establish the spontaneous incidence of mesovarian leiomyomas.

Table 1. Experimental design (Part I).

Group	Treatment[a]	Dosage equivalent[b]	Rats per group, female
1	Control	—	105
2	Salbutamol (low dose)	2 mg/kg/day	55
3	Salbutamol (high dose)	20 mg/kg/day	55
4	Terbutaline (low dose)	6 mg/kg/day for 62 weeks, then 12 mg/kg/day[c]	55
5	Terbutaline (high dose)	60 mg/kg/day for 62 weeks, then 120 mg/kg/day[c]	55
6	Salbutamol + Propranalol	20 mg/kg/day plus 33 mg/kg/day[d]	55

[a]Rats treated for a total of 104 weeks.
[b]Estimated average amount ingested by each rat based on known food consumption.
[c]The dose of Terbutaline was doubled from week 63 as it was found to give less than intended plasma concentrations in the treated rats (*2*).
[d]The dose of the Propranolol was that found to effectively abolish the increase in heart rate caused by oral Salbutamol in the rat (*2*).

Results

Part I

A summary of the mesovarian smooth muscle lesions observed in Part I of this study is given in Table 2. Both β-stimulants, Salbutamol and Terbutaline (groups 3, 4, and 5), produced mesovarian leiomyomas. There were no rats with leiomyomas among the controls nor in the group given Salbutamol plus Propranolol.

Eighteen of the rats with leiomyomas had grossly detected lesions. Nine of these lesions were located on the right side, six were bilateral, and three were seen

*Huntingdon Research Centre, Huntingdon, Cambridgeshire, PE18, 6ES, England.

Table 2. Incidence of mesovarian smooth muscle lesions.

Group	Treatment	No. of rats examined	No. of rats with macroscopic lesions in mesovarium[a]	No. of rats with mesovarian leiomyomas	No. of rats with smooth muscle hyperplasia
1	Control	105	0	0	0
2	Salbutamol 2 mg/kg/day	55	0	0	2
3	Salbutamol 20 mg/kg/day	55	9	16 (23)[b]	2
4	Terbutaline 6/12 mg/kg/day	55	1	1	0
5	Terbutaline 60/120 mg/kg/day	55	8	7 (9)	2
6	Salbutamol + Propranolol 20 mg + 33 mg/kg/day	55	0	0	0

[a]Macroscopic lesions included swelling, nodules, or masses.
[b]Numbers in parentheses are the total number of leiomyomas observed.

on the left side. These tumors varied from 1 mm to 20 mm in diameter. The earliest appearance of a leiomyoma in this part of the study was at week 56 in a decedent rat from the group receiving Salbutamol at 20 mg/kg/day.

Part II

The incidence of leiomyomas seen in Part II of this study is given in chronological order in Table 3. There were 52 intercurrent deaths during the dosing period (up to 80 weeks), and 50 more rats were killed at 80 weeks. Among these 102 rats, there were 17 rats with mesovarian leiomyomas. During the postdosing recovery period, there were another 22 rats with mesovarian leiomyomas (among the remaining 98), including one which was killed at week 124.

Forty-one of the 200 rats had macroscopic mesovarian lesions present as swellings, nodules, or masses. Twenty-nine of these grossly detected lesions were on the right side, nine were bilateral, and three were on the left side. The earliest appearance of a leiomyoma in this part of the study was at week 63. The lesions varied from 2 mm in diameter to a 29 × 24 × 16 mm irregular mass, the largest tumor. The lesions were located most frequently in the mesovarium extending into the hilar region of the ovary, dorsal to the ovary (Plate 1), and sometimes freely in the mesovarian ligament, up to 12 mm away from the tip of the uterine horn. Macroscopic lesions appeared as fusiform swellings, spherical or ovoid nodules, or as irregular bosselated masses (Plate 2). Cut surfaces revealed dense whitish tissue with a faintly whorled pattern (Plate 3). Lesions were well-circumscribed, but had no distinct encapsulation.

Table 3. Incidence of leiomyomas in rats given Salbutamol for 80 weeks.

Week of death	No. of rats examined	No. of rats with macroscopic mesovarian lesions[a]	No. of rats with mesovarian leiomyomas	No. of rats with smooth muscle hyperplasia
Treatment period				
0–59	11	0	0	0
60–69	19	2	2(2)[b]	2
70–79	22	5	5(6)	3
Interim kill				
80	50	12	10(11)	7
Recovery period				
81–89	18	3	3(5)	1
90–99	26	6	7(7)	0
100–109	23	6	5(7)	0
110–119	17	5	6(7)	0
120–124	14	2	1(1)	0

[a]Macroscopic lesions included swelling, nodules, and masses.
[b]Numbers in parentheses indicate the total number of leiomyomas observed.

Histological Features

Histologically, leiomyomas appeared as well-circumscribed growths of smooth muscle fibers (Plates 4 and 5). The muscle fibers appeared as interlacing bundles, with a criss-crossing pattern and were sometimes arranged in whorls (Plate 6). The muscle cells were long, with abundant eosinophilic cytoplasm and cylindrical, cigar-shaped nuclei with blunt ends (Plate 7). In some of the microscopic fields, the nuclei appeared ovoid or circular depending on the sectioning angle on the bundle of muscle fibers. The tumor cells stained yellow with van Gieson and red with Mason's trichrome. Sparse interbundle collagen was also present in varying proportions.

Irregular areas of smooth muscle tissue in excess of the usual amount found in the mesovarium, the suspensory ligaments, or in the ovarian hilus were diagnosed as smooth muscle hyperplasia. In these instances, although the smooth muscle tissue was focally in excess, the lesions lacked the characteristic patterns of interlacing bundles or whorls seen in the tumors and appeared as areas of irregular or parallel smooth muscle fibers (Plate 8).

The review of the ovaries carried out to establish the occurrence of mesovarian leiomyomas among untreated rats revealed four cases in 7748 rat ovaries examined. These four cases had morphological features identical to those described for the induced tumors described previously.

Discussion

Leiomyomas recorded in this study arose from the smooth muscle normally present in the mesovarium. This muscle tissue extends into the ovarian hilus and anteriorly into the ligaments. None of the tumors examined showed any evidence of malignancy. The tumors tended to occur more frequently on the right side than the left, which was similar to a previous observation (*3*).

Mesovarian leiomyomas were induced in rats by the administration of two chemically distinct adrenergic stimulants, Salbutamol and Terbutaline. Other β-stimulants like Soterenol hydrochloride and Mesuprine hydrochloride are known to induce these tumors in the rat (*3,4*). Two other agonists, Zinterol and Reproterol, were also reported to have induced leiomyomas in the rat (*2*). A 12-month study in rats with high doses of Mabuterol revealed 3 out of 56 rats with mesovarian leiomyomas (*5*).

The induction of mesovarian leiomyomas in rats appears to be a general feature of β-stimulants. That the induction of these benign tumors is a function of adrenergic stimulation was further evidenced by the fact that the concurrent administration of the adrenergic blocker, Propranolol, prevented their development. Mesovarian smooth muscle in the rat is known to contain β_2- adrenoceptors, and it is postulated that prolonged and intense activation of β_2-adrenoceptors that mediate cellular relaxation might give rise to leiomyomas (*6*).

In Part II of this study, female rats treated with Salbutamol 20 mg/kg/day for 80 weeks followed by a postdosing recovery period of 44 weeks had a similar incidence of mesovarian leiomyomas during the treatment and recovery periods. Since these tumors were still detected toward the end of the recovery period, and there were no appreciable differences in the size of the masses detected, it can be concluded that these lesions were neither reversible nor progressive.

Beta-stimulants are known to induce mesovarian leiomyomas in different strains of rats such as Sprague-Dawley derived (Charles River CD strain), pigmented Long Evans, and Wistar derived (Jcl) rats (*2,3,5*). β-stimulants are not known to produce mesovarian leiomyomas in mice or other species of laboratory animals. This class of pharmacological compounds has been extensively used for more than 15 years in man, and there is no evidence of any increased incidence of smooth muscle tumors among users of these drugs (*7*). It is apparent from this report that these tumors in the rat are not unique to β-stimulants but do occur spontaneously, albeit exceptionally rarely.

The authors wish to thank D. Poynter, Glaxo Research Ltd., England, for permission to use results of this experiment carried out at Huntingdon Research Centre. We are grateful to A. Galloway for typing this manuscript and to M. Cannon for the photographic work.

REFERENCES

1. Fallahzadeh, H., Dockerty, M. B., and Lee, R. A. Leiomyoma of the ovary: report of five cases and review of the literature. Am. J. Obstet. Gynecol. 113: 394–398 (1972).
2. Jack, D., Poynter, D., and Spurling, N. W. Beta-adrenoceptor stimulants and mesovarian leiomyomas in the rat. Toxicology 27: 315–320 (1983).
3. Nelson, L. W., and Kelley, W. A. Mesovarial leiomyomas in rats in a chronic toxicity study of Soterenol hydrochloride. Vet. Pathol. 8: 452–457 (1971).
4. Nelson, L. W., Kelley, W. A., and Weikel, J. H. Mesovarial leiomyomas in rats in a chronic toxicity study of Mesuprine hydrochloride. Toxicol. Appl. Pharmacol. 23: 731–737 (1972).
5. Amemiya, K., Koduh, M., Suzuki, H., Saga, and K., Hosaka. Toxicity of Mabuterol. Arzneim Forsch/Drug Res. 34: 1680–1684 (1984).
6. Apperley, G. H., Brittain, R. T., Coleman, R. A., Kennedy, I., and Levy, G. P. Characterization of the β-adrenoceptors in the mesovarium of the rat. Br. J. Pharmacol. 63: 345–398 (1978).
7. Poynter, D., Harris, D. M., and Jack, D. Salbutamol: lack of evidence of tumor induction in man. Br. Med. J. 6104: 46–47 (1978).

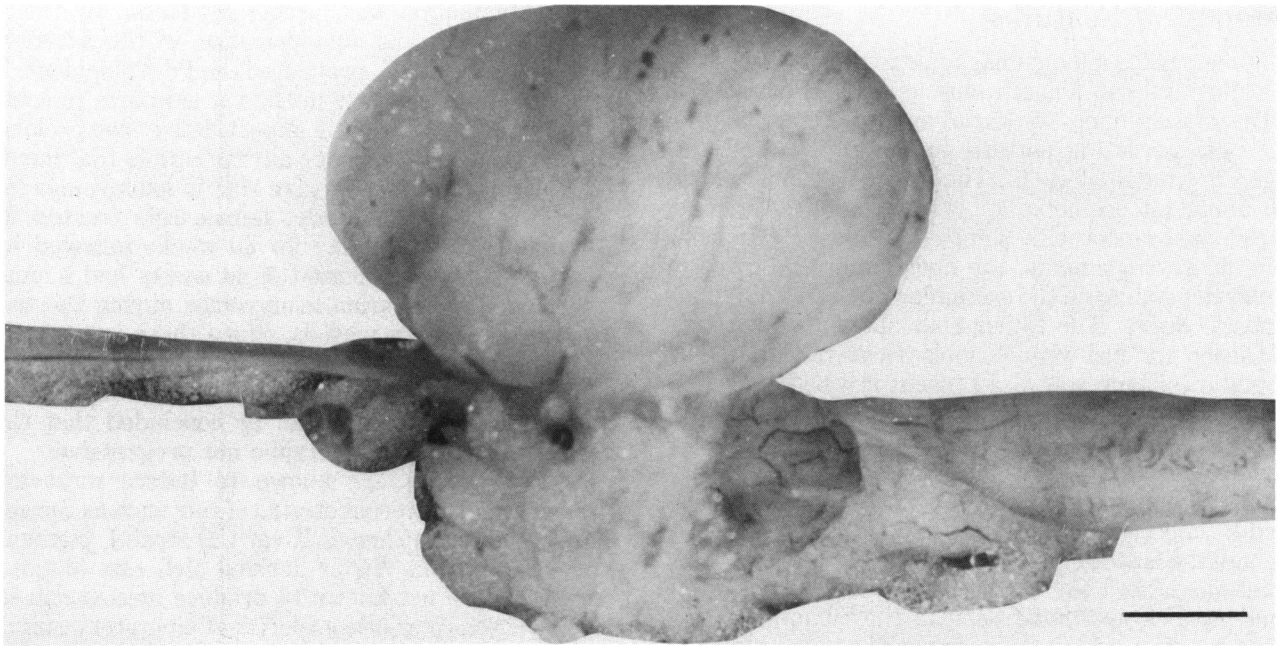

PLATE 1. Mesovarian leiomyoma situated dorsal to the right ovary. Bar = 2 mm.



PLATE 2. A large mesovarian leiomyoma; note the multinodular bosselated appearance. Bar = 5 mm.

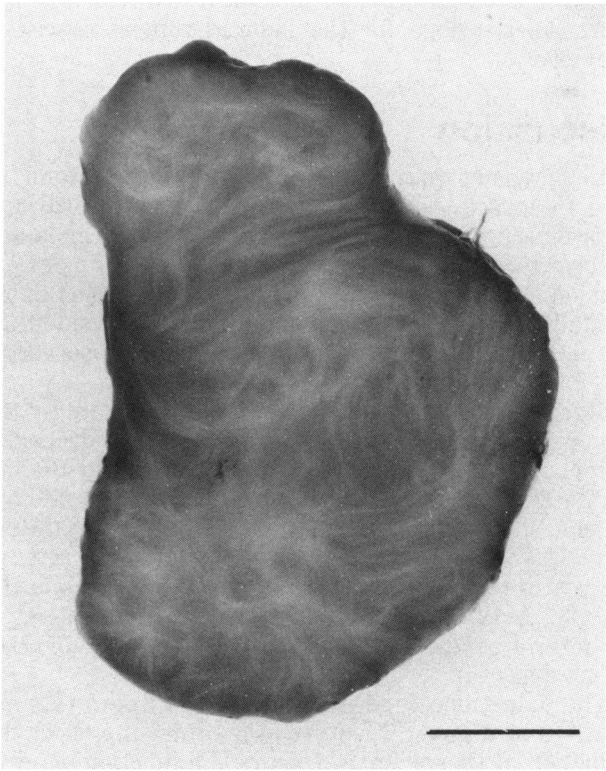

PLATE 3. Mesovarian leiomyoma. Cut surface revealing faint whorled pattern. Bar = 5 mm.

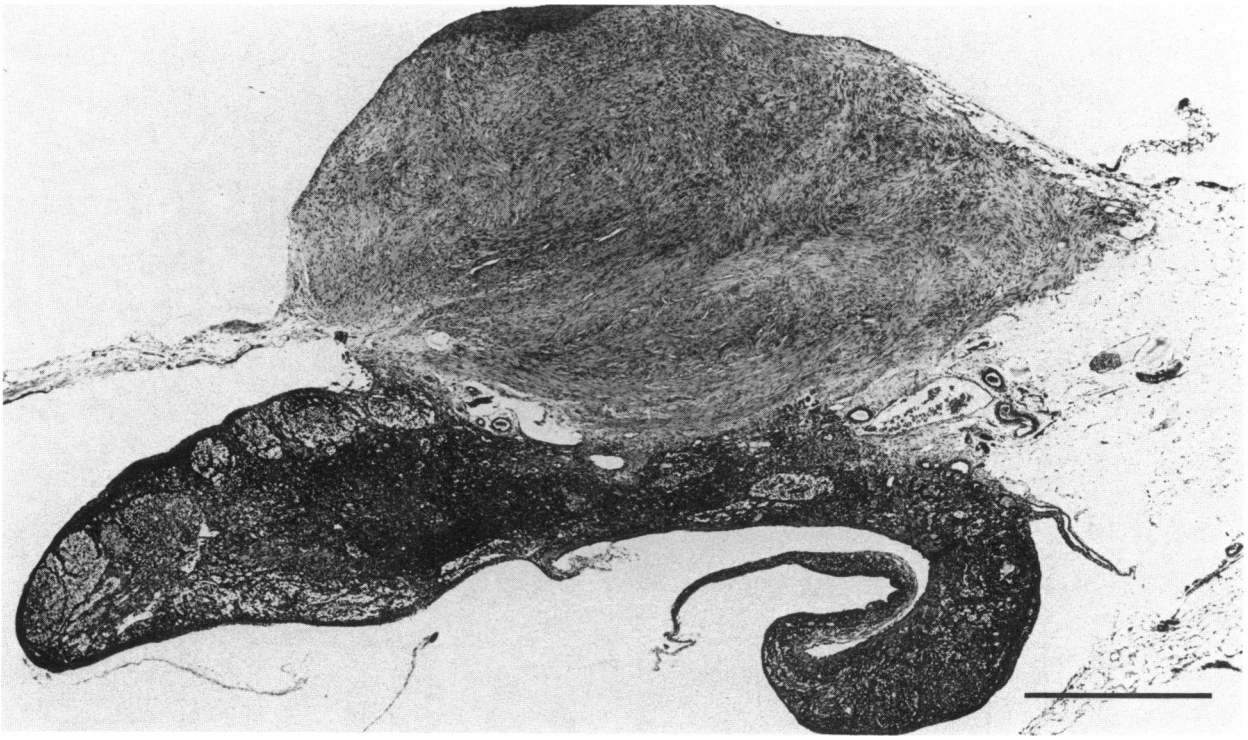

PLATE 4. Mesovarian leiomyoma situated at ovarian hilus. H & E. Bar = 1 mm.

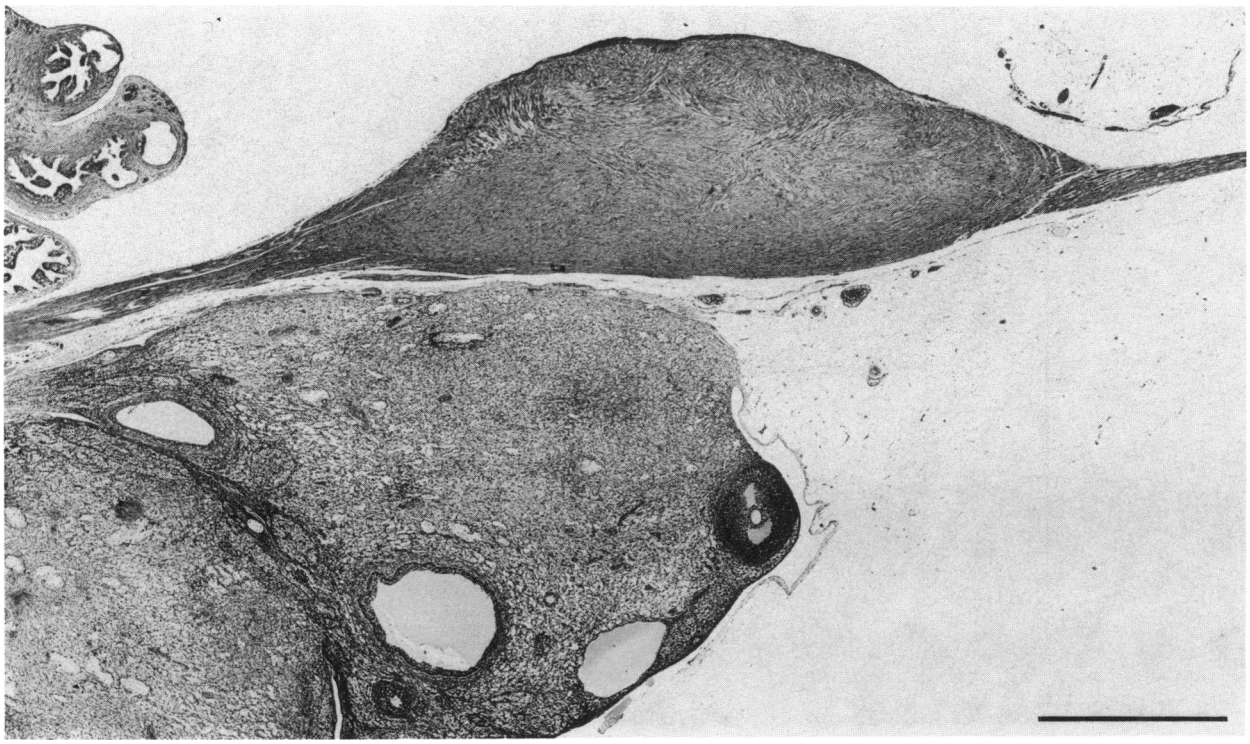

PLATE 5. Mesovarian leiomyoma on the right mesovarian ligament. H & E. Bar = 1 mm.

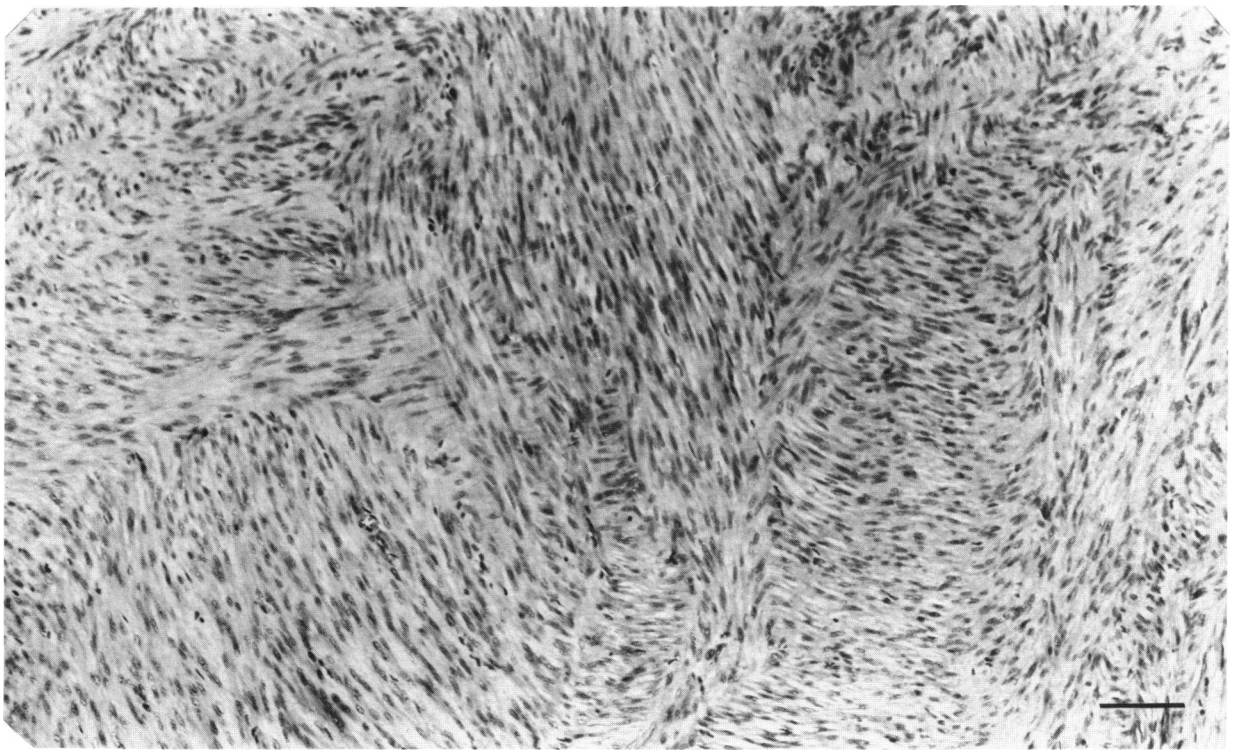

PLATE 6. Mesovarian leiomyoma showing criss-crossing pattern of muscle bundles. H & E. Bar = 100 μm.

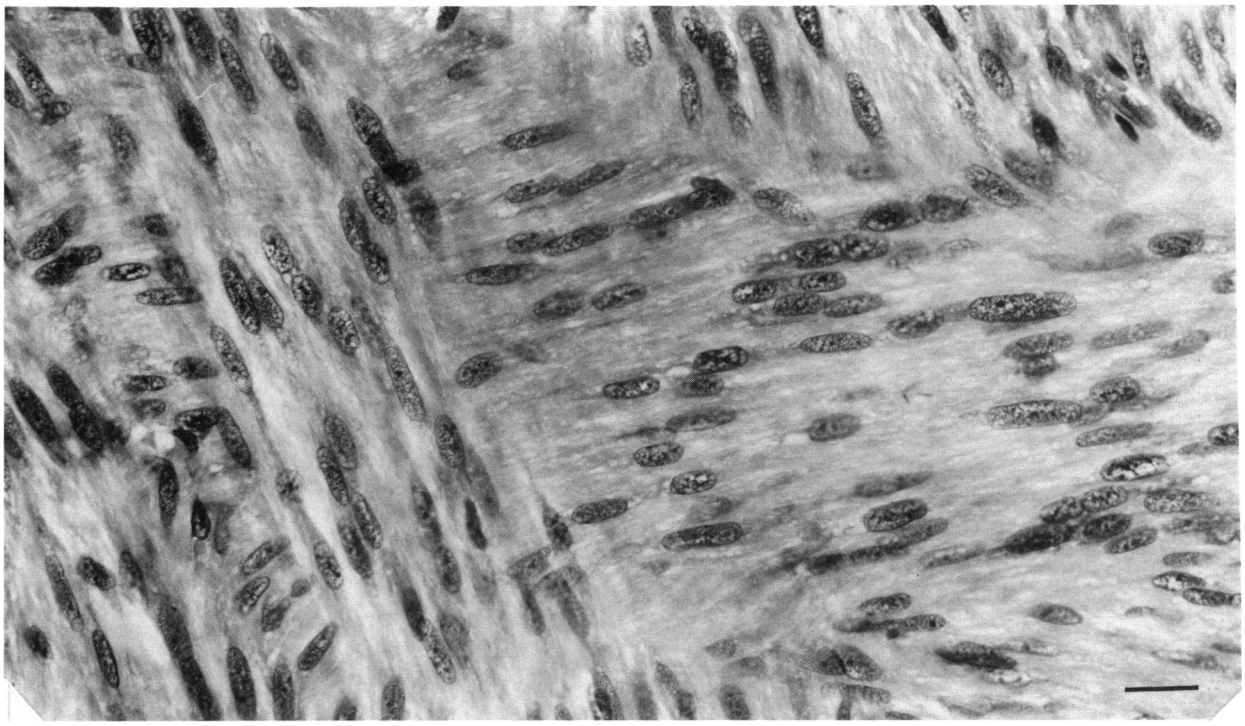

PLATE 7. Mesovarian leiomyoma showing elongated cells with cigar-shaped nuclei. H & E. Bar = 20 μm.

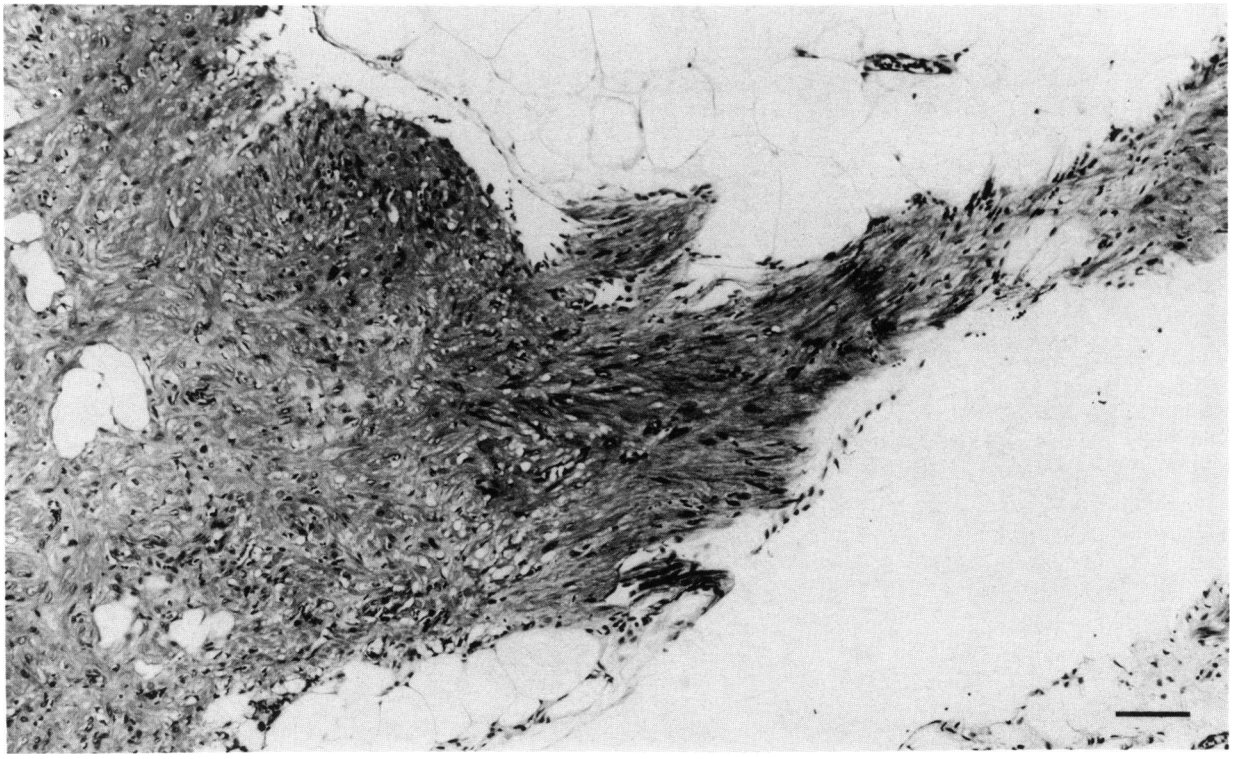

PLATE 8. An area of mesovarian smooth muscle hyperplasia. H & E. Bar = 40 μm.